

Complications After Filler Injection in Breasts

Sie Thu Myint^{1,2*}, Zin May Win^{1,2}, Aung Myat Thu³, Ohnmar Thaug^{1,2}, Soe Lin^{1,2}, Wutyee Thiha Aung^{1,2}, Khin Hsu Hlaing^{1,2}, Naing Min Soe^{1,2}, Aung Myat^{1,2}, Htun Thuya^{1,2} and Thein Lwin

¹Department of surgery, University of Medicine (1), Yangon, Myanmar

²Surgical Ward 2, Yangon General Hospital, Myanmar

³Grand Hanthar International Hospital, Myanmar

*Corresponding Author: Sie Thu Myint, Department of surgery, University of Medicine (1), Yangon, Myanmar.

Received: March 11, 2024

Published: April 23, 2024

© All rights are reserved by Sie Thu Myint, et al.

Abstract

Breast augmentation is one of the most common aesthetic surgeries in the world. There are 2 types of breast augmentation; breast implants, and fillers, such as autologous fat and biomaterials.

Filler injection is a common procedure in Yangon. Filler injection can be associated with granulomas and malignancy.

Breast augmentation has a long history. In the past, paraffin or oil was injected into the breast. Recently liquid silicone or polyacrylamide hydrogel was used as fillers.

Keywords: Breast Augmentation; Infection; Fat

Introduction

Aquafilling/Los Deline injections correct mild unfavorable results after breast augmentation with silicone implants. Single large-volume injections for breast augmentation are employed all over the world, including Europe, Japan, and Korea [1].

Complications after injection of various materials for breast augmentation include inflammation, infection, fat necrosis, mastalgia, gel migration, and nodular lesions.

Case Study

In this case series, some of the complications are described.

The first case is about a 25-year-old lady who underwent injection of fillers for augmentation of both breasts. Following injection, anaphylactic shock developed and she was admitted to intensive care unit. A few days later, the injection sites developed fat necrosis which required wide excision under general anaesthesia (Figure 1). After wide excision, daily dressing was carried out. The patient recovered and was discharged from hospital. The wound healed completely with secondary union.

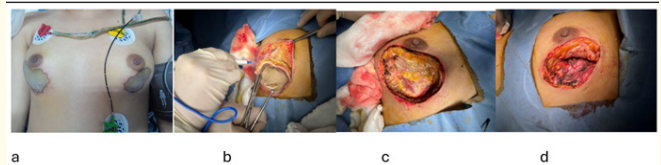


Figure 1

The second case, a 20-year-old lady developed infection and required drainage under general anaesthesia (Figure 2). The post-operative period was uneventful. Daily dressing was carried out and the wound healed completely.

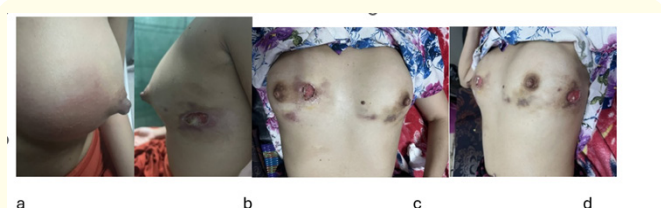


Figure 2