



## Clinical Diagnosis and Therapeutic Management of Schistosomosis (*Schistosoma spindale*) Infestation in Cattle: A Case Study

Deepak Chandran<sup>1\*</sup>, Lejaniya AS<sup>2</sup>, Ajin S Kumar<sup>3</sup>, Athira Rajan<sup>3</sup> and Georgen G Edana<sup>4</sup>

<sup>1</sup>Assistant Professor, Department of Veterinary Sciences and Animal Husbandry, School of Agricultural Sciences, Amrita Vishwa Vidyapeetham University, Tamil Nadu, India

<sup>2</sup>PhD Scholar, UCSI University, Department of Food Science and Nutrition, Faculty of Applied Sciences, Taman Connaught, Malaysia

<sup>3</sup>Veterinary Doctor, Kerala, India

<sup>4</sup>BVSc and AH Scholar, Kerala Veterinary and Animal Sciences University, India

**\*Corresponding Author:** Deepak Chandran, Assistant Professor, Department of Veterinary Sciences and Animal Husbandry, School of Agricultural Sciences, Amrita Vishwa Vidyapeetham University, Tamil Nadu, India.

**Received:** September 14, 2021

**Published:** July 13, 2022

© All rights are reserved by **Deepak Chandran., et al.**

### Abstract

Schistosomosis is a snail borne trematode infection of domestic and wild animals in different parts of Asian and African subcontinent. A study was conducted at Ashraya Veterinary Clinic, Wayanad district, Kerala, India, during the period of June-July 2021 with schistosomosis (*S. spindale* infection) in cattle, in which three cows were selected for the study. All the three cases were reported with present history of diarrhoea, mixed with blood and mucous, and had a common history of grazing in marshy fields. Diagnosis of disease condition as schistosomosis was done by microscopical examination of faecal sample after digestion with 10% potassium hydroxide solution. The treatment protocol followed was Anthiomaline @ 2.5 to 5 mg/kg BW I/M and then repeated on alternate days or weekly once for two more times.

**Keywords:** Schistosomosis; Blood; Mucous; Anthiomaline

### Introduction

Livestock plays a major role in economic status of India's rural population. It contributes nine percent gross domestic product (GDP) and employs eight percent of the labour force. Schistosomosis is a snail borne trematode infection of domestic and wild animals in different parts of Asian and African subcontinent. It is regarded as fifth major helminthosis of domestic animals in the subcontinent [1,2]. It was Montgomery in 1906 who first described schistosomosis in the portal vein of domesticated animals in India and described three new schistosome viz., *S. spindale*, *S.*

*indicum* and *Ornithobilharazia bomfordi* [3]. Visceral schistosomosis is widespread in India and other developing countries. About 165 million cattle are infected worldwide and 530 million head of cattle live in areas endemic to schistosomosis [4]. Transmission of infection takes place via water and infection may occur after brief contact with water in endemic areas. Schistosomes are successful parasite apparently, as the result of prolonged co-evolution with their host. An abattoir study based on mesenteric worm count estimated a very high prevalence of 57.3% of *S. spindale* infection in Wayanad [5,6]. Pilot study conducted at Thrissur district also re-

vealed 42.4% prevalence of *S. spindale* among cattle and buffalo. Detection of subclinical schistosomosis in live animal is difficult since affected animal do not show any signs of diseases and animal act as carrier. It is important to detect the disease in live animal so that they can be treated in order to minimize morbidity and economic loss. *S. spindale* infection is under diagnosed as the eggs in routine faecal sample are usually masked with high mucous content and often missed. Diagnosis of the disease is based on clinical signs and examination of clinical materials. Schistosomes are elongate, unisexual and dimorphic trematodes which inhabit the blood vessels of their hosts. The female is longer than the male and the female is usually carried, especially during copulation, by the latter in a ventral, gutter-like groove, the gynaecophoric canal formed by the incurved lateral edges of the body. The eggs are thin shelled and have lateral or terminal spine. The occurrence of cattle schistosomes within their range is discontinuous, depending on the presence of intermediate snail hosts, their level of infection, and the frequency of water contact. Ruminants are usually infected with cercaria (infective stage) by penetration of the skin, although infection may be acquired orally while animals are drinking [7,8].

**Materials and Methods**

A study was conducted at Ashraya Veterinary Clinic, Wayanad district, Kerala, India, during the period of June-July 2021 with schistosomosis (*S. spindale* infection) in cattle, in which three cows were selected for the study. All the three cases were reported with present history of diarrhoea, mixed with blood and mucous, and had a common history of grazing in marshy fields. Diagnosis of disease condition as schistosomosis was done by microscopical examination of faecal sample after digestion with 10% potassium hydroxide solution.

**Clinical case details**

- **Case 1:** A five - years old crossbred cow (Figure 1) was presented with a history of passing dung mixed with blood and mucous (Figure 2) for two days, had a history of grazing in field. Animal was dewormed one week back with fenbendazole bolus. Upon clinical examination, temperature of 99.9°F, pale mucus membrane and one rumen motility in two minutes were detected.
- **Case 2:** A four years old crossbred cattle (Figure 3) was presented with a history of passing blood along with dung in the last one day, reduced milk yield. Animal was dewormed two months back with morantel citrate bolus and had a history of grazing in field. Upon clinical examination, temperature of

101.1°F, pale mucus membrane and two rumen motility in two minutes were detected.

- **Case 3:** A four years old crossbred cattle was presented with a history of passing dung mixed with blood in the past three days. Animal is anorectic and has reduced milk yield; dewormed two weeks back with morantel citrate bolus. Upon clinical examination, high temperature of 101.8°F, pale mucus membrane (Figure 4) and one rumen motility in two minutes were detected.



**Figure 1**



**Figure 2**



**Figure 3**

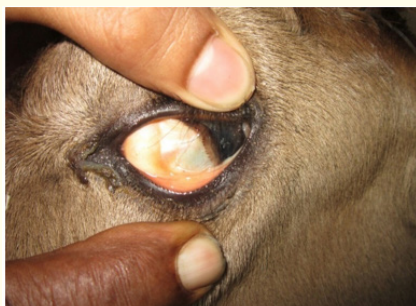

Figure 4

### Results and Discussion

Faecal sample examination of dung after digestion with 10% KOH solution revealed spindle shaped ova of *Schistosoma spindale* (Figure 5 and Figure 6). After confirmatory diagnosis, each animal was administered 15 ml Anthiomaline via intramuscular route at two different sites. Treatment with Anthiomaline was repeated after two weeks. All the animals recovered from clinical signs after first administration of Anthiomaline itself.

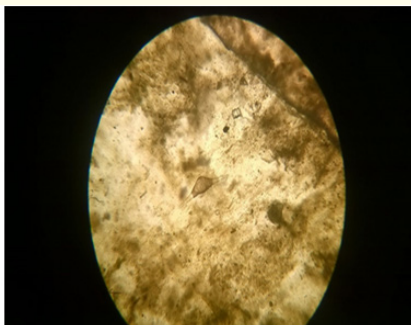


Figure 5

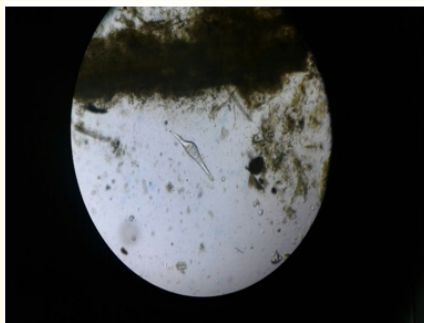


Figure 6

*Schistosoma spindale* flukes reside in the mesenteric veins and *Indoplanorbis exustus* (snail) act as intermediate host (Sumanth *et al.*, 2004). The eggs of *S. spindale* are spindle shaped with a terminal spine and they are expelled out through faeces of infected animals. The eggs immediately hatch when these come in contact with water. After hatching the miracidium comes out and enter into snail. In the snail host three other stages occur like sporocyst, daughter sporocyst and cercaria. No redia stages occur in snail. The cercaria is actively motile and can move from one place to another. The final host gets infection through skin penetration performed by cercaria. The cercaria penetrates through skin and gets transformed into schistosomula. The schistosomula are transported to the specific location through blood circulation to lungs, liver, portal vessels etc. Clinical signs of the disease include profuse diarrhoea mixed with blood and mucous, apart from anemia, dullness, depression and emaciation [3,9]. Most important confirmatory clinical diagnosis is through examination of faecal sample where in spindle shaped egg of *S.spindale* is detected. Histological examination of biopsy material of mucosa, liver or other affected organ is also carried out for detection of eggs. Another method of diagnosis is via miracidium inhibition test [7]. The proved treatment protocols are Tartar emetic @ 1mg/kg I/V two times a week for six weeks, Praziquantal @ 60 mg/kg orally, and Anthiomaline @ 2.5 to 5 mg/kg BW I/M and then repeated on alternate days or weekly once for two more times. Proper treatment of affected animals is very important to prevent the spread of disease. Control measures are based on interrupting the life cycle by removing adult parasites by chemotherapy, elimination of snail-intermediate host by molluscicides and preventing access of definitive hosts to natural water sources contaminated with cercaria. Animals should not be allowed to graze on the low land area where water is stagnant. Control of snails by application of molluscicides ensure the contraction of animals with schistosomosis [4,8].

### Conclusion

Three cases of schistosomosis (*S. spindale*) infestation were reported at Ashraya Veterinary Clinic, Wayanad during June - July 2021. The animals recovered from clinical signs after two injections of Anthiomaline I/M taken at two weeks interval. Schistosomosis is often a subclinical disease which cause high economic losses due to morbidity and mortality, impaired growth, decreased productivity and an increase in sensitivity to other parasitic and bacterial infection. Cercaria, the infective stage for definitive host have a short life span and survive for only few hours after shedding from the snail. The transmission requires prolonged contact between animal and cercaria contaminated water. Such conditions are fulfilled by animal grazing in marshy pastures and drinking contaminated water.

Therefore, schistosomosis is encountered in areas with perennial water sources such as ponds, lakes, dams and marshy grazing grounds. Control measures are based on interrupting the life cycle by removing adult parasites by chemotherapy, elimination of snail-intermediate host by molluscicides and preventing access of definitive hosts to natural water sources contaminated with cercaria.

### Bibliography

1. Mc Cawley, *et al.* "Economic evaluation of the production impact of bovine schistosomiasis and vaccination in Sudan". *Preventive Veterinary Medicine* 2 (1984): 735-754.
2. Sumanth S., *et al.* "A study of nasal and Visceral schistosomosis in cattle slaughtered at an abattoir in Bangalore". *Revue Scientifique et Technique* 23 (2004): 937-942.
3. Rajamohan K. "Schistosomosis in cattle and buffalo in Kerala state". MVSc Thesis, Kerala Agricultural University, Thrissur (1972): 93.
4. Agrawal MC., *et al.* "Schistosoma spindale and bovine schistosomosis". *Journal of Veterinary Parasitology* 14 (2000): 95-107.
5. Ravindran R., *et al.* "Visceral schistosomiasis among domestic ruminants slaughtered in Wayanad, South India". *South East Asian Journal of Tropical Medicine and Public Health* 38 (2007): 1008-1010.
6. Bindu L., *et al.* "Abattoir survey of Schistosoma spindale infection in Thrissur". *Journal of Veterinary and Animal Science* 42 (2011): 53-54.
7. Osman AA., *et al.* "A note on the diagnosis of schistosomiasis in slaughtered sheep". *Sudan Journal of Veterinary Science and Animal Husbandry* 24 (1984): 127-132.
8. Deepa C. "A study on the prevalence of schistosomiasis in bovines". *Intas Polivet* 8 (2007):143-144.
9. Dargie JD. "The pathogenesis of Schistosoma bovis infection in Sudanese cattle". *Transactions of the Royal Society of Tropical Medicine and Hygiene* 74 (1980): 560-562.
10. Montgomery RE. "Observations on Bilharziasis among animals in India". *Journal of Tropical Veterinary Science* 1 (1906): 15-46.