



## Surgical Management of Closed Pyometra in a Bengal Cat: A Case Report

Parvathy Gopakumar Nair<sup>1\*</sup>, Sreenu Sreekumar<sup>1</sup>, Theneyan Mohamed<sup>2</sup>, Fredrick Olianga<sup>1</sup>, Francis Pilapil<sup>1</sup>

<sup>1</sup> Veterinary Surgeon, Al Wasl Veterinary Clinic (Falcon Centre), Dubai, United Arab Emirates

<sup>2</sup> Senior Veterinary Surgeon, Al Wasl Veterinary Clinic (Falcon Centre), Dubai, United Arab Emirates

**\*Corresponding Author:** Parvathy Gopakumar Nair, MVSc; Veterinary Surgeon, Al Wasl Veterinary clinic (Falcon Centre), Jumeirah 1, Dubai, United Arab Emirates, Tel: 00971588567065; Fax: 043447555; Email: pgnair92@gmail.com

**DOI:** 10.31080/ASVS.2022.04.0409

**Received:** April 11, 2022

**Published:** May 26, 2022

© All rights are reserved by **Parvathy Gopakumar Nair., et al.**

### Abstract

A four year old female Bengal cat was presented to Al Wasl Veterinary Clinic (Falcon centre) Dubai with distended abdomen and complaint of inappetence. The cat had mating history before 35 days. On clinical examination cat had the rectal temperature of 100.9 F and pale mucous membrane. The vulva was dry and clean. On ultrasonography examination of abdomen, multiple anechoic areas found in the uterine lumen. Complete blood count revealed leucocytosis with neutrophilia and eosinophilia. Based on the above mentioned findings, the condition was diagnosed as feline closed pyometra or Cystic endometrial hyperplasia. Cat was stabilized with antibiotics and supportive intravenous medication. Midventral laparotomy was performed under general anaesthesia. Ovario-hysterectomy was performed in a routine manner. Blood parameters two days post surgery was within the normal limits. The cat had an uneventful recovery.

**Keywords:** Feline; Ultrasonography; Anechoic; Closed pyometra; Ovario-hysterectomy; Cystic endometrial hyperplasia

### Introduction

Pyometra in cats is a disease characterized by an acute or chronic suppurative bacterial infection of the uterus post estrum with accumulation of inflammatory exudate within the uterine lumen [1]. In cats, pyometra is not commonly encountered, depends on less progesterone dominance due to seasonality and induced ovulation. Queen being an induced ovulator, ovulation occurs 30-50 hours post mating and starts to produce progesterone 24-48 hours post ovulation [2]. Progesterone causes hyperplasia, stimulates secretory activity of endometrial glands, suppression of myometrial contractions and cervical closure leading to ascending bacterial infection from vagina [1,3].

The most common clinical observation is vaginal mucopurulent discharge, seen in about 75% of the cases [4]. This symptom is ab-

sent in cases with closed cervix pyometra. Uterus can be palpated hard with or without abdominal distension [5]. Ultrasonography is the best and effective tool for the diagnosis of pyometra [3,6].

Ovario-hysterectomy is the safest and most effective curative option, since there is complete removal of source of infection and bacterial products, preventing recurrence.

### Material and Methods

#### History and clinical examination

A four year old female Bengal cat weighing 4.3 kg was presented to Al Wasl Veterinary Clinic, Falcon centre, Dubai with distended abdomen (Figure 1) and complaint of inappetence for past two days. The cat had a history of mating before 35 days. On clinical examination cat had the rectal temperature of 100.9 F and pale mu-

cous membrane. Other physiological parameters including respiration and heart rate were within the normal limits. The vulva was dry and clean, no discharge was noted. On abdominal palpation, uterus felt harder and enlarged than normal. Lateral radiograph revealed multiple sacculated opaque fluid filled structures from caudal to mid abdomen many places superimposed with urinary bladder (Figure 2). Ultrasonographic examination of abdomen showed multiple anechoic areas presented within the uterine lumen (Figure 3). Complete blood count revealed leucocytosis with neutrophilia and eosinophilia (Table 1). Serum biochemistry showed high globulin levels (Table 2). Based on the above mentioned clinical findings, the condition was diagnosed as Feline closed pyometra.

**Surgical management**

**Stabilization and anesthesia**

The cat was immediately stabilized intravenously with antibiotic (Inj. Amoxicillin Clavulanic acid @12.5mg/kg bodyweight), analgesic (Inj. Meloxicam 0.2 mg/kg bodyweight subcutaneously), fluid therapy (Ringer’s lactate @10ml/kg bodyweight, Duphalyte @5ml/kg bodyweight intravenously) and antacid (Omeprazole 0.75 mg/kg bodyweight intravenously). She was premedicated with ketamine (5mg/kg bodyweight) and medetomidine hydrochloride (0.025mg/kg bodyweight) intramuscularly. The cat was then intubated with size 2.5 endotracheal tube and anesthesia was maintained in 1-2% Isoflurane at the oxygen flow rate of 1 litre/minute.

**Surgical procedure**

The queen was positioned on dorsal recumbency. Surgical site was shaved and scrubbed with chlorhexidine and povidone iodine (Figure 4). Monitoring of temperature, partial pressure of oxygen, respiration and heart rate was done. A linear mid ventral incision was made and enlarged sacculated uterine horns were carefully exteriorized (Figure 5). The uterine and ovarian blood vessels were properly ligated with 2-0 polyglycolic acid. Ovaries, uterine horns and uterus were completely removed with all precautions to prevent the spillage of uterine contents (Figure 6). The abdominal wall was closed followed by subcutaneous sutures with size 2-0 polyglycolic acid. Skin was apposed with intradermal suture pattern with size 2-0 polyglycolic acid.

**Post-operative care**

Post- surgery, cat was admitted and maintained on inj. Amoxicillin Clavulanic acid @12.5mg/kg bodyweight twice daily for next seven days along with oral meloxicam suspension 0.1 mg/kg body-


weight for next 3 days. Blood sampling two days post-surgery was within normal limit (Table 1, 2). Cat had uneventful recovery and was discharged on seventh day post-operative.

Parameters	Queen (Pre-Surgery)	Normal limits	Queen (Post- surgery)
WBC (10 <sup>9</sup> /l)	98.34	3.5-20	19.82
Lymphocytes(10 <sup>9</sup> /l)	7.21	0.9-9.1	2.22
Monocytes (10 <sup>9</sup> /l)	0.68	0.09-1.2	0.76
Neutrophils (10 <sup>9</sup> /l)	89.25	1.6-13.4	14.2
Eosinophils (10 <sup>9</sup> /l)	1.12	0.02-0.5	0.14
RBC (10 <sup>12</sup> /l)	8.30	7.7-12.8	8.51
Haemoglobin (g/dl)	12.9	10-16.9	11.4
Platelets (10 <sup>9</sup> /l)	388	125-618	280

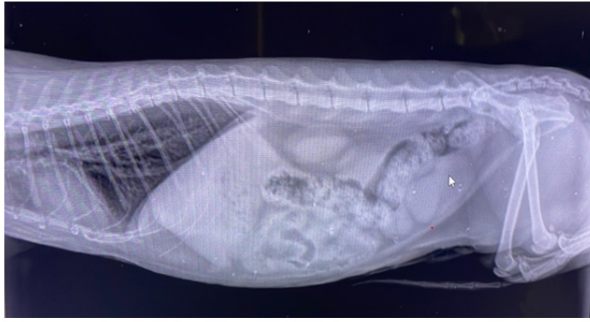
**Table 1:** Haematological values pre-surgery and post-surgery.

Parameters	Queen (Pre- Surgery)	Normal limits	Queen (Post-Surgery)
BUN (mg/dL)	21	10-30	25
Creatinine (mg/dL)	1.6	0.3-2.1	1.3
Albumin (g/dL)	1.9	2.2-4.4	2.3
Globulin (g/dL)	5.4	1.5-5.0	4.2
ALP (U/L)	19	10-90	10
Total Protein (g/dL)	7.3	5.4-8.2	6.5

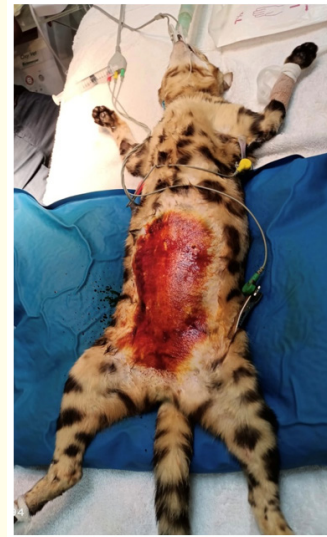**Table 2:** Serum biochemistry pre-surgery and post-surgery.



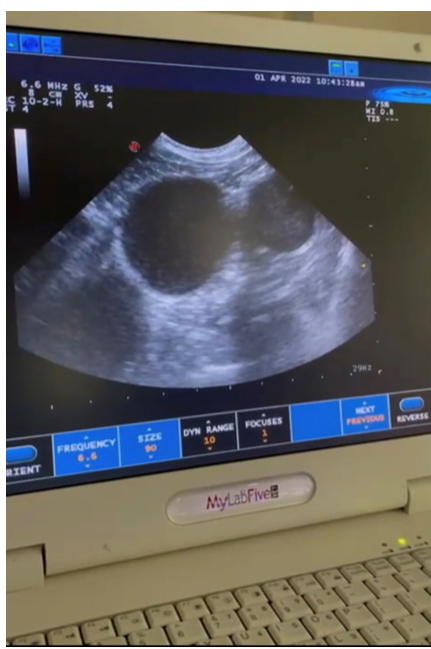**Figure 1:** Queen presented with distended abdomen.



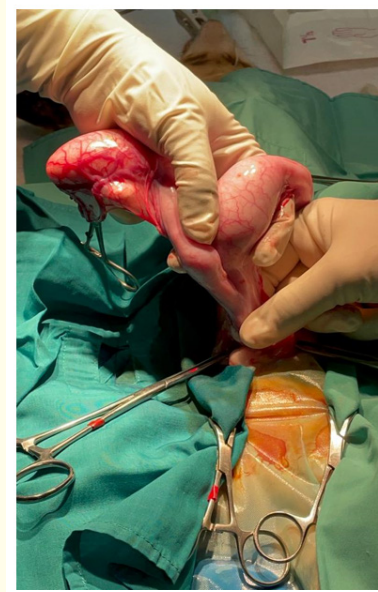**Figure 2:** Multiple sacculated radio-opaque fluid filled structures.



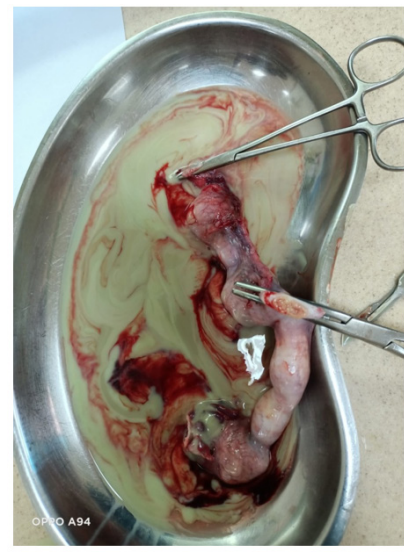**Figure 4:** Queen on dorsal recumbent position.



**Figure 3:** Multiple anechoic fluid filled sacs.



**Figure 5:** Uterus after exteriorization.



**Figure 6:** Removed Uterus with Pus.

## Result and Discussion

Pyometra is an inflammatory condition of uterus characterized by cystic endometrial hyperplasia. Pyometra is a uncommon condition in queens because of low progesterone dominance due to seasonality and induced ovulation [1,2]. Queens older than three years and older than five years with no relationship to the number of whelping [5], these findings were reported in the present report. Prevalence of pyometra in Bengal cat was found to be comparatively higher [4]. In queens with closed pyometra, discharge is not appreciated, they will have highly distended abdomen [5]. Endotoxaemia and bacteraemia are seen in such cases due to absorption of bacterial toxins [3].

Most of cats with pyometra show high white cell counts frequently characterized by leukocytosis with neutrophilia and left deviation [5], similar to be current report. It could be associated with the retention of purulent material in the uterus causing toxin production. Serum biochemistry does not show vast abnormalities. In cases with sepsis, hypoglycaemia is seen as a result of increase in consumption of glucose and decrease in gluconeogenesis. Along with this manifestation hypokalaemia and azotaemia are generally seen due to hypovolaemia and circulatory collapse. In present con-

dition hyperglobulinaemia was observed due to dehydration and inflammatory process. Hyperglobulinaemia similar to our case can be present in 30-60% of the cases [1,5]. Ultrasonography is the most efficient diagnostic tool for pyometra [6] as it helps to detect the anechoic or hypoechoic intrauterine fluid leading to prompt diagnosis. Early and accurate diagnosis offers the best chance of cure.

If the cat is young or the owners have the desire to breed from her or if she is old and in poor condition for surgical risk, medical treatment could be attempted otherwise surgical management is the treatment of choice [8]. Surgical management is the most effective treatment option in closed pyometra because through Ovario-hysterectomy, the source of infection and bacterial products are removed completely preventing its recurrence [5,7]. In this case, dorsal recumbency, with ventral midline approach was preferred which gave a better visualization of the anatomy, also preference of this site reduced postoperative pain and infection.

In the present study early diagnosis of the condition, timely surgical intervention and antibiotic therapy saved the life of the animal.

## Conclusion

Feline closed pyometra or Cystic Endometrial hyperplasia is the condition not seen commonly as canines. In the present study Bengal cat diagnosed with closed pyometra and its successful surgical management, had rapid and uneventful recovery.

## Conflict of Interest

The authors declare that they have no conflict of interest.

## Bibliography

1. Hagman Ragnvi. "Pyometra in small animals." *Veterinary Clinics: Small Animal Practice* 48.4 (2018): 639-661.
2. Holst Bodil Ström., *et al.* "Characterization of the bacterial population of the genital tract of adult cats." *American Journal of Veterinary Research* 64.8 (2003): 963-968.
3. Hollinshead Fiona and Natali Krekeler. "Pyometra in the queen: to spay or not to spay?" *Journal of Feline Medicine and Surgery* 18.1 (2016): 21-33.
4. Hagman Ragnvi., *et al.* "Incidence of pyometra in Swedish insured cats." *Theriogenology* 82.1 (2014): 114-120.



5. Agudelo CF. "Cystic endometrial hyperplasia-pyometra complex in cats. A review". *Veterinary Quarterly* 27.4 (2005): 173-182.
6. Bigliardi E., *et al.* "Ultrasonography and cystic hyperplasia-pyometra complex in the bitch". *Reproduction in Domestic Animals* 39.3 (2004): 136-140.
7. Boursier., *et al.* "Effectiveness of a bipolar vessel sealant device for ovariohysterectomy in cats with pyometra". *Journal of Feline Medicine and Surgery* 20.12 (2018): 1119-1123.
8. Nak., *et al.* "Follow-up examinations after medical treatment of pyometra in cats with the progesterone-antagonist aglepristone". *Journal of Feline Medicine and Surgery* 11.6 (2009): 499-502.