



Study on Major Gross Lesions in Lung of Small Ruminants Slaughtered at Elfora Export Abattoir Bishoftu, Central Ethiopia

Ibrahim Denebo¹ and Arega Tafere^{2*}

¹Veterinary Medicine, Recently Graduated from Wolaita Sodo University, Ethiopia

²Veterinary Pathology, Wolaita Sodo University, Ethiopia

*Corresponding Author: Arega Tafere, Veterinary Pathology, Wolaita Sodo University, Ethiopia.

Received: December 06, 2021

Published: March 09, 2022

© All rights are reserved by Ibrahim Denebo and Arega Tafere.

Abstract

Lungs exposed to larval stages of cestode belonging to the genus *Echinococcus* caused Hydatidosis which is an important zoonosis and may lead to development of emphysema and pneumonia as a result of secondary disease complication. A cross-sectional study was conducted from May, 2021 to August, 2021 to determine the major gross lesions and associated risk factors in small ruminants that brought from Afar, Arsi, Borena, Harar and Somali areas at ELFORA export abattoir. During the study period, gross pathological examination was conducted on 400 (224 goats and 176 sheep) randomly selected small ruminants. The total prevalence of gross pathological lesions in lung of Sheep and Goats slaughtered at ELFORA export abattoir in the current study was 250 (62.5%). Out of 224 goats 143 (63.84%) and 176 sheep 107 (60.79%) lung gross lesions were detected. Based on ages of the small ruminants, in young 58(69.87%) and adult 192 (60.56%) were affected with gross pathological lesions of lungs. Based on body condition score, good 59 (52.67%) and medium 191 (66.31%) were affected with gross lesions of lung. Animals were brought from Borena, Arsi, Somali, Harar and Afar within percentage of gross lesions that detected in the lungs 81 (60.9%), 36 (67.92%), 37 (62.71%), 37 (74%) and 59 (56.19%) respectively. Significant variation ($p < 0.05$) was no observed in different age groups, species, body condition scores and origin of the animals. The current finding in goats, hydatid cyst (8.93%), pneumonia (20.98%), emphysema (16.07%), calcification (14.73%), congestion (10.27%), consolidation (8.93%), abscess (3.57%) and others (6.25%) while in sheep, hydatid cyst (11.93%), pneumonia (23%), emphysema (13.63%), calcification (13.63%), congestion (6.25%), consolidation (5.68%), abscess (5.11%) and others (2.27%) prevalences were determined. In conclusion, this study showed that hydatidosis and major gross pathological lesions of lungs in small ruminants causes significant problems generally on health of small ruminants and particularly on organ of lungs. Further investigation to determine prevalence of lung abnormalities in small ruminants in different areas of the country and zoonotic importance of hydatidosis is recommended.

Keywords: Goat; Hydatidosis; Lung; Sheep; Small Ruminants

Introduction

Ethiopia is the leader small ruminant's population in Africa continent which is kept by farmers mostly found in low rank economy in rural areas. It is common way of life in most part of the country rather than urbanization. The estimated small ruminants (sheep and goats) population in Ethiopia is 47.8 million.

The animal productivity is still inadequate even though huge livestock resources are available in Ethiopia. This may be associated with presence of infectious and non-infectious disease and lack of good management strategy according to CSA [11]. Hydatidosis

is one of common disease that hinders productivity in sheep and goat and one of common problems of lung abnormalities in animals among major tropical parasitic diseases [27]. It is also a zoonotic diseases caused by *Echinococcus granulosus* [12]. Long term development of hydatid cysts in the intermediate host is characteristics of hydatidosis infection. The prevalence of hydatidosis in a particular area can be affected with different factors such as environment, social culture, and the dynamics of transmission between definitive and intermediate host including human. Large number of mammalian species including domestic ungulates and man are intermediate while dogs are a definitive host of the diseases [3,28].

In Ethiopia, where home slaughtering of cattle, sheep, goats and camels is still practiced and uncooked offal and carcass wastes are normally fed to dogs and cats, cystic echinococcosis has become an endemic disease and poses public health problems. Many researches are carried out in Ethiopia to determine echinococcosis prevalence [17]. The occurrence of emphysema and pneumonia may be associated with exposure to bacterial or viral infections and stress of slaughter animals at lairage during acclimatization of animals in addition to hydatidosis [10,11]. Lung enlargement, hyperaemia, and sometimes oedema are characteristics of pneumonia which describes inflammation of lung and commonly caused by environmental agents. Atelectasis is also another lesion of the lung as a result of collapse of the alveoli due to failure of the alveoli to inflate or because of compression of the alveoli while emphysema occurs due to destruction of connective tissue of the lung, including the supporting and elastic tissue of pulmonary parenchyma. It also occurs in an abnormal permanent accumulation of air in the lungs associated with some disease conditions and is caused by an obstruction to the outflow of air or by extensive gasping respiration during slaughter procedures. Lung emphysema can be identified macroscopically by inspecting enlarged greyish-yellow, pale, pear like shiny and palpating puffy and crepitant feel lung [19, 22]. The prevalence and gross pathological lesions of lung in animals has been reported from different parts of the country by different researchers. Even though, different researchers in the country studied on gross lesions of lung in cattle, there is limited work in gross abnormalities of lung in sheep and goat specifically, there was no work done at ELFORA export abattoir, Bishoftu. Thus, the aim of this study will be undertaken:

- To assess major gross lesion in lung of sheep and goat slaughtered at ELFORA export abattoir, Bishoftu.
- To determine associated risk factors in lung abnormalities of sheep and goat.

Material and Methods

Study area

The present study was conducted in Bishoftu town which is located at 47km South East from Addis Ababa. The research was carried out between May, 2021 and August, 2021 at ELFORA export abattoir in Bishoftu town, located at 9°North and 40°East with an altitude of 1880 meter above sea level [20]. Veterinary laboratory facilities are organized at the export abattoir to conduct microbiological assessments. These enable ELFORA as part of latest devel-

opment in safety control assurances and product quality control. The Ministry of Agriculture and Rural Development issued international sanitary certificates regarding meat and meat product shipments.

Study population

A total number of 400 animals (176 sheep and 224 goats) was presented for slaughter from which goats was higher compared to sheep due to less requirement of sheep than goats in the abattoir. The study was performed in lung of both sheep and goats. Animals were all males and originated from different parts of lowland of the country. These areas were like, Somale, Borena, Afar, Arsi and Harar. The animals were slaughtered in ELFORA abattoir, Bishoftu.

Study design and sampling method

Simple random sampling method was performed to the present study to take the representative sample of sheep and goats brought from Afar, Arsi, Borena, Harar and Somali, from May, 2021 to August, 2021. The study design employed was a cross sectional type with the objective of determining the hydatidosis prevalence and major gross lesion identification in lung sheep and goat by post-mortem examination of lung.

Sample size determination

The sample size for study animals was determined by the formula given by (Thrusfield, 2005). The sample size was calculated by using from the previous report 37% [5] prevalence. In this study 37% prevalence with 5% desired level of precision and 95% of confidence interval are used to calculate the sample size using the following formula.

The proposed sample size is;

$$N = \frac{T^2 \times P_{exp} (1 - P_{exp})}{d^2}$$

Where,

N = Sample size to be determined

T = Value at a given confidence level and T = 1.96

P_{exp} = Expected prevalence of lung major gross lesions in the study area

D = Desired absolute precision at 95% confidence interval = 5%.

Therefore, Accordingly, the required sample size for this study was 358; but in order to increase precision, it was added by 42 thus 400 (224 goats and 176 sheep) were used for study.

Data collection procedure

Animals will be grouped into species (sheep and goat), age was determined by observing their teeth according to the methods described by (Solomon and Kassahun, 2009). Animals was categorized as; Young (animals in the age below or equal to 1.5 year) and Adult (greater than 1.5 year). The area where animals were brought also recorded.

Ante mortem

The study animals were given all the necessary identification with paint on their body and and variables such as age, origin and body condition score was recorded during ant-mortem examination. All body parts of animals were inspected at lairage before slaughtered for any pathological abnormalities and injuries. Normal and abnormal behavior of animals, posture, giant, respiration, color, and conformation were also inspected. During ante mortem inspection, the age of each animal was identified by visual observation of the teeth, for those which have not erupted permanent incisor teeth, were grouped as young, and while those with pair or more permanent incisor teeth erupted were grouped as adult [2].

Post mortem

Visualization, palpation and incisions were used during post-mortem examination of lung for the presence of any abnormality. Gross lesions were identified and judged based on the guidelines of meat inspection for developing countries. The major gross lesions identification in lung of small ruminants during post-mortem examination were hyadit cyst, empysema, pneumonia, calcification, congestion, consolidation, abscess and others lesions were observed [15].

Data analysis

The current data collected, were analyzed using Stata Version 13.0 (Stata corp. College Station, TX, USA). The prevalence of cysts in sheep and goat were described and summarized by Descriptive statistics. Chi-square (χ^2) test was used to determine the association between different risk factors. The $p = 0.05$ were considered as significance level.

Result

Of the total 400 carcasses (224 goats and 176 sheep) examined, 250 (62.5%) were infected with overall lungs gross pathological lesions. The overall lungs gross lesions were detected in 143 (63.84%) and 107 (60.79%) of the inspected goats and sheep respectively. The difference in the prevalence of the overall lungs gross lesions of two species, were no significant ($p > 0.05$). Out of the total 83 young and 317 adult small ruminants examined 58 (69.87%) young and 192 (60.56%) adults gross lesions of lung were observed. The occurrence of overall lungs gross lesions based on body condition of animals were detected in 59 (52.67%) good and 192 (66.31%) medium. The highest prevalence (74%) was identified in animals from Harar, whereas, the lowest prevalence (56.19%) was detected in animals from Afar (Table 1 and Figure 1).

Risk factors		No of inspected	No affected	Percent (%)	X ² (p-value)
Species	Caprine	224	143	63.84	0.389 (0.533)
	Ovine	176	107	60.79	
	Total	400	250	62.5	
Age	Young	83	58	69.87	2.433 (0.119)
	Adult	317	192	60.56	
	Total	400	250	62.5	
BCS	Good	112	59	52.67	6.402 (0.011)
	Medium	288	191	66.31	
	Total	400	250	62.5	
Origin	Borana	133	81	60.9	5.416 (0.247)
	Arsi	53	36	67.92	
	Somali	59	37	62.71	
	Harar	50	37	74	
	Afar	105	59	56.19	
	Total	400	250	62.5	

Table 1: The overall lungs gross pathological finding associated with different risk factors. BCS: body condition scores.

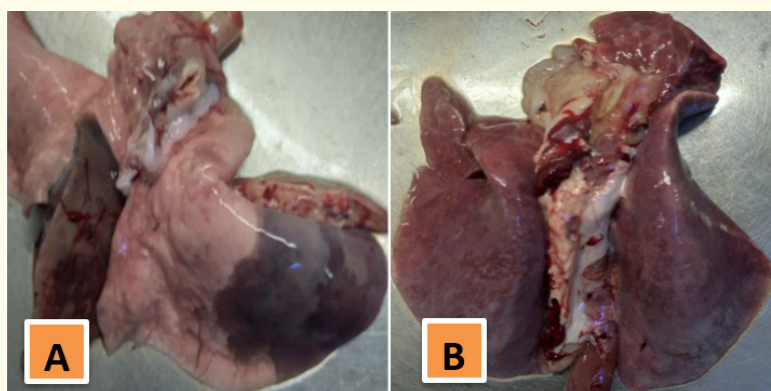


Figure 1: Lung hepatization and sever congestion in small ruminants: Red hepatization of lung (A) and generalized congested lung (B).

Out of total 400 animals (224 goats and 176 sheep) examined, 41 (10.25%) were infected with hydatid cysts. Cysts were detected in 20 (8.93%) and 21 (11.93%) of the infected goats and sheep respectively. The difference in prevalence of the cyst in two species was no significant ($p > 0.05$). Out of total 400 carcasses (224 goats and 176 sheep) examined, 88 (22%), 60 (15%), 57 (14.25%), 34 (8.5%), 30 (7.5%), 17 (4.25%) and 18 (4.5%) were infected with pneumonia, Emphysema, Calcification, Congestion, Consolidation, Abscess and Other lesions respectively. Out of 224 Goats, 47 (20.98%), 36 (16.07%), 33 (14.73%), 23 (10.27%), 20 (8.93%), 8 (3.57%) and 14 (6.25%) were infected with pneumonia, Emphysema, Calcification, Congestion, Consolidation, Abscess and Other lesions respectively while out of 176 sheep, 21 (11.93%), 41 (23.29%), 24 (13.63%), 24 (13.63%), 11 (6.25%), 10 (5.68%), 9 (5.11%) and 4 (2.27%) were infected with pneumonia, Emphysema, Calcification, Congestion, Consolidation, Abscess and Other lesions respectively (Table 2 and Figure 2).

Gross lesions	Frequencies and Prevalence (%)		
	Caprine (%)	Ovine (%)	Total (%)
Hydatidosis	20(8.93)	21(11.93)	41(10.25)
Pneumonia	47(20.98)	41(23.29)	88(22)
Emphysema	36(16.07)	24(13.63)	60(15)
Calcification	33(14.73)	24(13.63)	57(14.25)
Congestion	23(10.27)	11(6.25)	34(8.5)
Consolidation	20(8.93)	10(5.68)	30(7.5)
Abscess	8(3.57)	9(5.11)	17(4.25)
Others	14(6.25)	4(2.27)	18(4.5)

Table 2: Lung gross lesion frequencies and prevalence in sheep and goat.

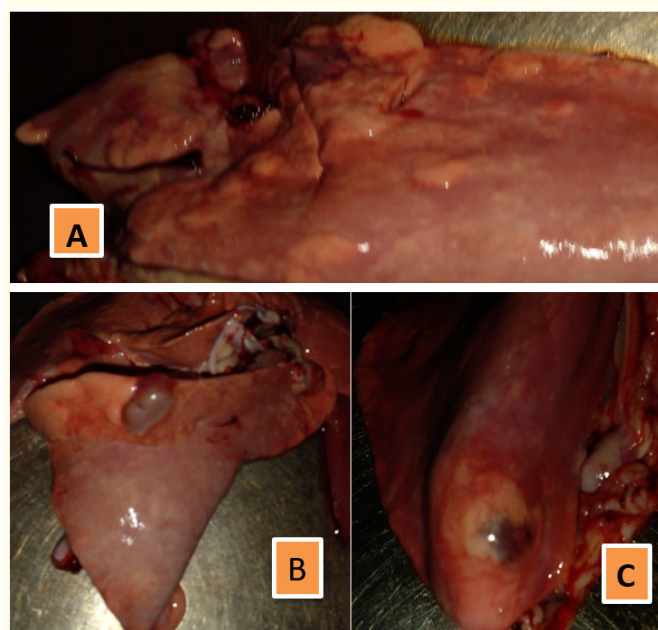


Figure 2: Gross lesion in lung of small ruminants. Affected lung showed abscess, congestion, cyst and granuloma (A), congestion and edema (B), fluid filled cyst, hydatid cyst (C).

Discussion

The total prevalence of the lungs gross pathological lesions in Sheep and Goats slaughtered at ELFORA export abattoir in the present study was 62.5%. This value was higher prevalence than 37% in ELFORA export abattoir [5]. This was due to various reasons like stress, inappropriate management and lack of awareness on animal health. The overall prevalence of lungs gross lesions recorded in this study in goats was 63.84 while in Sheep was 60.79%. Previously reported prevalence of 40.88% in goats while in sheep

was 35.93% in ELFORA export abattoir [5]. Both reports indicate that the prevalence of lung gross lesions in goats is slightly higher than sheep due to more infected browsers, lack of rest before slaughter and stress. Based on age the prevalence in adult (60.56%) was slightly lower than young (69.56%) due to young having lower immunity and needing good management than adult.

Gross lesions prevalence on lungs in medium (66.31%) was higher prevalence than in good (52.67%) based on body score due to variations in the temperature, environmental conditions, and the way of rising of these animals. The overall prevalence of hydatid cyst in lungs of sheep and goats slaughtered at ELFORA export abattoir in the present study was 10.25%. This value was slightly higher prevalence than 5.7% in Hashim export abattoir [1] and 2.2% in ELFORA export abattoir but, lower prevalence than 54.8% in ELFORA export abattoir [25]. These differences may be associated with different areas or sources of animals brought to the slaughter houses which contribute to the distribution of hydatidosis due to different disease host management and agro-ecological factors. The prevalence of hydatid cyst in the lungs of sheep (11.93%) was slightly higher prevalence than in the lungs of goats (8.93%). Sheep were more infected with hydatid cyst in the lung than goats due to the habit of feeding. Sheep were feeding and grazing while goats were feed browsers. The current prevalence of pneumonia in small ruminant was 22%. This value was in agreement with the prevalence of 18.29% and 23.31% in ELFORA export abattoir [8] and [5] respectively. The present prevalence rate of emphysema in small ruminant was 15%. The occurrence of emphysema in goats (16.07%) was higher prevalence than sheep (13.63%) due to many reasons like environmental condition and different exposure to stress. Emphysema in goat (16.07%) and in sheep (13.63%) was higher prevalence than 6.77% in goats and in sheep (7.03%) in ELFORA export abattoir [5]. The prevalence of calcification in lungs of sheep and goats slaughtered at ELFORA export abattoir in the present study was 14.25%. This value was disagreed with the prevalence of 3.13% in small ruminant previous study in ELFORA export abattoir [5]. In goats (14.73%) and in sheep (13.63%) was disagreed with the prevalence of 3.91% in goats and 2.34% in sheep. This was due to different reasons like environment condition, inappropriate transportation and lack of proper management. The prevalence of congestion in small ruminant was 8.5%. Current finding of consolidation prevalence of goats and sheep was 7.5% while abscess in sheep and goat was 4.25%. Other lesions were contained hepatization, atelectasis and hemorrhage. The present investigations of other lesions in goats (6.25%) were slightly higher than sheep (2.27%). Among gross lesions identification on lungs of small ruminant were more infected with pneumonia (22%), followed by emphysema (15%). Among

both species sheep was more infected with hydatid cyst than goat due to the habit of feeding; sheep graze while goats browse; therefore, sheep are more likely to pick echinococcal eggs agrees with the studies in Eastern Uganda [21]. Adults in both species were found to harbor more cysts than young. Some studies also similarly reported that significant variation occurred in the prevalence among age groups of animals [6]. Positive correlation in the prevalence of cystic echinococcosis as age of animal advances was explained [14]. This could mainly be due to differential and repeated exposure to infection as animals live for longer period.

In the present study, many abnormalities in lungs were found in both species. This might be related to the fact that lungs have the first great capillary sites encountered by the migrating *Echinococcus* oncosphere which adopt the portal vein route and primarily negotiate the hepatic and pulmonary filtering system sequentially before any other peripheral organs are involved [2,14,17]. The lungs were considered as having the first large capillary fields encountered by the blood-borne oncospheres. Also the presence of greater capillary beds in the lungs than in other organs and soft consistency of the lung might also help easy development of the cysts. When oncosphere escapes into the general systemic circulation, the development of cyst occurs occasionally in other tissues and organs [2].

Conclusion and Recommendations

Major lung gross abnormalities were investigated in the present study which poses hazards to public health, and may cause severe financial losses to the livestock in several regions of the world. The major gross lung lesions identification in small ruminants that slaughtered at ELFORA export abattoir were hydatidosis, pneumonia, emphysema, calcification, congestion, abscess and other lesions were detected by visualization, palpation and incision of lungs after postmortem examination carried out. Mostly animals were originated from Arsi, Afar, Borena, Harar and Somali areas of Ethiopia. Among both species sheep was more infected with hydatid cyst than goat but the overall breed prevalence major gross lung lesion was statistically non-significant. Both in sheep and goat lungs were more infected with pneumonia followed by emphysema. From the risk factors only body condition score were showed significant difference. Thus, according to the conclusion we are recommended:

- Public awareness creation on disease prevention and risk of zoonotic diseases and proper management and disposal of infected lungs
- Veterinary professionals, public health workers and policy makers should work together for a common goal.

- Expansion of abattoir facilities, appropriate meat inspection and disposal of infected organs should be strengthened.
- Regular treatment of dogs with anthelmintic and disease prevention and control strategies should be implemented.

Acknowledgements

First of all, thanks to God who support me successfully and who gave me the ability to do this thesis research. I would like to thank my advisor Dr. Arega Tafere (DVM, MVSc in verinary pathology) who helps me how to find sources from different and directly showed me the system of this work. And also thanks to Addis Ababa University College of Veterinary Medicine and Agriculture for accepting me to do this research in Bishoftu town, Ethiopia. I would also like to thank ELFORA export abattoir's workers for their permission and allowance to perform this thesis in their abattoir. Lastly, thanks to my family support me by financial and other who give advice for me.

Conflict of Interest

The authors declared that there is no conflict of interest regarding this described research article.

Bibliography

1. Abera A., *et al.* "Hydatidosis in Sheep and Goats Slaughtered at Bishoftu Hashim Export Abattoir: Prevalence and Risk Factors". *European Journal of Biological Sciences* 12.1 (2020): 17-25.
2. Alemu Y and Merkel RC. "Sheep and goats production and Handbook for Ethiopia". (2008): 2.
3. Alvarez CA., *et al.* "Echinococcus granulosus sensu lato genotypes infecting humans review of current knowledge". *International Journal of Parasitology* 44 (2014): 9-18.
4. Assefa H., *et al.* "Cystic echinococcosis amongst small ruminants and humans in central Ethiopia. Onderstepoort". *Journal of Veterinary Research* 82.1 (2015): 949-947.
5. Aynalem M., *et al.* "Major Cause of Organ and Carcass Condemnation and Its Financial Loss at Bishoftu Elfora Export Abattoir". *International Journal of Nutrition and Food Sciences* 4.3 (2015): 364-372.
6. Azlaf R and Dakkak A. "Epidemiological study of the cystic echinococcosis in Morocco". *Veterinary Parasitology* 137 (2006): 83-93.
7. Bayu Y., *et al.* "Prevalence and economic importance of liver parasites: Hydatid Cyst, Fasciola species and Cysticercus tenuicollis in sheep and goats slaughtered at Addis Ababa abattoir enterprise in Ethiopia". *Journal of Veterinary Medicine Animal Health* 5 (2013): 1-7.
8. Berhanu M., *et al.* "Prevalence of Pneumonia in Sheep and Goats Slaughtered at Elfora Bishoftu Export Abattoir, Ethiopia: A Pathological Investigation". *Journal of Veterinary Medicine*, (2019): 10.
9. Berhe G. "Abattoir survey on cattle hydatidosis in Tigray Region of Ethiopia". *Tropical Animal Health Production* 41 (2009): 1347-1352.
10. Cadmus SIB and Adesokan HK. "Causes and implications of bovine organs/offal condemnations in some abattoirs in Western Nigeria". *Tropical Animal Health and Production* 41.7 (2009): 1455-1463.
11. Central Statistical Agency. "The Federal Democratic Republic of Ethiopia; Central Statistical Authority Federal Democratic Republic of Ethiopia Agricultural samples Enumeration Statistical Abstract". (2009): 446-539.
12. Craig PS., *et al.* "Prevention and control of cystic echinococcosis". *The Lancet Infectious Diseases* 7 (2007): 385-394.
13. Fufa A and Debele H. "Major causes of organ condemnation for cattle and its financial impact at Wolaita Sodo municipality abattoir, southern Ethiopia". *Global Veterinaria* 11.6 (2013): 730-734.
14. Getachew E. "Major diseases of export-oriented livestock in export Abattoirs in/around Ada Liben Wereda, Debre Zeit, Faculty of Veterinary Medicine and Haramaya University, Ethiopia, DVM Thesis". (2008).
15. Getaw A., *et al.* "Hydatidosis: prevalence and its economic importance in ruminant slaughtered at Adama municipal abattoir, Central Oromia, Ethiopia". *Acta Tropica* 113.3 (2010): 221-225.
16. Hunde G., *et al.* "Small Ruminant Hydatidosis: Occurrence and Economic Importance in Addis Ababa Abattoir". *Global Veterinary* 8 (2012): 160-167.
17. Kebebe E., *et al.* "Hydatidosis of sheep and goats slaughtered At Addis Ababa Abattoir: Prevalence and Risk Factors". *Tropical Animal Health Production* 42 (2010): 803-805.

18. Mellau LSB, *et al.* "Aslaughterhouse survey of lung lesions in slaughtered stocks at Arusha, Tanzania". *Preventive Veterinary Medicine* 97.2 (2010): 77-82.
19. NMSA. "National Meteorology Service Agency, Addis Ababa, Ethiopia" (2003).
20. Nyero D., *et al.* "Prevalence of hydatid cysts in goats and sheep slaughtered in Soroti Municipal Abattoir, Eastern Uganda". *Africa Journal of Parasitology Research* 2 (2015): 148-151.
21. Radostits OM., *et al.* Constable, *Veterinary Medicine: A Textbook of the Diseases of Cattle, Horses, Sheep, Pigs and Goats*, Saunders, Edition., Saunders, London, UK, 10th edition (2010).
22. Regassa F., *et al.* "Study on the prevalence of cystic hydatidosis and its economic significance in cattle slaughtered at Hawassa Municipal abattoir, Ethiopia". *Tropical Animal Health and Production* 42 (2010): 977-984.
23. Tatek T., *et al.* "Cystic echinococcosis: prevalence and economic significance in small ruminants slaughtered at Elfora Export Abattoir, Bishoftu, Ethiopia". *Ethiopian Veterinary Journal* 21.2 (2017): 11-27.
24. Thrusfield M. "Sampling in Veterinary Epidemiology". 2nd edition. London: Blackwell Science (2005): 120-137.
25. Tilahun A and Terefe Y. "Hydatidosis: prevalence, cyst distribution and economic significance in cattle slaughtered at arbaminch municipality abattoir, southern Ethiopia". *Global Veterinaria* 11 (2013): 329-334.
26. Yimer A., *et al.* "Prevalence, Cyst Characterization and Economic Importance of Bovine Hydatidosis in Addis Ababa Abattoirs Enterprise, Ethiopia". *Journal of Animal Research* 6 (2016): 375-379.

Assets from publication with us

- Prompt Acknowledgement after receiving the article
- Thorough Double blinded peer review
- Rapid Publication
- Issue of Publication Certificate
- High visibility of your Published work

Website: www.actascientific.com/

Submit Article: www.actascientific.com/submission.php

Email us: editor@actascientific.com

Contact us: +91 9182824667