

Surgical Correction of Umbilical Hernia in Buffalo Calf: A Case Report

Dhurba DC^{1*} and Ranjana Ranabhat²

¹*Veterinary Hospital and Livestock Service Expert Center, Hetauda, Makawanpur, Nepal*

²*United Veterinary Center, Hetauda, Makawanpur, Nepal*

***Corresponding Author:** Dhurba DC, Veterinary Hospital and Livestock Service Expert Center, Hetauda, Makawanpur, Nepal.

Received: May 12, 2021

Published: May 24, 2021

© All rights are reserved by **Dhurba DC and Ranjana Ranabhat**.

Abstract

A four month old male buffalo calf with the history of bulge type swelling found at the point of umbilicus was brought to United Veterinary Center, Hetauda, Makawanpur, Nepal. Clinical examination revealed a reducible type small bulge mass with 4 fingers length and 3 fingers breadth hernial ring. Other clinical parameters were within the normal physiological limit. The case was corrected surgically by means of herniorrhaphy.

Keywords: Buffalo Calf; Bulge Type Swelling; Umbilicus; Herniorrhaphy

Introduction

Hernia is the protrusion of an organ or tissue outside the abdominal cavity through natural or an abnormal opening [1]. A discontinuation of the abdominal wall at the region of umbilicus resulting protrusion of the abdominal contents in to hernia sac is known as umbilical hernia [5]. Some hernias are reducible, means hernial mass can be returned to their normal location through hernial ring while non-reducible type of hernia cannot pushed back [1]. Hernia may be congenital or acquired [7]. In calf, umbilical hernia is commonly present due to failure of the normal closure of umbilical ring [4]. From such incomplete closure of umbilical ring the abdominal contents like intestine, omentum comes out [3]. Acquired cause of umbilical hernia includes weak abdominal wall (imperfect occlusion of umbilicus), deep wound, abscess, increased intra-abdominal pressure due to straining, constipation or diarrhoea, violent exercise etc [2].

This condition can be diagnosed by external digital palpation, clinical observation, or ultrasonography [4]. There are different methods for the correction of umbilical hernia such as ligation of hernia sac, suturing of hernia ring, use of clamps and surgical

correction [8]. But if the hernia is greater than 5 cm then the surgical correction (herniorrhaphy) is the treatment of choice for the correction of umbilical hernia [6].

Case Presentation

A male buffalo calf of 4 months was brought to United Veterinary Center, Hetauda with the history of bulge type swelling found at the point of umbilicus. According to owner bulge mass was present since birth and which tends to increase in size with age. The palpation at the site of swelling confirmed that the hernial mass is reducible type. The size of hernial ring was 4 fingers length and 3 fingers breadth. Clinical parameters such as heart rate, respiratory rate and temperature were within normal physiological range. No any other behavioral changes were noticed.

Surgical correction

The calf was restrained on right lateral recumbence. Cranial paravertebral regional nerve block was done by using 2% lignocaine. Then, the site of incision (umbilical area) was prepared for aseptic surgery by shaving, scrubbing, washing with Salvon*

(Cetrimide 3% and Chlorhexidine gluconate 1.5% solution). At operative site 2% lignocaine was infiltrated locally. After proper analgesia the animal was controlled in dorsal recumbency and about 7 cm long longitudinal midline incision was made over swelling mass. The skin was detached from subcutaneous tissues and the incision was continued through abdominal muscles and peritoneum avoiding blood vessels.

A part of small intestine was found as hernial content. Gently the intestine was repositioned into abdominal cavity through the umbilical ring. The hernial ring was closed by overlapping mattress suture after freshened the edges of hernial ring. Absorbable suture material (No. 2 catgut) was used to close the opening. The subcutaneous layer was sutured with No 2 catgut and skin with Nylon in interrupted suture pattern.

Recommended post-operative care

Systemic antibiotic:

- Penstrip-400[®] (Procaine penicillin G-200000 IU + Dihydro-streptomycin-200 mg per ml)

Sig. 1 ml/kg body weight, OD, I/M × 5 days.

Analgesic:

- Meloxin-I[®] (Meloxicam- 5 mg/ml per ml)

Sig. 1 ml/10 kg body weight, BID, I/M × 3 days.

Topical antibiotic:

- Nebanol[®] (Neomycin sulphate BP 5 mg +Bacitracin Zinc BP 250 IU per gram)

Sig. Apply on wound BID x 5 days.

Fly repellent and wound healing spray:

- Skin heal[®]

Sig. Apply TID × 5 days.

Regular dressing with 5% povidone iodine for 10 days.

Finally, on 12 day post-operative complete healing was recorded and the skin suture were removed on the same day.

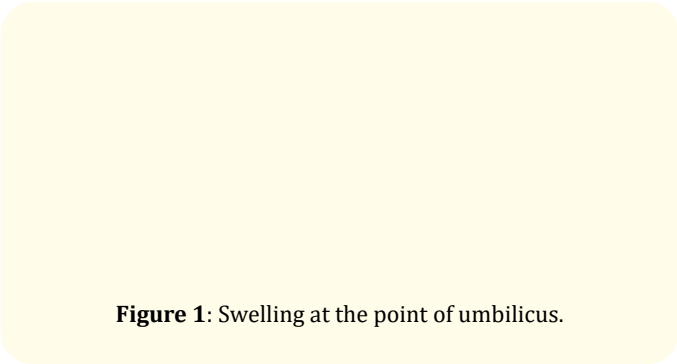


Figure 1: Swelling at the point of umbilicus.

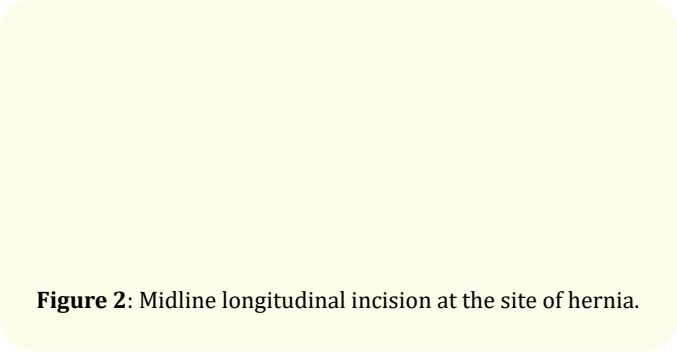


Figure 2: Midline longitudinal incision at the site of hernia.

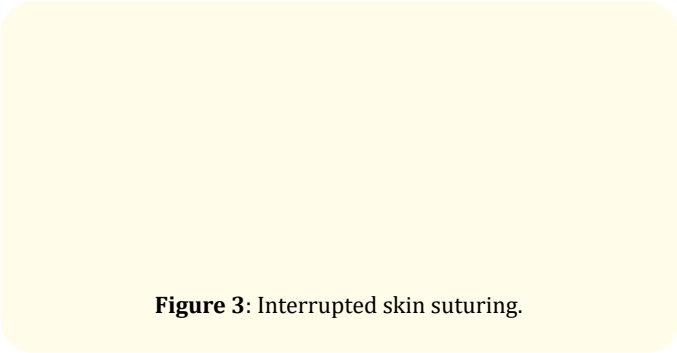


Figure 3: Interrupted skin suturing.



Figure 4: Recovered calf.

Conclusion

In a male buffalo calf the umbilical hernia was corrected successfully with herniorrhaphy. After proper diagnosis, timely operation and good post-operative care is major for the correction of umbilical hernia.

Conflict of Interest

The author declare that there is no any conflict of interest.

Bibliography

1. Alkhillani M A. "Abdominal Hernia in A Mesopotamia Buffalo calf". *Al-Anbar Journal of Veterinary Sciences* 12.1 (2019).
2. Greber Deborah., *et al.* "Occurrence of congenital disorders in Swiss sheep". *Acta Veterinaria Scandinavica* 55.1 (2013): 1-7.
3. Haben Fesseha MVSc. "Umbilical Hernia in Cross Holstein Friesian Calf and its Surgical Management: A Case Report". *Hernia* 5 (2020): 6.
4. Haile Y., *et al.* "A study on the prevalence of umbilical hernia in calves in and around Gondar Town, North Gondar, North West Ethiopia". *International Journal of Veterinary Sciences and Animal Husbandry* 2.2 (2017): 11-15.
5. Iqbal U., *et al.* "Surgical Correction of Umbilical Hernia in Non-descript Buffalo Calf-A Case Study". *Biomedical Letters* 5.1 (2019): 15-17.
6. Kumar Vineet., *et al.* "Acellular dermal grafts for the reconstruction of umbilical/ventral hernias in buffalo calves". *Veterinary Practitioner* 13.1 (2012): 12.
7. Radostits Otto M., *et al.* "Veterinary Medicine E-Book: A textbook of the diseases of cattle, horses, sheep, pigs and goats". Elsevier Health Sciences (2006).
8. Sutradhar Bibek Chandra., *et al.* "Comparison between open and closed methods of herniorrhaphy in calves affected with umbilical hernia". *Journal of Veterinary Science* 10.4 (2009): 343.

Volume 3 Issue 6 June 2021

© All rights are reserved by Dhurba DC and Ranjana Ranabhat.