



## Effects of Aqueous Leaf Extract of *Psidium guajava* (Guava) on Paracetamol Induced Kidney Damage in Wistar Rats

Hyacinth Tochukwu Eze<sup>1\*</sup>, Ezejindu Damian Nnabuihe<sup>2</sup>, Joshua Izuchukwu Abugu<sup>2</sup> and Ifeanacho Ezetaonu Abireh<sup>3</sup>

<sup>1</sup>Department of Internal Medicine, Nnamdi Azikiwe University, College of Medicine Nnewi Campus, Anambra State, Nigeria

<sup>2</sup>Department of Anatomy, Faculty of Basic Medical Sciences, Nnamdi Azikiwe University, Nnewi Campus, Anambra State, Nigeria

<sup>3</sup>Department of Anatomy, Faculty of Basic Medical Sciences, Enugu State University of Science and Technology, Enugu State, Nigeria

**\*Corresponding Author:** Hyacinth Tochukwu Eze, Department of Internal Medicine, Nnamdi Azikiwe University, College of Medicine Nnewi Campus, Anambra State, Nigeria.

**Received:** May 27, 2024

**Published:** June 30, 2024

© All rights are reserved by **Hyacinth Tochukwu Eze., et al.**

### Abstract

Paracetamol which is one of the most commonly consumed drugs all over the world has shown some toxic effect when consumed in large quantity or consistently. However, it is not clear whether or not the toxicity is related to the vital organs like the liver and kidney, hence the present study is aimed towards showing not only the toxic effect of paracetamol on the liver and kidney but more importantly investigating the protective effect of aqueous extract of *Psidium guajava* leaf against paracetamol induced toxicity on these organs. Sixteen (16) adult wistar rats weighing 180-220g were divided into four groups of four animals each. Group A was given normal rat feed and water as the control; group B was administered 100 mg/kg body weight of paracetamol, group C was administered 250 mg/kg body weight of *Psidium guajava* leaf, while group D was administered 100 mg/kg of paracetamol + 250 mg/kg of aqueous leaf extract of *Psidium guajava*. All the treatments were given daily orally for twenty one days. Twenty four hours after the last administration, the animals were anesthetized under chloroform vapour and dissected. The liver and kidney tissues were harvested, weighed and fixed in 10% formal saline for histological studies. Blood for serum preparation was collected through ocular puncture for histochemical studies. Evaluations of marker enzymes were carried out using randox kit method. The serum levels of Aspartate aminotransferase (AST), Alanine aminotransferase (ALT), Alkaline phosphatase (ALP), creatinine and urea in group B was significantly higher ( $P < 0.005$ ) than the control group A and groups C and D. The result of this study show that the paracetamol administered damaged the two organs and it also shows that the aqueous extract of *Psidium guajava* has an ameliorating effect on the paracetamol induced organs. The extract may contain antioxidant and chemoprotective properties against paracetamol induced toxicity.

**Keywords:** Paracetamol; *Psidium guajava*; Aspartate Aminotransferase (AST)

## Introduction

Paracetamol (also known as acetaminophen) is one of the most commonly used non-steroidal anti-inflammatory drugs. It has been long recognized as potentially lethal because of dose-related hepatic and often renal injury. Low dose ingestion having harmful consequences appear to be more likely associated with alcohol use. Most people are only at risk of liver toxicity if they take more than the normal dose for instance taking 10-15 grams more than twice the recommended dose [1].

The liver is a vital organ of digestive system present in vertebrate and some other animals. It has a wide range of functions including detoxification, protein synthesis, and production of biochemical necessary for digestion. In humans, the liver is the largest of gland in the body and the second largest organ in the body. It makes up about 2.5% of the adult body weight [3]. The causes of liver damage ranges from Cellular Necrosis to Liver Cirrhosis, but the toxicity of paracetamol intake will be the major focus of this present study. Hepatotoxicity is a damage or injury to the liver caused by a drug, chemical, or other agents. More than 900 drugs have been implicated in causing liver injury, and this includes high dose of paracetamol [2].

Paracetamol also has direct actions on the kidney. The kidneys regulate the balance of ions known as electrolytes in the blood, along with maintaining acid base homeostasis. They also move waste products out of the blood and into the urine, such as nitrogen-containing urea and ammonium. Kidneys also regulate fluid balance and blood pressure. They are also responsible for the reabsorption of water, glucose, and amino acids [3].

Acute ingestion of large doses can cause damage to the kidney. Diseases of the kidney are diverse, but individuals with kidney disease frequently display characteristic clinical features. Common clinical conditions involving the kidney include the nephritic and nephritic syndromes, renal cysts, acute kidney injury, chronic kidney disease, urinary tract infection, kidney stones, and urinary tract obstruction [3].

However, the use of plants for therapeutic purpose has proved helpful in restoring normalcy to organs, and this practice is as old as the history of man [4]. It is generally known that the consumption of a variety of local herbs and vegetables by man contributes significantly to the improvement of human health, in terms of pre-

vention and or cure of diseases because plants have long served as a useful and natural source of the therapeutic agents. Moreover, traditional medicine is greatly relied upon especially by rural dwellers for the treatment of various ailments.

Guava (*Psidium guajava*) is a common shade tree or shrub in door-yard gardens in the tropics. The tree is easily identified by its distinctive thin, smooth, copper-coloured bark that flakes off showing a greenish layer beneath. It has been reported that the phytochemical analyses of guava leaf products reveals the presence of more than 20 isolated compounds including alkaloids, anthocyanins, carotenoids, essential oils, fatty acids, lectins, phenols, saponins, tannins, triterpenes, and vitamin C [5]. Guava fruit contain high vitamin C than citrus fruits and also an appreciable amount of vitamin A [6]. Guava is used not as food but also as folk medicine in subtropical areas around the world because of its pharmacological activities. The leaf extract of guava has traditionally been used for treatment of diabetes in East Asia and other countries. The leaves of guava are rich in flavonoids, in particular, quercetin. Many pharmacological studies have demonstrated the ability of this plant to exhibit antioxidant, hepatoprotective, anti-allergy, anti-diabetes, anti-inflammatory and anti-microbial effects. More research on guava leaves reveals that it is of great importance in the regenerative capability of liver and kidney damaged by paracetamol. Thus this research is aimed at showing the toxicological effect of paracetamol to the kidney and liver and its remedy using aqueous extract of *Psidium guajava*.

## Materials and Methods

### Location and duration of the study

This study was carried out at the Anatomy Department, Nnamdi Azikiwe University, Nnewi Campus, Anambra State, Nigeria. The rats were made to acclimatize for a period of two weeks after which the test substance was administered for 28 days; the entire experiment lasted for six weeks.

### Ethical approval

This study was approved by the Faculty of Basic Medical Sciences, College of Health Sciences Nnewi, Nnamdi Azikiwe University.

### Collection and preparation of extract

The guava leaves was collected from a family garden at Igbo-ukwu town, Anambra state. The guava leaves were authenticated by the Department of Botany, Nnamdi Azikiwe University Awka. The

leaves were washed and air dried completely for two weeks. The guava leaves were grounded into powdered form using Laboratory blender and weighed 400g. The powdered fruit was dissolved in 4L of distilled water and kept for 48hours, and after which it was filtered using filter paper. The extract was oven dried into a gel-like form using hot air oven.

#### Procurement of drug

Paracetamol was purchased from a standard pharmacy store at Nnewi, Anambra state.

#### Acute toxicity test ( $LD_{50}$ ) of paracetamol

The acute toxicity test of paracetamol was carried out in the Department of Physiology, Faculty of Basic Medical Sciences, College of Health Sciences Nnewi, Nnamdi Azikiwe University according to the method employed by [25]. In this study, a total of 13 wistar rats were used. The test was carried out in two phases. In phase 1, nine (9) adult wistar rats were used and they were grouped into three groups of three animals each. Group 1 received 10 mg/kg of paracetamol, group 2 received 50 mg/kg of paracetamol while group 3 received 100 mg/kg of paracetamol. The animals were observed over a period of 24hrs for mortality. From the result of phase 1, the second phase was carried out. In this phase, 4 adult wistar rats were used and they were grouped into four groups of one animal each. Group 1 received 200 mg/kg of paracetamol, group 2 received 300 mg/kg of paracetamol, and group 3 received 400 mg/kg of paracetamol while group 4 received 500 mg/kg of paracetamol. They animals were also monitored over a period of another 24hrs for mortality.  $LD_{50}$  was determined by the formula:

$$LD_{50} = \sqrt{(a \times b)}$$

Where A = the lowest dose that brought death

B = the highest dose that did not kill

#### Acute toxicity test ( $LD_{50}$ ) of aqueous extract of *Psidium guajava*

The acute toxicity test of aqueous leaf extract of guava leaves was carried out in the Department of Physiology, Faculty of Basic Medical Sciences, College of Health Sciences Nnewi, Nnamdi Azikiwe University according to the method employed by Dietrich Lorke (1983). In this study, a total of 13 wistar rats were used. The test was carried out in two phases. In phase 1, nine (9) adult wistar rats were used and they were grouped into three groups of three animals each. Group 1 received 10 mg/kg of *Psidium guajava* leaf extract; group 2 received 100 mg/kg *Psidium guajava* leaf extract while group 3 received 1000 mg/kg of guava leaf extract. The ani-

mals were observed over a period of 24hrs for mortality. From the result of phase 1, the second phase was carried out. In this phase, 4 adult wistar rats were used and they were grouped into four groups of one animal each. Group 1 received 2000 mg/kg of *Psidium guajava* leaf extract, Group 2 received 3000 mg/kg of *Psidium guajava* leaf extract, and group 3 received 4000 mg/kg of guava leaf extract while group 4 received 5000 mg/kg of *Psidium guajava* leaf extract. They animals were also monitored over a period of another 24hrs for mortality.  $LD_{50}$  was determined by the formula:

$$LD_{50} = \sqrt{(a \times b)}$$

Where A = the lowest dose that brought death

B = the highest dose that did not kill

#### Experimental animals and design

The research was done with sixteen adult albino wistar rats comprising of male rat of about 3 month old. The rats were bought from a local farm at Enugu and moved to the site of the experiment. They were housed in 4 standard cages and were divided into 4 groups (A to D). The weight of each rat was measured using an analytical weighing balance. They were fed with feed and water for a period of two weeks to enable them acclimatizes to their new environment before the experiment began. During the acclimatization period, the rats were fed with normal grower's mesh of known weight of about 100g daily and given Water. The animal care and handling was conducted in compliance with the National Regulations for Animal Research. University Ethical committee reviewed the protocols, which were consistent with International Animal Welfare Guidelines. The group A served as the Control group while group B, C, and D served as the Test groups.

The rats were weighed before the administration of the test substances commenced.

The administration of the *Psidium guajava* was done as follows:

- Group A (Control) received only water and feed for four weeks.
- Group B received only Paracetamol per body weight for 21 days.
- Group C received only extract of *Psidium guajava* per body weight for 21 days.
- Group D received both Paracetamol for 21 days and extract of *Psidium guajava* leaf for two weeks.

Organ collection

The rats were sacrificed after 21days of administration, the kidney was harvested and put in a normal saline to maintain normal physiological conditions after which they were weighed and fixed in 10% formal saline for Histological processing.

Tissue processing

After weighing the organs, a small part of the kidney tissues were cut out and immediately fixed in 10% formal saline in order to preserve the various constituents of the cells in their normal micro anatomical position and to prevent autolysis and putrefaction. After fixation the tissues were dehydrated to remove water and other substances. This was carried out in different percentages of alcohol 50%, 70% and 95% absolute. In each grade of alcohol, tissues were changed twice for two (2) hours, one (1) hour for each change. After dehydration, tissues were cleared in xylene for two (2) hours after which infiltration was done in molten paraffin wax at a temperature of 60oc for two (2) hours, each in two changes. When the paraffin wax cools, it sets as a hard block which allows for easy sectioning of the tissues. The tissue sections were produced by normal histochemical methods of dehydration, clearing, impregnation, embedding, sectioning and staining (with H&E).

The micrographs of the relevant stained sections were subsequently taken with the aid of a light microscope.

Statistical analysis

The data were analyzed using SPSS version 23. Values were represented as MEAN and SEM, Relative Organ weight (Brain) were analyzed using One way ANOVA, followed by Post Hoc LSD multiple comparison. Body weight was analyzed using Student dependent T-test. Values were considered significant at  $P < 0.05$ .

Result

Physical and behavioural changes

During the period of acclimatization, all the rats were healthy with smoothly laid hairs on their skin, pinkish eyes and normal skin colour. There was also an increase in size. But after the commencement of administration, group A (control group) showed no clinical signs while the remaining groups had labor breathing, staggering, sluggishness which was more pronounced in group B.

The effect of aqueous leaf extract of guava on paracetamol induced kidney damage on body weight

Groups Body weight (g)		MEAN	±SEM	P-VALUE	T-VALUE
Group A (Control)	Initial	155.00	±25.00		
	Final	197.50	±11.81	0.273	-1.340
Group B	Initial	152.50	±4.78		
	Final	200.00	±0.00	0.002*	-9.922
Group C	Initial	162.50	±8.53		
	Final	202.50	±2.50	0.016*	-4.899
Group D	Initial	195.00	±22.17		
	Final	210.00	±7.07	0.406	-0.965

Table 1: Shows the effect of aqueous leaf extract of Guava on paracetamol induced Kidney damage on Body weight.

All data were analyzed using Student dependent T-test and data were considered significant at  $P < 0.05$ . \* $P < 0.05$  means significant, and  $P > 0.05$  means not significant.

Result from table 1 above shows a non-significant ( $P > 0.05$ ) increase in the body weight in-group A, when the initial weight was compared to the final weight. Group B had a significant ( $P < 0.05$ ) increase in the body weight when the initial weight was compared to the final weight. Group C had a significant ( $P < 0.05$ ) increase in the body weight when the initial weight was compared to the

final weight. Group D had a non-significant ( $P > 0.05$ ) increase in the body weight when the initial weight was compared to the final weight.

The effect of aqueous leaf extract of guava on paracetamol induced kidney damage relative kidney weight

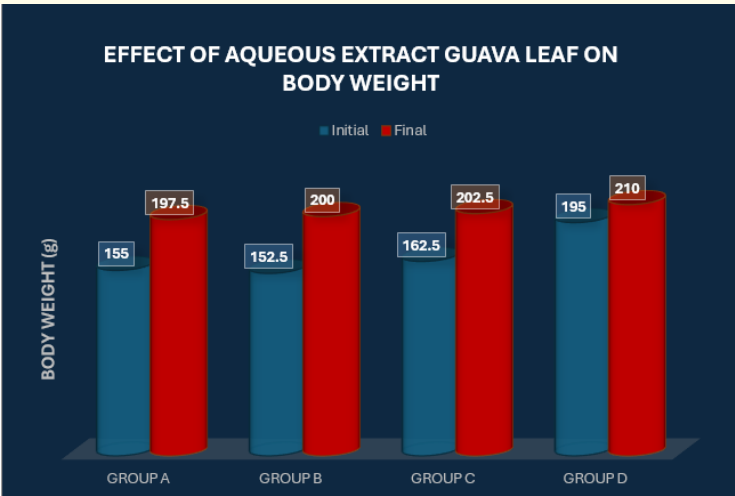


Figure 1: The effect of aqueous leaf extract of guava on paracetamol induced kidney damage on body weight.

Organ weight Groups		MEAN	±SEM	P-VALUE	F-VALUE
Relative kidney weight (g)	Group A (Control)	0.72	±0.03		
	Group B	1.94	±0.00	0.000*	95.068
	Group C	0.70	±0.01		
	Group D	0.91	±0.02		

Table 2: Shows the effect of aqueous extract of guava leaf on paracetamol induced kidney damage on the relative kidney weight. All data were analyzed using One-way Anova, and data were considered significant at  $P < 0.05$ . \* $P < 0.05$  means significant and  $P > 0.05$  means not significant.

Result from table 2; shows a significant ( $P < 0.05$ ) difference between the relative kidney weight when the control group was compared with group B, C, and D.

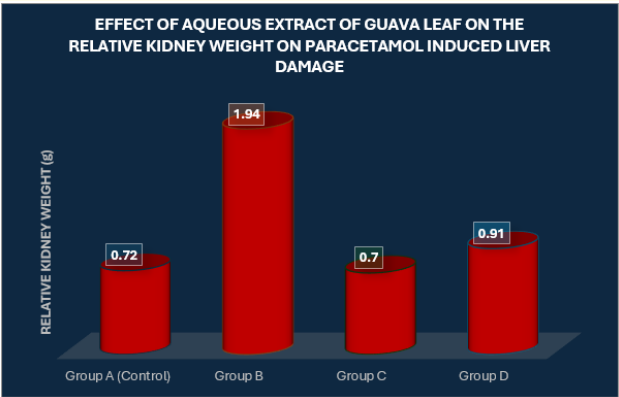


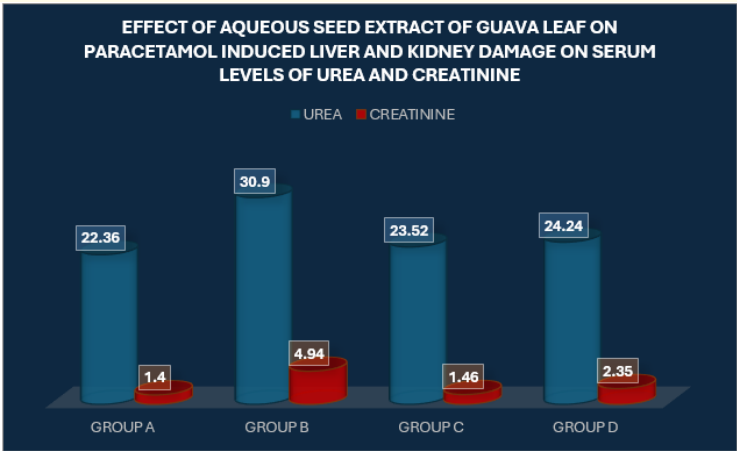
Figure 2: Shows the effect of aqueous extract of guava leaf on paracetamol induced kidney damage on the relative kidney weight.

The effect of aqueous extract of guava leaf on paracetamol induced kidney damage on serum levels of creatinine and urea

GROUPS	UREA (mg/dl)	CREATININE (mg/dl)
A	22.363.00	1.400.90
B	30.902.99	4.940.56
C	23.520.14	1.461.44
D	24.241.21	2.353.26
F-RATIO	6.218	1.221
PROB. OF SIG.	<0.005	<0.005

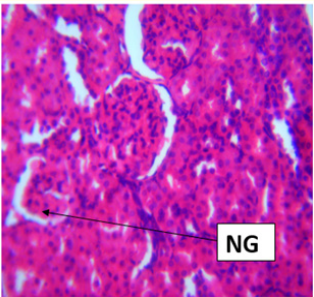
**Table 3:** Shows the effect of aqueous extract of guava leaf on paracetamol induced liver and kidney damage on serum levels of creatinine and urea.

Result from the table above shows a significant increase ( $P < 0.05$ ) in group B, C, and D when compared to group A. Serum creatinine level had a significant ( $P < 0.05$ ) increase ( $P < 0.05$ ) in group B, C, and D when compared group A.

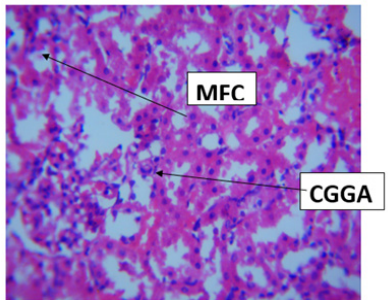


**Figure 3:** Shows the effect of aqueous extract of guava leaf on paracetamol induced liver and kidney damage on serum levels of creatinine and urea.

Histopathological findings

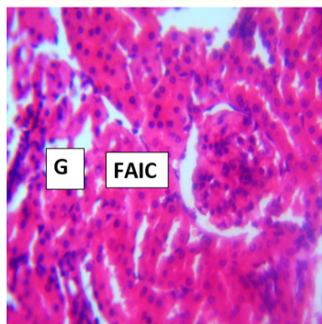


**Figure 4:** Photomicrograph of 1 control section of kidney (X400) (H/E) shows well perfused normal renal architecture with glomeruli (G), renal tubules (RT) and tubular cell (TC) well represented.

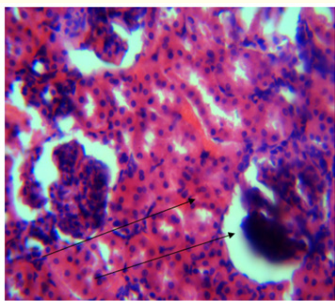


**Figure 5:** Photomicrograph of 2 section of kidney administered 0.5ml of paracetamol for 21 days (X400) (H/E) shows moderate degeneration, poorly perfused renal tissue with necrosed glomeruli (NG) fatty change (MFC) and cytoplasmic ground glass appearance (CGGA).





**Figure 6:** Photomicrograph of 3 section of kidney administered 0.4 ml of guava leaf extract for 21 days (X400) (H/E) shows mild aggregate inflammation cell (MIIC) otherwise normal.



**Figure 7:** Photomicrograph of 4 section of kidney administered 0.4 ml of paracetamol and guava leaf extract 21 days (X400) (H/E) shows moderate regeneration of the renal tubules (RT) and tubular cell (TC) with necrosed glomeruli (NG).

## Discussion

Paracetamol (acetaminophen) is a widely used analgesic and antipyretic drug. Several studies have reported the toxic, gastrointestinal and musculoskeletal effect of this drug [7]. It has been reported that acute overdose of paracetamol can cause fatal liver and kidney damage and its toxicity is the foremost cause of acute liver failure in Western world [8].

Plants play an essential role in the health care needs for the treatment of diseases and to improve the immunological response against much pathology [9]. Studies have shown that the consumption of fruits, vegetables and seeds can be helpful to prevent the risk factor of many diseases due to the bioactive compounds. Many plants have been used for the purpose of reducing risk factors [10]. Amongst these plants with great therapeutic potentials is *Psidium*

*guajava* which is popularly known as guava. *Psidium guajava* is a small medicinal tree that is native to South America. It has been used traditionally as a medicinal plant throughout the world for a number of ailments [11]. The main constituents of guava are vitamins, tannins, phenol, flavonoids, saponins, essential oils and triepernoid acids [12]. Guava leaves extract has analgesic, anti-inflammatory, anti-microbial, hepatoprotective and anti-oxidant activities.

In the present study, the mean of the initial body weight (g) of the control group A was  $155 \pm 25.00$  and the final body weight was  $197.50 \pm 11.81$  having a significant increase with P-value of 0.273. This could be physiological as the only substance they were exposed to was water and feed. These are signs of relative healthiness in the control group. The initial mean body weight of test group B which received paracetamol was  $152.50 \pm 4.78$  and the final body weight was  $200 \pm 0.00$  with a significant P-value of 0.002 when compared to the control group, there was an increase in the body weight. This shows that although paracetamol caused damage to the liver and kidney, it did not cause a decrease in the food intake. This goes in line with the research by [7], who reported that paracetamol caused significant changes in body weight of rats after treatment of rats for 42days. Test group C which received guava leaves extract showed a significant increase in the initial and final mean weight with a P-value of 0.016. This can be attributed to *Psidium guajava* leaf extract causing an increase in the feeding capacity of the rats as a result of the saponins present in guava leaf extract. Test group D received both paracetamol in the first 2 weeks and *Psidium guajava* extract in the last 2 weeks. This resulted to a significant increase in the final mean body weight with a P-value of 0.406. This shows that the extract served as a dietary supplement enhancing growth on the body weight of the rats.

Relative organ weight result showed a significant increase in relative weight of the liver and kidney of group B when compared to the control group A. This is probably as a result of inflammation caused by paracetamol. Test groups C and D which received *Psidium guajava* L. extract, paracetamol + guava leaf extract respectively have relative liver and kidney weights similar to group A. This suggests that after administration of paracetamol and further treatment with *Psidium guajava* leaf extract the relative weights of the liver and kidney were reduced to almost the weight of the control group. This could be as a result of anti-inflammatory proper-

ties possessed by the leaf extract of guava leaf. This agrees with a research by [16], who studied the hepatoprotective activity of different extract of *Psidium guajava* in acute experimental injury induced by tetrachloride and paracetamol, from his result the organ weight was restored to normalcy.

In the present study, test group B which received only paracetamol showed a significant increase in the activities of the liver enzymes AST and ALT as a result of hepatocellular necrosis or membrane damage to the liver [13]. Increase in the level of ALP is due to the increased synthesis in the presence of increased biliary pressure. [14] also stated that paracetamol treatment leads to elevated levels of liver marker enzymes and bilirubin. [15] also showed a significant increase in the level of liver enzymes in paracetamol treated rats when compared with other groups. Test groups C and D showed a significant decrease in the level of liver enzymes when compared to group B. Treatment with *Psidium guajava* leaf extract suppressed the elevated serum levels of AST, ALT and ALP towards their respective normal levels. This agrees with research by [24] which stated that *Psidium guajava* leaf has the ability to reduce activity of serum enzymes and enhance antioxidant defiance status. [17] studied the effect of aqueous extract of *Psidium guajava* on liver enzymes and histological integrity, the result obtained showed that the extract had no significant effect on the activities of the serum liver enzymes. [16] studied the hepatoprotective activity of different extract of *Psidium guajava* in acute experimental injury induced by tetrachloride and paracetamol. The result showed that aqueous extract of guava leaf reduced elevated serum levels of enzymes AST, ALT and ALP. Also the result of the present study shows that paracetamol induced significant increase in the concentration of plasma urea and creatinine in group B as compared to normal control group. There was significant decrease in urea and creatinine level in group C and D compared to group B which received paracetamol. This shows the healing effect of aqueous extract of *Psidium guajava* leaf.

In the present study, the histology of group A control section of liver showed normal hepatic architecture with well perfused cytoplasm (WPC), hepatocytes (H) and central vein (V). Histological result of group B section of liver administered with paracetamol showed moderate degeneration of hepatic tissues with scanty hepatocyte, focal aggregation of inflammatory cell (FAIC). This goes in line with research by [14], in which the paracetamol treated liver section showed congestion, mild centrilobular degeneration

of hepatocytes, mild bile duct hyperplasia and multifocal cell infiltration. [18] also documented that the liver of rats treated with paracetamol showed portal tracts with dilated and congested veins. Periportal necrosis of the hepatocytes that surround the portal areas and inflammatory infiltration were also seen. Paracetamol induced liver damage is the second leading cause of liver transplantation and accounts for considerable level of mortality and morbidity [14].

Histological result of group A control section of kidney showed well perfused normal renal architecture with glomeruli (G), renal tubule (RT), and tubular cell well represented. Histological result of group B section of kidney administered with paracetamol showed moderate degeneration poorly perfused renal tissues with necrosed glomeruli (NG) and fatty change (FC). This could possibly be as a result of the administration of paracetamol at a higher dose. This goes in line with research by [19], which shows severe degenerative changes in the kidney of group treated with paracetamol at higher dose. Histological result of group C section of liver administered with *Psidium guajava* leaf extract shows normal hepatic features with central vein (CV) and well perfused cytoplasm, thus no damage occurred. This is attributed to the phytochemical contents possessed by the extract. This corresponds with research by [17] who studied the effect of aqueous extract of *Psidium guajava* on liver enzymes and histological integrity, the result obtained showed that the extract is not hepatotoxic. Histological result of group C section of kidney administered with *Psidium guajava* leaf extract shows mild aggregate inflammatory cell (MIIC) otherwise normal. This shows that administration of *Psidium guajava* did not induce any histopathological lesion on the liver and kidney tissues. This goes in line with a research work by [20] which stated that administration of extract of guava leaves at high or low dose did not induce any histopathological lesions to the kidney. Histological result of group D section of liver administered with paracetamol and *Psidium guajava* shows moderate regeneration with mild focal aggregate of inflammatory cell (FAIC). This could be as a result of flavonoids present in the extract. Flavonoids have been reported to have anti-oxidative effect [21]. Anti-oxidants have been proven to play an important role in the regulation of a vast array of physiological and pathological processes. They principally contribute to the deleterious effect of reactive oxygen and other free radicals [22]. Furthermore saponins also present in the extract is known to have hypocholesterolemic activities [23] which may aid in lessening the metabolic burden on the liver. Histological result of group



D section of kidney administered with paracetamol and *Psidium guajava* shows moderate regeneration of the renal tubules (RT) and tubular cells (TC) with necrosed glomeruli (NG). This shows that aqueous extract of *Psidium guajava* has hepatoprotective and renoprotective properties towards paracetamol damage.

### Conclusion

The result showed that aqueous extract of *Psidium guajava* leaf did not induce adverse changes in the biochemical parameters of serum levels of AST, ALT, ALP, creatinine and urea and no histopathological lesions was observed in the liver and kidney tissues instead it remedied the damage caused by paracetamol. This suggests that aqueous extract of *Psidium guajava* leaf has ameliorating effect towards paracetamol induced liver and kidney damage.

### Recommendation

Having analyzed the results of this experiment, I recommend that:

- Freshly prepared aqueous extract of guava leaf should be used to ameliorate mild damage caused by paracetamol to the liver and kidney.
- Awareness should be created on the toxic effect of overdose of paracetamol.
- More research should be done on the effect of aqueous extract of guava leaf on other organs.

### Bibliography

1. Rumack B H and Matthew H. "Acetaminophen poisoning and toxicity". *Pediatrics* 55.6 (1957): 871-876.
2. Friedman Scott E., *et al.* "Current Diagnosis and Treatment in Gastroenterology". New York: Lang Medical Books/Mc Graw. 667-679.
3. Moore KL., *et al.* "Clinical Oriented Anatomy". Walter Kluwer Lippincott Williams and Wilkins (2010).
4. Tapsell LC., *et al.* "Health benefits of herbs and spices; the past, the present, the future". *Medical Journal of Australia* 185.4 (2006): 4-24.
5. Chun LJ., *et al.* "Acetaminophen hepatotoxicity and acute liver failure". *Journal of Clinical Gastroenterology* 43.4 (2009): 342-349.
6. Conway Peter. "Tree medicine-A comprehensive guide to the healing power of over 70 trees". Judy Piatkus Publisher Ltd. (2001).
7. Oyediji KO., *et al.* "Effect of paracetamol on haematological and reproductive parameters in male albino rats". *Journal of Pharmacy and Biological Sciences* 4.6 (2013): 65-70.
8. Daly FF., *et al.* "Guideline for the management of paracetamol poisoning in Australia and New Zealand". 188 (2008): 269-270.
9. Borchers AT., *et al.* "Shosaiko-to and other Kampo (Japanese herbal) medicines: a review of their immunomodulatory activities". *Journal of Ethnopharmacology* 73 (2000): 1-13.
10. Wu JW., *et al.* "Inhibitory effects of guava leaf extract and its active compounds on the glycation process of protein". *Food Chemistry* 113 (2008): 78-84.
11. Pathak RK and Ojha CM. "Genetic resources of guava". New Delhi: Malhotra Publishing House. 1 (1993): 143-147.
12. Haida KS and Baron A. "Phenolic compounds and anti-oxidant activity of two varieties of guava". *Rev Cienc Saude* 28 (2011): 11-29.
13. Willianson EM., *et al.* "Selection, preparation and pharmacological evaluation of plant materials" 13 (1996).
14. Sabina EP., *et al.* "Hepatoprotective and antioxidant potential of Wiltania somnifera against paracetamol induced liver and kidney damage in rats". *International Journal of Pharmacy and Pharmaceutical Sciences* 2 (2013).
15. Ajayi IA., *et al.* "Preliminary Phytochemical Analysis of Some Plant Seeds". *Research Journal of Chemical Sciences* 1 (2011): 58-62.
16. Friday E., *et al.* "Effect of aqueous extract of *Psidium guajava* leaf on liver enzymes, histological integrity and haematological indices". *Journal of Biological Sciences* 3.1 (2010): 1-6.
17. Roy CK and Das AK. "Comparative evaluation of different extracts of *psidium guajava* linn for hepatoprotective activity". *Pakistan Journal of Pharmaceutical Science* 23 (2000): 15-20.

18. Suchismita R., *et al.* "Acetaminophen induced kidney failure in rats: A dose response study". *Journal of Biological Sciences* 15.4 (2015): 187-193.
19. Ezejindu DN., *et al.* "Histological effect of guava leaf aqueous extract on kidneys of adult wistar rats". *International Journal of Research in Medical and Health Sciences* 4.3 (2014): 1-6.
20. Abd Algader NNE. "Chemopreventive effect of *Coriandrum sativum* fruits on hepatic toxicity in male rats". *World Journal of Medical Sciences* 8.4 (2007): 322-333.
21. Middleton E. "Biological properties of plant flavonoids: An overview". *International Journal of Pharmacology* 34.95 (1996): 344-348.
22. Barber DA and Harris SR. "Oxygen free radicals and anti-oxidant". *A Review Journal of Pharmacology* 534.16 (1994): 26-35.
23. Price KK., *et al.* "The chemical significance of saponins in food and feeding stuffs". 26 (1987): 127-135.
24. Jayanthi P and Lalitha P. "Reducing Power of the Solvent Extracts of *Eichhornia crassipes* (Mart.) Solms". *International Journal of Pharmacy and Pharmaceutical Sciences* 3 (2011): 3-5.
25. Lorke D. "A New Approach to Practical Acute Toxicity Testing". *Archives of Toxicology* 54.4 (1983): 275-287.