



Aortic Prosthesis Infection on Duodenal Erosion: Case Report

H Dabachi*, AA Amar, S EL Youbi, H Naouli, H Jiber and A Bouarhoum

Vascular Surgery Department, Hassan II University Hospital, FES, Morocco

***Corresponding Author:** H Dabachi, Vascular Surgery Department, Hassan II University Hospital, FES, Morocco.

Received: February 19, 2025

Published: February 26, 2025

© All rights are reserved by
H Dabachi, et al.

Abstract

Vascular prosthesis infections require medical and surgical management. Probabilistic antibiotic therapy may be initiated before surgical treatment in the event of severe sepsis, septic shock or threat of septic mechanical complications (anastomotic detachment, aneurysmal rupture). It is based on a combination of a glycopeptide, a broad-spectrum beta-lactam and an aminoglycoside. Once the causative bacteria(s) have been identified by blood cultures and/or intraoperative samples and the antibiogram data are known, specific antibiotic therapy with the narrowest possible spectrum will be prescribed for a total period of six weeks postoperatively. In the event of non-optimal surgical treatment, suppressive antibiotic therapy will be initiated following the usual antibiotic treatment [8].

Surgical management of aortic prosthesis infection includes excision of the prosthesis and revascularization of the lower limbs. The most commonly used material in France is cryopreserved arterial allograft or the use of femoral veins taken from the patient. These replacements with autogenous material allow in situ revascularization and have better resistance to infection. The other possibility of revascularization is extra-anatomical by axillo-bi-femoral bypass, especially used in cases of prostheticodigestive fistula [9].

The choice of medical-surgical treatment depends on the mode of contamination of the prosthesis, the incriminated germ, the location of the infected prosthesis and the general condition of the patient [8].

Keywords: Aortic Graft Infection; Duodenal Erosion; Gastrointestinal Hemorrhage; Aorto-Digestive Fistula; Medical-Surgical Treatment

Introduction

The development of synthetic arterial grafts has been a major advance in vascular surgery, leading to acceptable results. However, graft infection has quickly emerged as an uncommon but serious complication. Among infections in vascular surgery, aortic graft infection is the most feared complication, and remains a complex problem despite many improvements in graft manufacturing, implantation techniques, and antibiotic prophylaxis [1].

A wide variety of treatments have been proposed for this complication, but with poor results due to the high mortality and amputation rates; IPI remains a great challenge. Overall graft infection rates are approximately 2%, reaching 6% in some series [1-3].

In Denmark, approximately 1000 patients undergo graft aortic replacements each year (Danish Vascular Database 1994-2004).

It is still difficult to eradicate graft infection. If not recognized or treated appropriately, the potential consequences are graft failure, life-threatening hemorrhage, or sepsis [2,3]. Even in highly experienced centers and in recent series, mortality and amputation rates related to graft infections remain very high [1-5]. However, the clinical presentation of intracavitary graft infection (ICG) can be nonspecific and late (up to more than 10 years after surgery) [2-4]. A nonspecific presentation with malaise, back pain, fever, gastrointestinal bleeding, increased sedimentation rate, hydronephrosis, or ischemia due to graft occlusion should be considered as potential manifestations of graft infection and warrant diagnostic

workup. The clinical presentation may be frank, particularly in cases of infection at the femoral level with swelling, local warmth or tenderness, a pulsatile mass, or discharge through a fistula [6,7]. In all other circumstances, a certain degree of diagnostic uncertainty exists until the prosthesis is surgically explored and/or cultured. The retroperitoneal location of the prosthesis makes the diagnosis difficult, particularly in cases without clinical symptoms.

In this work, we report the case of a 37-year-old patient, admitted for late infection of the aortic prosthesis, 2 years after its placement, revealed by digestive symptoms of hematemesis and melena following erosion of the duodenum.

Observation

A 35-year-old male patient consulted the emergency room for two episodes of melena and hematemesis with fever.

This patient has a history of: follow-up for Behçet's disease, operated in 2021 for ruptured aneurysm of the infrarenal abdominal aorta with placement of an aorto-aortic bypass, reoperation in 2022 for proximal anastomotic false aneurysm having benefited from an aorto-bi-iliac bypass (DACRON type prosthesis).

His usual treatment includes: rosuvastatin 20 mg/day, Kardégic® 75 mg/day, IMUREL, COLCHICINE, pantoprazole 20 mg/day and bisoprolol 1.25 mg/day.

On admission to the emergency room, the patient is hypotensive at 92/74 mmHg, without peripheral signs of shock, febrile at 38.5° with sinus tachycardia at 118/min. The pulse oxygen saturation (SpO₂) is 100% on room air.

The first assessment shows a hemoglobin (Hb) at 11 g/dL (reference*: 13.4 g/dL one year before), normal renal function. GB: 10600, CRP 13, Troponin, as well as brain natriuretic peptide (BNP) are normal.

Vascular filling with macromolecules is started, as well as treatment with proton pump inhibitor (PPI).

The esophagogastroduodenal endoscopy carried out up to the third duodenum, visualized) (Figure 1).

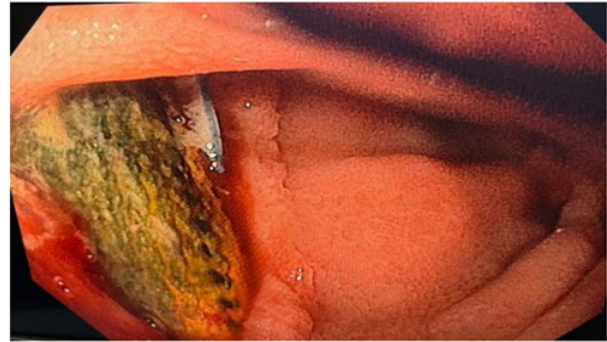


Figure 1: Endoscopic image shows an intraduodenal foreign body (D3) compatible with prosthetic material (aortic prosthesis which perforates the duodenum).

Secondarily, the patient will present a new episode of lower digestive hemorrhage, in the form of melena.

An abdominal CT scan, with intravenous injection of PDC is performed, showing a defect of the duodenal wall opposite the D3 portion of the duodenum with periprosthesis aero-liquid effusion with an image suggesting an intraduodenal foreign body (Figure 2).

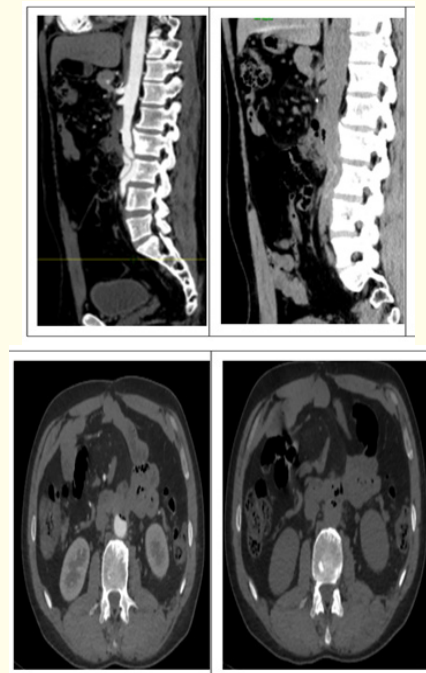

Figure 2: CT images showing periprosthesis aero-liquid effusions with an image suggesting an intra-duodenal foreign body.

The patient underwent emergency surgery which consisted of repairing the perforation of the duodenum with total excision of the aortobiliac prosthesis which was infected with a greenish appearance of the prosthesis (Figure 3).

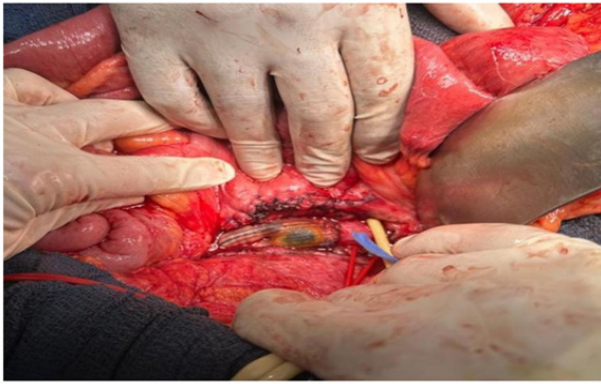


Figure 3: Intraoperative view of a transverse duodenal suture with greenish appearance of the prosthesis.

The surgical procedure is completed by:

- A gastro-jejunal anastomosis
- An aorto-bi-iliac bypass (Figure 4)
- Protection of the prosthesis by BOVINE PERICARDIAL PATCH (Figure 5)
- Performance of an additional protective epiplooplasty to protect the prosthesis and prevent recurrence of digestive erosion (Figure 6).

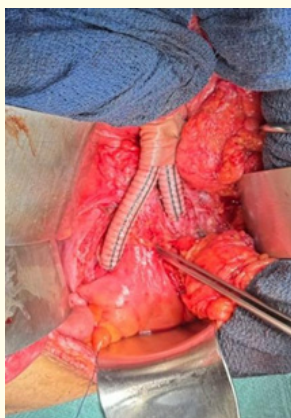


Figure 4: Perioperative view after vascular reconstruction by aorto-biliary bypass.

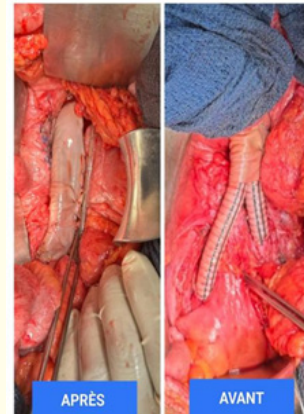


Figure 5: Perioperative view before and after protection of the prosthesis by BOVIN pericardial patch.

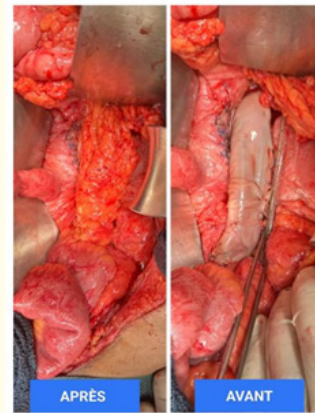


Figure 6: Intraoperative view before and after positioning of the omentumplasty.

The culture of the aortic prosthesis was negative, for which an anti-infectious treatment based on tazocillin was initiated for 6 weeks.

On the seventh postoperative day, the patient resumed his transit, declared discharge at D+10 postoperatively.

Discussion

The medical and surgical management of patients with IPV is complex. It depends on the mode of contamination of the prosthesis (contiguity, hematogenous), the incriminated germ (virulent or not), the location of the infected prosthesis (peripheral, abdominal

or thoracic) and the general condition of the patient (comorbidities). In any case, it is not easy to apply to all situations the dogma according to which all infected material must be removed [8].

Concerning probabilistic antibiotic therapy: The use of probabilistic anti-infective treatment is a multidisciplinary decision that takes into account the location of the prosthesis (intra- and/or extracavitary), the severity of the sepsis, the terrain and the expected time before surgery. In addition to being highly desirable from a prognostic point of view, surgical revision contributes to the diagnosis of the infection. Indeed, if the proportion of intraoperative samples with positive culture does not seem to be impacted by 48 hours of prior antibiotics, the risk of loss of microbiological information increases beyond that [10,16]. In practice, it is recommended to limit the use of probabilistic antibiotic therapy to only situations of suspected or proven IPV for which it does not seem reasonable to wait for the microbiological results of reliable samples: sepsis with severity criteria, septic shock, clinical and/or radiological signs suggesting a mechanical complication of infectious origin, such as an aneurysmal rupture or anastomotic detachment.

With regard to surgical indications and strategies: The aim of surgery is to eradicate the source of the infection as best as possible. It is also to allow the identification of the incriminated germ. Before deciding to remove the contaminated material, the different possibilities of vascular reconstruction after disassembly must be considered. For infections of prostheses vascularizing the limbs, the strategy is relatively clear. In situ or extraanatomical reconstruction can be performed using a venous autograft or an arterial homograft. In an emergency context, in the absence of available autografts or homografts, the choice of extraanatomical revascularization avoiding the septic focus using a standard vascular prosthesis is an alternative [17]. The other alternative is temporary in situ repair with a standard prosthesis after debridement of the infected tissues. Secondly, a more durable reconstruction with a graft less sensitive to infection and after implementation of antibiotic therapy will be carried out. The choice of conservative treatment is rarely retained [18]. In rare cases of infections of prostheses or aortic endoprostheses (< 1%), the situation is mainly assessed according to the general condition of the patient and the virulence of the germ. The decision is then medico-surgical. Conservative treatment may be retained in the case of low-virulence germs or when the patient is considered too fragile with a prosthesis that is difficult to access (thoracoabdominal aortic endoprostheses for example). However, it will be necessary to perform debridement of the periprosthetic abscess, exclusion of a fistula

(bronchial, esophageal, digestive), placement of a muscle flap or pedicled omentum intra-abdominally with possible drainage. The results are heterogeneous in the literature; in any case, lifelong suppressive antibiotic therapy will be necessary [19]. When the decision is made to remove all or part of the infected prosthesis, the choice of in situ vascular reconstruction will be preferred, because this type of reconstruction seems to be associated with better results than extra-anatomic reconstructions [20]. In the case of extra-anatomic aortic reconstruction, for example using an axillobifemoral bypass, the risk of infection and occlusion is high; in addition, there is a risk of aortic stump failure.

Regarding the choice of prosthesis: Polyester and ePTFE vascular prostheses have no defense against pathogenic germs. In any case, the prostheses are less effective against infection than arterial or venous autografts or homografts, even if the latter pose other problems, such as aneurysmal degeneration and the risk of occlusion. Several research avenues are currently being developed to propose prostheses that release anti-infectious agents (silver ions, triclosan) or antibiotics [21]. Their use in primary prevention raises the problem of resistance, and their effectiveness in secondary prevention has not been demonstrated [22].

Conclusion

Aortic prosthesis infections remain a rare but serious complication, with high morbidity and mortality, the diagnosis of prosthesis infection is raised in the face of the notion of a fever or digestive symptoms. Therapeutic management is medical-surgical, the therapeutic decision is multidisciplinary, depends on the mode of contamination of the prosthesis, the incriminated germ, the location of the infected prosthesis and the general condition of the patient.

Bibliography

1. Kieffer E., et al. "In-situ allograft replacement of infected infrarenal prosthetic grafts". *Journal of Vascular Surgery* 17 (1993): 349-356.
2. Lorentzen JE., et al. "Vascular graft infection : an analysis of 62 graft infection in 2411 consecutively implanted synthetic vascular grafts". *Surgery* 98 (1985): 81-86.
3. Calligaro KD and Veith FJ. "Diagnosis and management of infected prosthetic aortic grafts". *Surgery* 110 (1991): 805-813.

4. Hayes PD, et al. "In-situ replacement of infected aortic graft with rifampicin-bonded prosthesis : the Leicester experience (1992 to 1998)". *Journal of Vascular Surgery* 30 (1999): 92-98.
5. Mckeow PP and McDougall PP. "Diagnosis of arterial graft infection by indium-111 oxine white blood cell scans". *Circulation* 66.2 (1982): 1130-1134.
6. McDougall PP, et al. "Evaluation of 111In leukocyte whole body scanning". *AJR American Journal of Roentgenology* 133 (1979): 849-854.
7. Szilagyi DE, et al. "Infection in arterial reconstruction with synthetic grafts". *Annals of Surgery* 176 (1972): 321-333.
8. F Camou, et al. "Treatment of Prosthetic Vascular Graft Infections". © SRLF et Lavoisier SAS (2016).
9. L Canaud, et al. "AlricTraitement chirurgical des infections des prothèses aortiques". 11/01/17 [43-070].
10. Legout L, et al. "Risk factors for methicillin-resistant staphylococcal vascular graft infection in an 11-year cohort study". *Journal of Infectious* 64 (2012): 441-442.
11. Vogt PR, et al. "Cryopreserved arterial allografts in the treatment of major vascular infection: a comparison with conventional surgical techniques". *The Journal of Thoracic and Cardiovascular Surgery* 116 (1998): 965-972.
12. Fiorani P, et al. "Long-term follow-up after in situ graft replacement in patients with aortofemoral graft infections". *European Journal of Vascular and Endovascular Surgery* 14 (1997): 111-149.
13. Roy D and Grove DI. "Efficacy of long-term antibiotic suppressive therapy in proven or suspected infected abdominal aortic grafts". *Journal of Infectious* 40 (2000): 184-187.
14. Postier RG, et al. "Results of a multicenter, randomized, open-label efficacy and safety study of two doses of tigecycline for complicated skin and skin-structure infections in hospitalized patients". *Clinical Therapy* 26 (2004): 704-714.
15. Vogt PR, et al. "Technical details with the use of cryopreserved arterial allografts for aortic infection: influence on early and midterm mortality". *Journal of Vascular Surgery* 35 (2002): 80-86.
16. Revest M, et al. "Medical treatment of prosthetic vascular graft infections: review of the literature and proposals of a working group". *International Journal of Antimicrobial Agents* 46 (2015): 254-256.
17. Aukema TS and Legemate DA. "Gluteopopliteal bypass for a compromised groin". *Journal of Vascular Surgery* 49 (2009): 483-485.
18. Mertens RA, et al. "Surgical management of infrainguinal arterial prosthetic graft infections: review of a thirty-five-year experience". *Journal of Vascular Surgery* 21 (1995): 782-790.
19. Murphy EH, et al. "The management of endograft infections following endovascular thoracic and abdominal aneurysm repair". *Journal of Vascular Surgery* 58 (2013): 1179-1185.
20. Oderich GS, et al. "Evolution from axillofemoral to in situ prosthetic reconstruction for the treatment of aortic graft infections at a single center". *Journal of Vascular Surgery* 43 (2006): 1166-1174.
21. Jean-Baptiste E, et al. "Evaluation of the anti-infectious properties of polyester vascular prostheses functionalised with cyclodextrin". *Journal of Infectious* 68 (2014): 116-124.
22. Topel I, et al. "Microbial spectrum and primary resistance to rifampicin in infectious complications in vascular surgery: limits to the use of rifampicin-bonded prosthetic grafts". *Angiology* 61 (2010): 423-426.