

## Hypertrophic Pyloric Stenosis in 10 Year Old Child: A Rare Presentation

Surakshith A Shetty<sup>1\*</sup>, H Ramesh<sup>2</sup> and K A Chaya<sup>3</sup>

<sup>1</sup>Resident, Department of Pediatric, Bapuji Child Health Institute, JJMMC, Davangere, Karnataka, India

<sup>2</sup>Professor, Department of Pediatric, Bapuji Child Health Institute, JJMMC, Davangere, Karnataka, India

<sup>3</sup>Assistant Professor, Department of Pediatric, Bapuji Child Health Institute, JJMMC, Davangere, Karnataka, India

\*Corresponding Author: Surakshith A Shetty, Resident, Department of Pediatric, Bapuji Child Health Institute, JJMMC, Davangere, Karnataka, India.

Received: January 28, 2109; Published: February 18, 2019

### Abstract

Infantile hypertrophic pyloric stenosis is disease usually presents with non-bilious vomiting at third to fourth weeks of life. Two most common complication is metabolic alkalosis and paradoxical aciduria. Diagnosis is usually confirmed by ultrasound. We report an unusual case of 10 year old boy who presented with recurrent, long standing episodes of non-bilious vomiting.

**Keywords:** Hypertrophic Pyloric Stenosis; Non-Bilious Vomiting; Ultrasound

### Introduction

Hypertrophic pyloric stenosis is a common condition of infancy. Gastric outlet obstruction include idiopathic hypertrophic pyloric stenosis, gastric antral webs, gastric volvulus, gastric polyp, crohn's disease, bezoars, ingestion of caustic substances, malrotation, mid gut volvulus [1]. Pyloric stenosis presenting beyond infancy is markedly uncommon, and while cases of later-onset pyloric stenosis have been reported, the etiology is poorly understood [2]. we report this case of pyloric stenosis in a 10-year-old male child because of its late onset.

### Case Report

A 10-year-old boy with history of persistent vomiting for 3 months and poor weight gain. The patient's medical evaluation began 2 month back when he presented with persistent vomiting, diagnosed as acute gastritis. Patient continued to have persistent weight loss and vomiting hence was readmitted to hospital for further evaluation. On clinical examination child had olive shaped mass (Figure 1) located above and to the right of the umbilicus in the mid epigastrium beneath the liver's edge. The mass is easiest palpated after an episode of vomiting. After eating/drinking, there is a visible gastric peristaltic wave that progresses across the abdomen. The rest of systemic examination did not show any abnormality.

On investigation his hemogram and chest x ray were normal, but serum electrolytes were abnormal (hyponatremia with hypokalemia). HIV serology, PPD test and gastric aspirate for tuberculosis were negative.

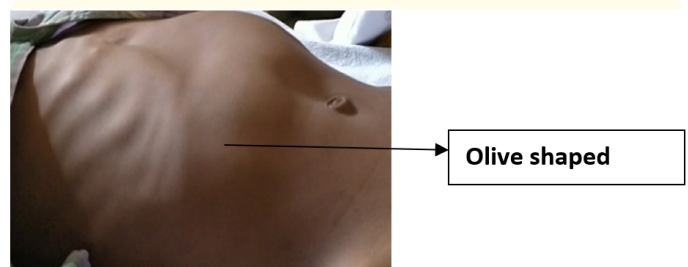


Figure 1: Olive shaped mass.

Subsequent ultrasound (Figure 2) done showed – stomach gross stasis, pylorus hypertrophy length-21 mm, diameter-18mm, thickness-7.3mm. Barium follow through (Figure 3) was done showing grossly dilated stomach having residual fluid with in, gross delay in emptying, antral and pyloric canal is narrow and failed to dilate.

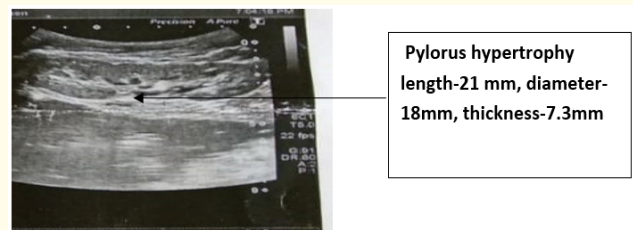
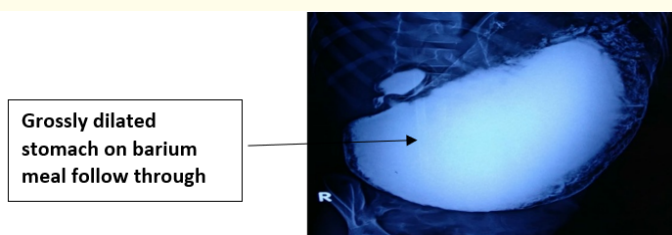
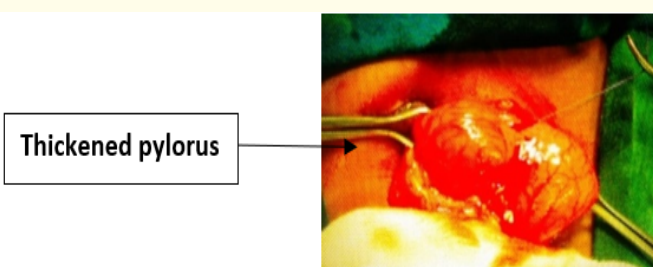


Figure 2: Ultrasound of pylorus.



**Figure 3:** Grossly dilated stomach on barium meal follow through.

He continued to have vomiting after eating solid foods as well as poor weight gain. At this point, pediatric surgery opinion was given and elected to operatively explore the child. Intraoperative finding found markedly thickened pylorus (Figure 4) as well as a boggy, distended stomach. Pyloroplasty was done. Post operatively he was started on oral liquid diet initially followed by solid diet which he tolerated well. Three months after surgery, the patient had gained nearly 3 kg and was tolerating regular diet well.



**Figure 4:** Thickened pylorus.

## Discussion

The incidence of hypertrophic pyloric stenosis is 2.4 per 1000 live births in Caucasians, 1.8 in Hispanics, 0.7 in Blacks, and 0.6 in Asians [3,4]. Diagnosis of IHPS is based mostly on the history and physical exam of the patient. Patient's history includes recurrent episodes of projectile vomits usually between the 4th and 6th week after birth. On physical assessment peristaltic waves are usually visible in the epigastrium and a characteristic "olive" shaped mass is palpable. The radiological study of choice to confirm the diagnosis is abdominal ultrasound. Also gastrointestinal contrast study and CT scan with contrast can be indicative. The most current ultrasonographic criteria for HPS include pyloric channel length 15 mm, pyloric muscle diameter 13 mm and pyloric muscle wall thickness 3 mm [5,6]. Definitive treatment is corrective sur-

gery. The Ramsted pyloromyotomy, performed through a right upper quadrant transverse incision, currently is the procedure of choice. Yet, new reports suggest laparoscopic pyloromyotomy as a safer alternative [7,8].

As Other causes of acquired hypertrophic pyloric stenosis were excluded this could be a case of Jodhpur disease recently renamed as "primary acquired gastric outlet obstruction of infancy and childhood" [9].

## Conclusion

Hypertrophic pyloric stenosis is a really rare disease entity in children more than 6 to 8 months. We have to be alert in cases with history of repeated vomiting and failure to gain weight.

## Bibliography

1. Subramaniam S and Bechtel K. "Pediatric pyloric stenosis differential diagnosis". *Emergency Medicine, Medscape* (2017).
2. Selzer Don., *et al.* "Hypertrophic pyloric stenosis in an adolescent". *Journal of Laparoendoscopic and Advanced Surgical Techniques* 19.3 (2009): 451-452.
3. Ziegler MM., *et al.* *Operative pediatric surgery* 1 (2005): 583-587.
4. Leong MM., *et al.* "Epidemiological Features of Infantile Hypertrophic Pyloric Stenosis in Taiwanese Children: A Nation-Wide Analysis of Cases during 1997-2007". *PloS One* 6.5 (2011): e19404.
5. Sharma KK., *et al.* "Gastric outlet obstruction in children: an overview with report of "Jodhpur disease" and Sharma's classification". *Journal of Pediatric Surgery* 43.10 (2008): 1891-1897.
6. Said M., *et al.* "Ultrasound Measurements in Hypertrophic Pyloric Stenosis: Don't Let the Numbers Fool You". *The Permanente Journal* 16.3 (2012): 25-27.
7. Costanzo CM., *et al.* "Postoperative outcomes of open versus laparoscopic pyloromyotomy for hypertrophic pyloric stenosis". *Journal of Surgical Research* 224 (2018): 240-244.
8. Kelay A and Hall NJ. "Perioperative Complications of Surgery for Hypertrophic Pyloric Stenosis". *European Journal of Pediatric Surgery* 28.2 (2018): 171-175.
9. Mukul Aggarwal., *et al.* "Jodhpur disease revisited: a rare cause of severe protein energy malnutrition". *Annals of Gastroenterology* 25.3 (2012): 262-264.

## Volume 2 Issue 3 March 2019

© All rights are reserved by Surakshith A Shetty., *et al.*