



Lateral Minimally Invasive Plate Osteosynthesis of Proximal Metadiaphyseal Humeral Fractures: A Case Series and Review of the Literature

Tânia A Veigas*, Alexandre Castro, Raquel Cunha, João Alves, António Madureira, Eduardo Ferreira, Herculano Nascimento, Manuel Godinho, António Miranda, Tiago P Torres

Orthopedics and Traumatology Department of Centro Hospitalar Entre o Douro e Vouga, Portugal

*Corresponding Author: Tânia A Veigas, Orthopedics and Traumatology Department of Centro Hospitalar Entre o Douro e Vouga, Portugal.

DOI: 10.31080/ASOR.2024.07.0933

Received: February 20, 2024

Published: March 10, 2024

© All rights are reserved by Tânia A Veigas, et al.

Abstract

Humeral shaft fractures are common, but proximal metadiaphyseal fractures are unusual and represent challenging injuries. Their treatment is still controversial and debatable. Lateral minimally invasive osteosynthesis (MIPO) represents an alternative treatment for those fractures, but there is still a lack of studies describing this technique. We retrospectively reviewed six patients with proximal metadiaphyseal humeral fractures treated with lateral MIPO. All the patients reached consolidation. We had one case of post-operative radial neuropraxia that entirely resolved with time, and there was no other complication. We reviewed and summarized the available literature, and our outcomes were similar to those described. The mean shoulder ROM was $143^{\circ} \pm 12,4^{\circ}$ of abduction; $145^{\circ} \pm 9,1^{\circ}$ of forward elevation; $33,8^{\circ} \pm 4,8^{\circ}$ of external rotation; most patients reached L1 level with internal rotation, with no statistically significant difference between the affected and non-affected arm. The mean Constant score was $88 \pm 5,4$; the mean Q-DASH score was $8 \pm 1,3$; and the mean UCLA score was $28,8 \pm 2,6^{\circ}$. The lateral MIPO approach permits a good shoulder function and a high union rate. Radial neuropraxia is the most common complication described in the literature and usually entirely resolves with time. Orthopaedic and trauma surgeons dedicated to shoulder injuries should know different approaches and fixation methods. MIPO should also be in their arsenal, with the lateral approach advantageous in proximal metadiaphyseal fractures and a reproductive technique.

Keywords: Minimally Invasive Surgery; Lateral Approach; Humeral Shaft Fractures; Proximal Metadiaphyseal Humeral Fractures

Abbreviations

Abd: Abduction; AO/ASIF: Association for Osteosynthesis/Association for the Study of Internal Fixation; BMI: Bone Mass Index; Class: Classification; ER: External Rotation; FA: Forward Elevation; F: Female; Fig: Figure; FU: Follow-up; IMN: Intermedullary Nail; IR: Internal Rotation; M: Male MIPO: Lateral Minimally Invasive Osteosynthesis; NA: Not Applied; Num: Number; L:Left; Retro: Retrospective; R: Right ROM: Range of Motion

Introduction

Humeral shaft fractures are common injuries that extend from the superior border of the pectoralis major insertion to the supracondylar ridge distally and are mostly treated non-surgically [19]. However, conservative treatment may not be appropriate

depending on the fracture location and pattern, the bone quality and the body habitus. The proximal metadiaphyseal humeral area is a challenging fracture location, and the conventional AO classification does not entirely characterise it [13,22]. They are referred to as intermuscular fractures with a typical pattern of displacement and have higher nonunion rates with conservative treatment (Figure 1) [7,22]. These injuries should not be treated as either purely metaphyseal or diaphyseal. Their prevalence is increasing with the ageing of the population, and some consider them fragility fractures [15]. They are compared to the subtrochanteric region, where intramedullary nailing (IMN) is considered the gold-standard. However, the best osteosynthesis in these injuries is still a matter of debate, with most opinions diverging between either IMN or minimally invasive plate osteosynthesis (MIPO) [18].

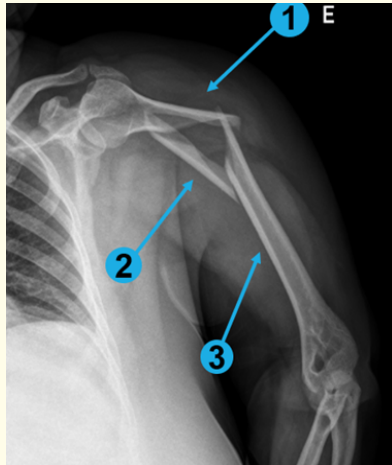


Figure 1: An example of an intermuscular fracture: 1) the proximal fragment is abducted by the deltoid; 2) the middle one is displaced medially by pectoralis major, teres major and latissimus dorsi; 3) the distal fragment is displaced proximally and medially by the biceps and triceps.

Reports of MIPO techniques in humeral shaft fractures have appeared since the first decade of the 21st century [4,21]. The theoretical advantages are less soft-tissue damage, preservation of the fracture hematoma and remaining osseous blood supply, avoidance of shoulder pain and secondary bone healing [23]. There has been scepticism about using MIPO techniques due to the anatomy and risk of damage to neurovascular structures, but safer techniques were developed. Recent literature reports low nonunion and complication rates, with some authors preferring MIPO [18,23]. However, these outcomes are difficult to analyse since studies have few patients, and combine different approaches, implants and fracture locations. There are different MIPO techniques. The most commonly described is an anterior plate with a proximal incision in the deltopectoral space and a distal split of the brachialis in the midline [3,4]. Another technique uses helical implants with either a deltopectoral or transdeltoid approach proximally and a split of the brachialis distally [8]. A less reported technique is the lateral approach that seems advantageous in treating proximal metadiaphyseal fractures [1,5,17].

This study aims to evaluate retrospectively our outcomes using the lateral MIPO approach in treating proximal metadiaphyseal fractures of the humerus using a long anatomical proximal locking plate. We also reviewed the available literature.

Materials and Methods

Patients and methods

We retrospectively reviewed all patients with a proximal third humeral shaft fracture treated with a lateral MIPO technique in our institution between 2019 and 2022. The patients were proposed for surgery if fracture reduction was unacceptable. The option for lateral MIPO technique in these patients was due to expected bad bone quality, obesity, the location and the availability of the hardware. Two different surgeons with experience in shoulder trauma performed the technique. We classified the fractures according to the Association for Osteosynthesis/Association for the Study of Internal Fixation (AO/ASIF) classification system. The definition of fracture union was callus formation on at least 3 of the 4 cortices on AP and lateral radiographs. Non-union was considered if both surgeons agreed it had no probability of healing without further intervention. A different doctor than those performing the surgery evaluated all the patients. Constant score, Quick-Dash and UCLA and range of motion were obtained. A Wilcoxon test was employed to assess whether a difference exists between the range of motion of the affected and non-affected limb. The Ethical Committee approved this study. Patient consent was obtained.

We reviewed all the available literature in English using Pubmed. The entire search terms used were ("humerus"[MeSH Terms] OR humeral[Title]) AND (Shaft[Title/Abstract] OR diaphysis[Title/Abstract]) AND (Minimally Invasive Surgical Procedure [Title/Abstract]). Abstracts and full texts were reviewed, and all the articles with approaches other than lateral MIPO were discarded. Review articles were cross-referenced for further relevant references. A further online search using the Google search engine was performed to identify omitted studies.

Operating technique

General anaesthesia and peripheral nerve block are performed. A beach chair position is adopted. The affected extremity is sterilely prepped and positioned on arm support. An anterolateral deltoid-split approach is performed by extending 5 cm distally from the acromion's tip, respecting the axillary nerve's safety interval without formally exposing it. Next, the raphe separating the anterior and middle heads of the deltoid is identified and sharply divided along with the subdeltoid bursa. A 5 to 8 cm incision in the lateral distal third of the arm is performed. The radial nerve is consistently identified as it emerges from the lateral intermuscular septum in the interval between the brachialis's vertical fibers and the brachioradialis's oblique ones. It is then gently released and

protected laterally, and the space between the two muscles is developed. Next, an antegrade submuscular extraperiosteal tunnel is created along the humeral shaft with a small raspatory or with the plate. The tunnel passes through the middle third of the deltoid v, leaving the anterior and posterior insertions intact. This is the most challenging step. In the distal approach, the radial nerve is constantly monitored and protected. The assistant helps by performing gentle traction and stabilising the arm in slight abduction. The plate is passed through the submuscular tunnel, and its constant contact with the bone is confirmed on the image intensifier. The surgeon uses the plate, indirect manoeuvres and assistant devices in the proximal fragment to reduce it. The fracture reduction

and plate height are confirmed with fluoroscopy. The plate is firstly fixed proximally and then distally with k wires and afterwards with screws creating a bridge construct with at least three screws on each side. With the shoulder and arm in different rotations and elevations, the fracture stabilisation and screw length are confirmed with fluoroscopy (Figure 2). No drain is used. After surgery, the arm is immobilised in a sling for the first three weeks, only for comfort, and the patient may mobilise the shoulder and arm according to tolerance, but load is prohibited. Self-passive mobilisation exercises are explained and incentivised. The hospitalisation time is usually 2 days. In the third week, the sling is abandoned, and the patient is sent to rehabilitation.

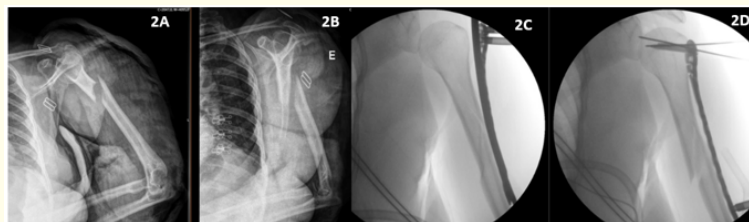


Figure 2: Unacceptable fracture reduction. Lateral plating and indirect manoeuvres achieved an acceptable reduction.

Results

We treated a total of 6 patients, 5 female and 1 male, with a mean age of 66 years (range 53 to 72 years) and a mean bone mass index (BMI) of 30 (range 27 to 39). The mean follow-up was 12 months, ranging from 3 to 20 months. All the injuries were due to accidental falls, except one that fell from a height of 4 meters (case 5). All were closed fractures without additional fractures associated. The motives for surgery were an unacceptable reduction of an acute fracture in 5 patients and one failed conservative treatment in a patient who initially did not want surgery. She went to the operating room 4 weeks later (case 1). According to the AO classification, there were 1 type A, 1 type B and 4 type C fractures. The main fracture line was located in the proximal third of the shaft (cases 3 and 4), extending proximally to the humeral surgical neck in case 5 and extending to the middle third of the shaft in the remaining. Tables 1 and 2 summarize the group characteristics and results. None of the patients had radial nerve paralysis at presentation. A long proximal lateral humerus locking plate was used (AxSOS Stryker®). The group had no non-union, infection or impingement (Figure 3). No patient had an axillary nerve lesion, but 1 patient developed a postoperative radial nerve paralysis that resolved completely after three months. Two patients were lost in follow-up because they passed away for other reasons. At the final follow-up, the mean Constant score was $88 \pm 5,4$; the mean Q-DASH score

was $8 \pm 1,3$; and the mean UCLA score was $28,8 \pm 2,6^{\circ}$. In regards to the range of motion of the affected limb, the mean abduction (Abd) was $143^{\circ} \pm 12,4^{\circ}$; forward elevation (FA) was $145^{\circ} \pm 9,1^{\circ}$, and external rotation (ER) was $33,8^{\circ} \pm 4,8^{\circ}$. Most had an internal rotation (IR) reaching the level of L1. There was no statistically significant difference between the range of motion of the affected limb and the non-affected limb (Abd: $Z = -1,604$, $p = 0,109$; FA: $Z = -1,342$, $p = 0,180$; ER: $Z = -1,890$, $p = 0,59$).

We reviewed the available literature, and 9 studies were retrieved. The study by Benninger et al. (2017) was excluded because it was only in cadavers, and the objective was to evaluate the damage to the humeral insertion of the deltoid muscle during the creation of the submuscular tunnel. The study of Ortega-Yago et al. compared the treatment of metadiaphyseal fractures with MIPO and IMN. However, only 3 of 29 patients had a lateral distal approach, so results were also not included. The results of the remaining 7 studies are summarized in tables 3 to 5 [1,6,10,11,17,20,21].

Discussion

Treatment of humeral shaft fractures is still a highly discussed issue. Proximal metadyaphyseal fractures are challenging since they are uncommon, have an intermuscular location and are usu-

Case	Sex/Age	BMI	Side	Indications	AO Class	Complications
1	F/65	27	R	Failed conservative treatment	12B2	Deceased during FU
2	F/53	31	L	Acute fracture	12A1	
3	F/68	39	L	Acute fracture	12 C1 extension to middle shaft	
4	F/69	30	L	Acute fracture	12 C1 extension to middle shaft	Pos-op radial neuropraxy with total resolution
5	M/72	27	R	Acute fracture	12C3 extension to humeral surgical neck	Deceased during FU
6	F/66	28	L	Acute fracture	12C2	

Table 1: Patient characteristics.

Abbreviations: BMI: Bone Mass index; Class: Classification; F: Female; FU: Follow-up; L:Left; M: Male; R: Right.

Case	Follow-up	Union	Mobilities affected shoulder	Mobilities non-affected shoulder	Constant	Q-DASH	UCLA
1	3 M	Yes	NA	NA	NA	NA	NA
2	18 M	Yes	Abd: 152°; FA:150°; ER: 35°; IR: L1	Abd:152°; FA:150°; ER: 40°; R:T11	88	9.1	31
3	20 M	Yes	Abd:145°; FA:140°ER: 40°; IR: L2	Abd:155°; FA:150° ER:42°; IR:T12	82	6.8	26
4	12 M	Yes	Abd:125°; FA:135°ER:30°; IR:L3	Abd:130°; FA: 140°ER:35°; IR:L1	95	6.8	31
5	4 M	Yes	NA	NA	NA	NA	NA
6	16 M	Yes	Abd:150°; FA:155°ER:30°; IR:L1	Abd:152°; FA: 155°ER:35°; IR:T11	87	9.1	27

Table 2: Patient outcomes.

Abbreviations: Abd: abduction ; ER: External rotation; FA: Forward elevation IR: Internal Rotation; NA: not applied.

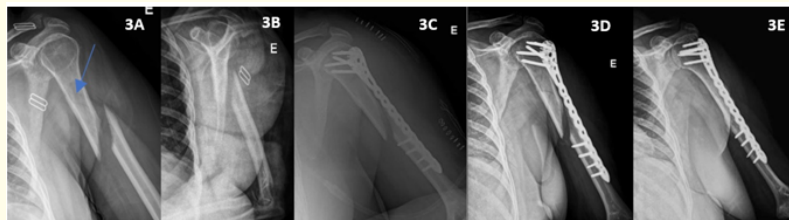


Figure 3: Non-acceptable fracture reduction. The blue arrow shows an undisplaced secondary line of fracture that extends almost to the surgical neck. The third image is the pos-operative x-ray and the fourth at 1 month of follow-up. The final x-ray is 4 months after surgery. Consolidation was obtained.

Authors	Study	Location	Patients/Gender	Mean Age	AO Class
Ji., <i>et al.</i> 2009 [11]	NR	NR	n = 22 (23 fractures)/(NR)	NR	NA
Spagnolo., <i>et al.</i> 2009 [21]	NR	Humeral shaft	n = 16/6♀ 10♂	54	n = 2 12A2+11; n = 4 12B1; n = 2 12B2; n = 3 12B3; n = 5 12C1
Rancan., <i>et al.</i> 2010 [17]	Retro	Meta-diaphyseal	n = 29/18♀ 11♂	77	n = 3 A011; n = 6 12A1; n = 1 12A2; n = 4 12A3; n = 3 12B1; n = 2 12B3; n = 6 12C1; n = 4 12C3
Aksu., <i>et al.</i> 2012 [1]	Retro	1 proximal; 1 shaft; 7 proximal shaft	n = 9/(NR)	75	n = 2 11A2; n = 2 12A1; n = 1 12A2; n = 4 12C1
Seyfettinoğlu., <i>et al.</i> 2018 [20]	Retro	diaphyseal with proximal extension	N = 21/18♀ 3♂	74	n = 17 12C1; n = 4 12C3
Jeong., <i>et al.</i> 2019 [10]	NR	shaft fractures ± distal or proximal extension	N = 35/28♀ 15♂ (NLCP: n = 18 LPP n = 17)	62	n = 10 A1; n = 5 A2; n = 8 B1; n = 3 B2; n = 1 B3; n = 7 C1; n = 1 C3
Chamseddine., <i>et al.</i> 2020 [6]	Retro	NR	n = 21/13♀ 8♂	56	n = 4 A1; n = 4 A3; n = 7 B2; n = 1 B3; n = 2 C2; n = 3 C3

Table 3: Review of the available literature on the lateral MIPO approach – Part 1.

Abbreviations: Num: number NR Not referred; Retro: Retrospective.

Study	FU	Mean Mobilities of shoulder	Constant	Q-DASH	UCLA
Ji., <i>et al.</i> [11]	72.2 W	NA	NA	NA	NA
Spagnolo., <i>et al.</i> [21]	7 M	Abd: 90°; FA: 170°	NA	NA	34; excellent: 62.5%; good: 37.5%
Rancan., <i>et al.</i> [17]	1 Y	NR	NA	NA	NA
Aksu., <i>et al.</i> [1]	1 Y	NR	86.8	NA	NA
Seyfettinog˘lu., <i>et al.</i> [20]	1 year	NR	84	21.9 ± 13	NA
Jeong., <i>et al.</i> [10]	16 M	NLCP: FA 154 ± 18; Abd: 155 ± 20; ER: 55 ± 20; IR: T10 LCP: FA: 143 ± 16; Abd: 140 ± 14; ER: 34 ± 11; IR: T12	NA	NA	NLCP: 27.4 ± 6.9 LPP group: 29.8 ± 3.3
Chamseddine., <i>et al.</i> [6]	1 year	NR	84	5	NA

Table 4: Review of the available literature on the lateral MIPO approach – Part 2.

Abbreviations: Abd: Abduction; ER: External rotation; FA: Forward flexion; FU: follow-up; IR: Internal rotation; M = months; NR Not referred.

Study	Non-union	Infection	Nerve Lesion	Other complications
Ji., <i>et al.</i> [11]	NR	NR	0	NR
Spagnolo., <i>et al.</i> [21]	0	0	0	
Rancan., <i>et al.</i> [17]	0	NR	0	NR
Aksu., <i>et al.</i> [1]	0	0	0	0
Seyfettinog˘lu., <i>et al.</i> [20]	0	0	N = 2 post op radial neuropraxis	2 impingement
Jeong., <i>et al.</i> [10]	2	0	0	0
Chamseddine., <i>et al.</i> [6]	1	NR	N = 2 pos op radial neuropraxis	Early shoulder-hand syndrome with reflex sympathetic dystrophy

Table 5: Review of the available literature on the lateral MIPO approach – Part 3.

ally unstable. In the study by Maresca *et al.* on multifocal humerus fractures, in 717 humeral fractures treated surgically, only 4.8% were proximal humeral shaft fractures. Among these, most had an undisplaced fracture of the proximal metaphysis with a displaced shaft fracture (57.1%) or were multifragmentary fractures affecting the proximal humerus and extending to the shaft (34,2%). Stedfeld *et al.* also agreed with the complexity of these lesions and proposed them as individual entities. In their study with 50 proximal third shaft fractures, the majority (76%) had an extension to the humeral head mainly undisplaced, almost all had a spiral morphology, and only 4% had a stable pattern. IMN or plates can be used, but the implant should be long and angular stable to provide enough torsional and bending stiffness to the fixation [22]. That would imply an extensive approach in the case of open reduction and internal fixation with a plate, with a higher risk of infection, so the debate has been between IMN and MIPO [9]. The advantages of antegrade IMN are a load-sharing implant and small dissection. The main disadvantages are iatrogenic injury of the rotator cuff, considered responsible for suboptimal clinical outcomes, the dif-

ficulty in the reduction and a higher non-union rate [25]. Maresca *et al.* proposed as contraindications to IMN a double displacement of the fractures because reduction is more complex and in comminuted fractures because of the risk of malreduction and inadequate stability. MIPO technique has the advantage of being minimally invasive as IMN and reduces operating time compared to ORIF. It also presents a high union and low complication rates. As in IMN, the disadvantage is the difficulty in fracture reduction with the concern for malunion [2,23]. There are studies comparing the two methods in proximal and middle third shaft fractures, with some favouring IMN, others MIPO and others with no differences [9,14,16,24].

Regarding the MIPO techniques, the anterior approach with a straight plate is more appropriate for middle and distal shaft fractures due to the plate location in the humerus. Therefore, a lateral implant seems more appropriate in proximal third shaft fractures. It provides a mechanical advantage in reducing the fracture. It also allows a more robust construction with more screws in the proximal fragment, which is especially important in proximal extension

to the humeral head and osteoporotic bone cases [13]. Due to these advantages, helical plates or lateral implants are good alternatives in proximal metadiaphyseal fractures. However, in many hospitals, helical implants are not readily available, which would imply pre-contouring plates. The lateral plating method uses an implant available in most hospitals, and the plate itself seems more helpful in the anatomic reduction as it crosses the deltoid insertion. A cadaveric study demonstrated that most anterior and posterior insertions were not involved, and their clinical significance on muscle function remains unclear [5]. Another advantage of the lateral approach is the exploration of the radial nerve, which may be necessary in some cases [12,17,21]. Only a few studies report the results of the lateral MIPO technique, but most describe good outcomes. The main concerns with the approach are the axillary nerve proximally and the radial nerve distally. Since the axillary nerve course is predictable, exploration is not mandatory, and no study has reported any injuries. Surgical exploration of the ra-

dial nerve should be performed always. In the current literature, in a total of 133 patients distributed in the 7 studies, 3% had a radial neuropraxia that entirely resolved with only observation, 2.3% had non-unions, 1.5% had implant impingement, and 0.8% had a shoulder-hand syndrome with reflex sympathetic dystrophy. Regarding shoulder function, only 2 studies present the shoulder ROM, and they apply different functional scores. In our study, we had one case of radial neuropraxia and no non-union or other complications. The patient had good shoulder ROM and functional scores (Figure 4). The lateral MIPO technique seems particularly useful in proximal metadiaphyseal fractures. Even though many studies also agree with that use, most mix different fracture location, which precludes conclusions. All the patients described in this study have that fracture location. Even though not addressed in the literature, all of our individuals were overweight or obese, and this method may be helpful for this type of patient. No studies, to our knowledge, exist in the literature.

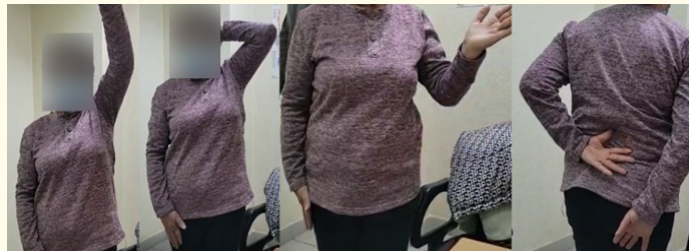

Figure 4: The image depicts a good function at 16 months post-op.

Conclusion

Albeit the small number of patients obtained, the results were similar to those described in the literature. This method appears to allow a good shoulder function and a high union rate. Radial neuropraxia seems the most common complication, even though uncommon. Orthopaedic and trauma surgeons dedicated to shoulder injuries should know different approaches and fixation methods. MIPO should also be in their arsenal, with the lateral approach advantageous in proximal metadiaphyseal fractures and a reproductive technique.

Conflict of Interest

No financial interest or any conflict of interest exists.

Bibliography

1. Aksu Neslihan., *et al.* "Minimally Invasive Plate Osteosynthesis (MIPO) in Diaphyseal Humerus and Proximal Humerus Fractures". 3 (2012): 154-160.
2. An Zhiqian., *et al.* "Plating Osteosynthesis of Mid-Distal Humeral Shaft Fractures: Minimally Invasive versus Conventional Open Reduction Technique". *International Orthopaedics* 34.1 (2010): 131-135.
3. Apivatthakakul T., *et al.* "Danger Zone for Locking Screw Placement in Minimally Invasive Plate Osteosynthesis (MIPO) of Humeral Shaft Fractures: A Cadaveric Study". *Injury* 41.2 (2010): 169-172.
4. Apivatthakakul T., *et al.* "Minimally Invasive Plate Osteosynthesis (MIPO) of the Humeral Shaft Fracture: Is It Possible? A Cadaveric Study and Preliminary Report". *Injury* 36.4 (2005): 530-538.
5. Benninger Emanuel and Christoph Meier. "Minimally Invasive Lateral Plate Placement for Metadiaphyseal Fractures of the Humerus and Its Implications for the Distal Deltoid Insertion- It Is Not Only about the Radial Nerve. A Cadaveric Study". *Injury* (2017): 1-6.

6. Chamseddine Ali Hassan., *et al.* "Minimally Invasive Percutaneous Plate Osteosynthesis for Treatment of Proximal Humeral Shaft Fractures". *International Orthopaedics* 45.1 (2021): 253-263.
7. Francisco Baixauli Castellá., *et al.* "Nonunion of the Humeral Shaft: Long Lateral Butterfly Fracture - a Nonunion Predictive Pattern?" *Clinical Orthopaedics and Related Research* (2004).
8. García-virto Virginia., *et al.* "MIPO Helical Pre-Contoured Plates in Diaphyseal Humeral Fractures with Proximal Extension". *Surgical Technique and Results R.* (2021).
9. Hohmann Erik., *et al.* "Minimally Invasive Plating versus Either Open Reduction and Plate Fixation or Intramedullary Nailing of Humeral Shaft Fractures: A Systematic Review and Meta-Analysis of Randomized Controlled Trials". *Journal of Shoulder and Elbow Surgery* 25.10 (2016): 1634-1642.
10. Jeong Jae-jung., *et al.* "Narrow Locking Compression Plate vs Long Philos Plate for Minimally Invasive Plate Osteosynthesis of Spiral Humerus Shaft Fractures". *BMC Musculoskeletal Disorders* (2019): 1-8.
11. Ji Fang., *et al.* "Minimally Invasive Percutaneous Plate Osteosynthesis (MIPPO) Technique Applied in the Treatment of Humeral Shaft Distal Fractures through a Lateral Approach". *International Orthopaedics* 33.2 (2009): 543-547.
12. Lau T W., *et al.* "Minimally Invasive Plate Osteosynthesis in the Treatment of Proximal Humeral Fracture". (2007): 657-664.
13. Maresca A., *et al.* "Multifocal Humeral Fractures". *Injury* 45.2 (2014): 444-447.
14. Oh C W., *et al.* "Plating of Humeral Shaft Fractures: Comparison of Standard Conventional Plating versus Minimally Invasive Plating". *Orthopaedics and Traumatology: Surgery and Research* 98.1 (2012): 54-60.
15. Oliver W M., *et al.* "Fractures of the Proximal- And Middle- Thirds of the Humeral Shaft Should Be Considered as Fragility Fractures An EpidemiologicAl Study of 900 Consecutive Injuries". *Bone and Joint Journal* 102-B.11 (2020): 1475-1483.
16. Ortega-Yago A., *et al.* "Treating Multifocal Humerus Fractures: A Comparison between the Mipo Technique and Intramedullary Nailing". *Injury* 53.10 (2022): 3332-3338.
17. Rancan Mario., *et al.* "Minimal Invasive Long PHILOS 1 -Plate Osteosynthesis in Metadiaphyseal Fractures of the Proximal Humerus". *Injury* 41.12 (2010): 1277-1283.
18. Saracco Michela., *et al.* "Which surgical treatment is preferable in humeral diaphyseal fractures ? a systematic review". 3 (2022): 1-11.
19. Sarmiento A., *et al.* "Functional Bracing for the Treatment of Fractures of the Humeral Diaphysis". *Journal of Bone and Joint Surgery* 82.4 (2000): 478-486.
20. Seyfettinoğlu Firat., *et al.* "Management of AO Type 12C Humerus Proximal Metadiaphyseal Fractures with Minimally Invasive Plate Osteosynthesis in Geriatric Patients". *Clinical Interventions in Aging* 13 (2018): 1003-1010.
21. Spagnolo Rosario., *et al.* "Minimally Invasive Plating Osteosynthesis Technique Applied to Humeral Shaft Fractures: The Lateral Approach". *European Journal of Orthopaedic Surgery and Traumatology* 20.3 (2010): 205-210.
22. Stedtfeld H W and R Biber. "Proximal Third Humeral Shaft Fractures - A Fracture Entity Not Fully Characterized by Conventional AO Classification". *Injury* 45 (2014): S54-59.
23. Tetsworth Kevin., *et al.* "Minimally Invasive Plate Osteosynthesis of Humeral Shaft Fractures". *Journal of the American Academy of Orthopaedic Surgeons* 26.18 (2018): 652-661.
24. van de Wall Bryan J M., *et al.* "MIPO versus Nailing for Humeral Shaft Fractures: A Meta-Analysis and Systematic Review of Randomised Clinical Trials and Observational Studies". *European Journal of Trauma and Emergency Surgery* 48.1 (2022): 47-59.
25. Walker Matt., *et al.* "Humeral Shaft Fractures : A Review". *Journal of Shoulder and Elbow Surgery* 20.5 (2011): 833-844.