



Lipoma; A Common Benign Neoplasm

Seyed Amirhossein Dormiani Tabatabaei*

Isfahan University of Medical Sciences isfahan, Iran

***Corresponding Author:** Seyed Amirhossein Dormiani Tabatabaei, Isfahan University of Medical Sciences isfahan, Iran.

Received: September 05, 2023

Published: October 23, 2023

© All rights are reserved by **Seyed Amirhossein Dormiani Tabatabaei**.

Abstract

Objective: In this essay, the manifestations, possible etiologies, diagnostic approaches, treatment methods and complications of lipomas are reviewed.

Methods: A thorough review of the literature is conducted, a series of 12 patients are outlined and briefly examined.

Results: Lipomas may present as asymptomatic tumors or produce distressing signs and symptoms such as pain, swelling and overgrowth. Some lipomas may be identified by physical examination alone. However, magnetic resonance imaging (MRI) is the conclusive method of evaluation especially in deeper lesions.

Conclusions: In the absence of indications or cosmetic concerns, observation stays the standard of care. When pain, itching, compression symptoms or disfigurement impress the patient, surgical removal and pathology assessment are typically recommended. Malignant transformation rarely occurs.

Keywords: Neoplasms; Lipoma; Pathology

Introduction

Lipomas are determined as a common subcutaneous neoplasms composed primarily of mature adipose (fat) cells [1]. That present as painless palpable masses.

In fact, these painless, slow-growing masses are the most common tumors in the body encountered by clinicians [2].

In 2% to 3% of affected patients, multiple lipomas can occasionally be associated with specific disorders such as multiple hereditary lipomatosis, which has an autosomal dominant mode of inheritance [3]. Dercum disease (adiposis dolorosa), which is typically seen in obese, postmenopausal women in whom multiple painful lipomas occur mostly around the hips and thighs with a simple dominant pattern of inheritance [4]. There are also rare congenital syndromes that include: Proteus syndrome, Multiple endocrine neoplasia (MEN) type 1, Gardner syndrome, Cowden syndrome, Benign symmetric lipomatosis (Madelung disease) and Bannayan-Riley-Ruvalcaba syndrome (BRRS) [5,6].

Anatomical pathology

Histologically, lipomas are soft, yellow to orange lobulated mass enclosed in a fine layer of fibrous tissue, uniform and well-circumscribed.

These benign tumors weighing only a few grams and usually range from 1 to >10 cm in size distributed throughout the body expected to affect the trunk and upper extremity [7]. However, occasionally can be found elsewhere adipocytes are normally present such as deeper locations of the body featuring the following: intermuscular and intramuscular lipoma, periosteal and periosteal lipoma, synovial lipomatosis and Intracranial lipoma [9].

Clinical pathology

Although these often-benign soft tissue lesions are rarely distinguishable from normal adipose tissue (Figure 1), lipomas derive from mesenchymal preadipocytes instead of mature adipocytes [10,11].

Some related benign variants of lipomas include a heterogeneous combination of other mesenchymally derived tissues such as: angioliipoma, which composed of vast narrow vascular ruts the mature adipocytes; fibrolipoma which contain plentiful fibrous tissue; chondroid lipoma, which contain cartilaginous elements among adipocytes; ossifying lipomas, which contains mature metaplastic bone; myoliipoma which include adipocytes inter mixed with hematopoietic tissue; myxoliipomas, which contain abundant mucoid mesenchymal tissues; lipoblastoma, a rapidly growing neo-

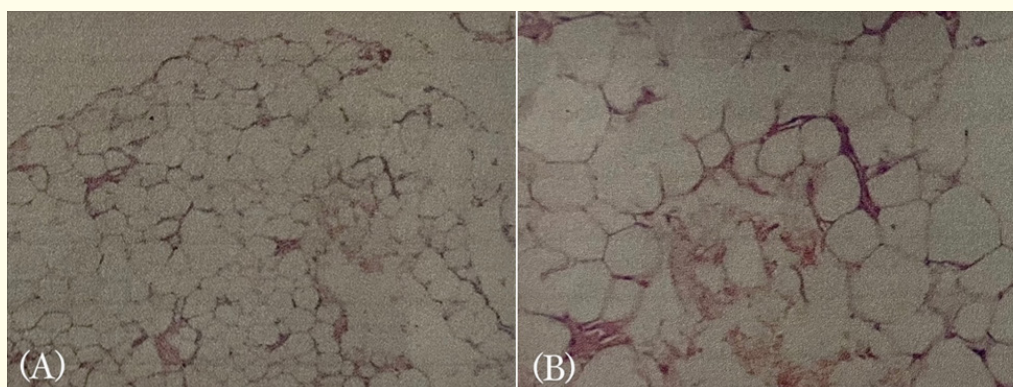


Figure 1: Histopathological examination of the specimen (haematoxylin and eosin). (A) A view of the lipoma showing adipose cells. (B) A view with mature adipose cells without atypia.

Credit: Seyed Amirhossein Dormiani Tabatabaei; M.D.

plasm composed of embryonal white fat with variable degrees of myxoid changes. Occurs predominantly in infancy; spindle cell lipoma, which get their name from the spindle cells they contain [9].

Epidemiology

Lipomas represent the most common noncancerous soft-tissue tumor in humans and have a prevalence of about 1 out of every 100 persons worldwide [13]. The prevalence of multiple lipomas has been cited as 5% of patients [8]. Lipomas have a negligibly higher incidence in males compared to females [12]. Although they can arise at any age, they are typically noted in middle-aged adults especially those of the fourth to sixth decades of age and develops in all races equally [13].

Etiology

The exact cause of lipomas is unknown. A genetic association has been demonstrated in a minority of patients, a gene association has been described on chromosome 12 in some solitary lipomas; In a subgroup of lipomas, spontaneous mutation in the HMGA2-LPP (located on 12q14.3) was involved in tumor pathogenesis [14]. The following chromosomal aberrations have been linked to proliferation of adipocytes: 13q portion loss, 12q13-15 region, 6p21-23 region, and other loci anomalies [15].

The incidence of lipomas is also boosted in patients with obesity, dyslipidemia [16] mitochondrial dysfunction [17] and endocrinopathies such as nodular goiter [18], diabetes mellitus [19] and Cushing's syndrome [20]. Considerable reports of long-term immunosuppression (especially corticosteroid therapy) association with the development of lipomas have been stated [21]. A massive lipoma evolution in a diabetic patient treated with chlorpropamide has also been reported [22]. Following statements postulates the mechanisms responsible for the genesis of lipomatous neoplasms

following antecedent traumatic injury. A conceivable link between trauma and lipoma development which have been dubbed post-traumatic lipomas (PTL) has been proposed [23], hypothesizing implicated trauma leads to the penetration of normal deep adipose tissue through a dissociated overlying septa named Scarpa's fascia at the level of a perforating vessel to shape "pseudolipoma". It consists of typical adipose tissue in an abnormal site and is not supposed as a true lipoma because it is not encapsulated [24,25]. Alternatively, the local blunt trauma to the respective area also causes subsequent haematoma, lymphatic effusion, local inflammation and necrosis leading to cytokine release triggering mesenchymal precursors (preadipocytes) differentiation and development to mature adipocytes and the formation of lipomas [9]. It is also speculated that chronically minor traumas especially to the areas, in which fat tissue is found between the bone and the firm skin, may activate the development and enlargement of lipomas. Metabolic regulation of adipose tissue have complex controlling aspects. Local or circulating growth factors (GH) or insulin-like growth factor (IGF), cytokines, or products of degrading haematoma could initiate these differentiations [26]. A specific example of this clinical condition is the 'lipoma arborescens'. This entity can be illustrated as subsynovial villous proliferation of mature adipocytes due to co-existing chronic inflammation of the synovium [26,27]. Several criteria have been cited to clarify a cause-and-effect relationship: The severity of the injury to initiate reparative multiplication of cells; prior integrity of the affected part; tumor arising within the site of the injury; histologic combination of tumor consistent with underlying tissue; and reasonable latent period [28,29].

Diagnosis

History and physical examination by a medical doctor are the basis of diagnosis. Lipomas oftentimes present as a soft non-tender mass as illustrated in figure 2.

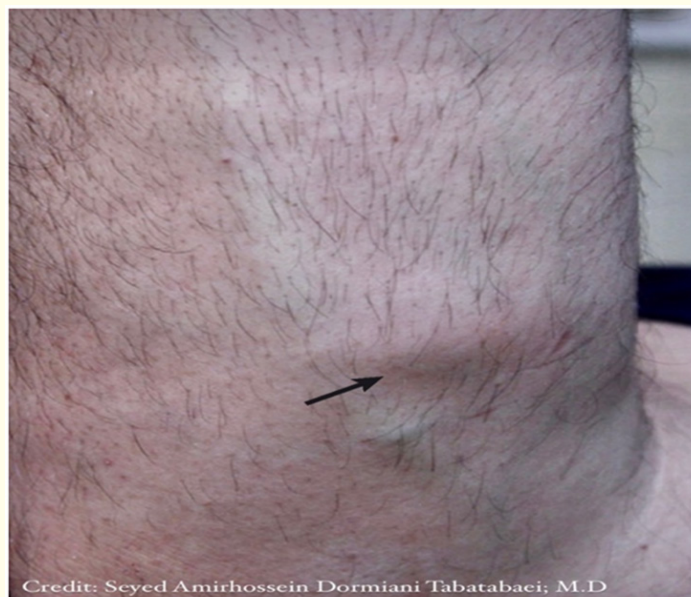


Figure 2: A 39-year-old man presented with a subcutaneous lipoma on the lateral side of the left forearm (the arrow). The mass, was mobile with respect to the over-lying skin but fixed to underlying structures.

Subcutaneous lipoma has a characteristic “doughy” feel on palpation [30]. Occasionally radiologic study may be prudent in cases to confirm the adipose nature of the lesion, include the following.

Location in deep tissues, the thigh, or retroperitoneal space, fixation to underlying tissues, pain, rapid growth and giant size. Plain radiograph shows an area of typical radiolucency known as a “water-clear density” [31]. Using ultrasound examination, a homogeneous and circumscribed hyperechoic area may be observed as shown in figure 3 [32].

Computed tomography (CT), exhibit non-enhancing, low attenuation lesions with smooth edges and distinct margins [33]. In magnetic resonance (MR) imaging, lipomas appear as a homogeneous, high-intensity signal similar to subcutaneous fat [34]. However, histologic examination after complete excisional biopsy remains definite diagnostic method [35]. It is cited that a clinicopathological correlation between the cytogenetic and the morphological subtypes of lipomatous neoplasms could serve as a significant diagnostic standards in controversial cases [27].

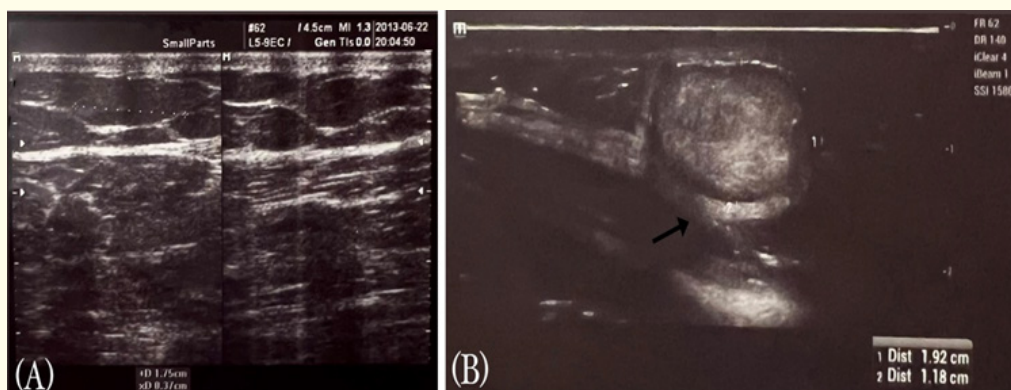
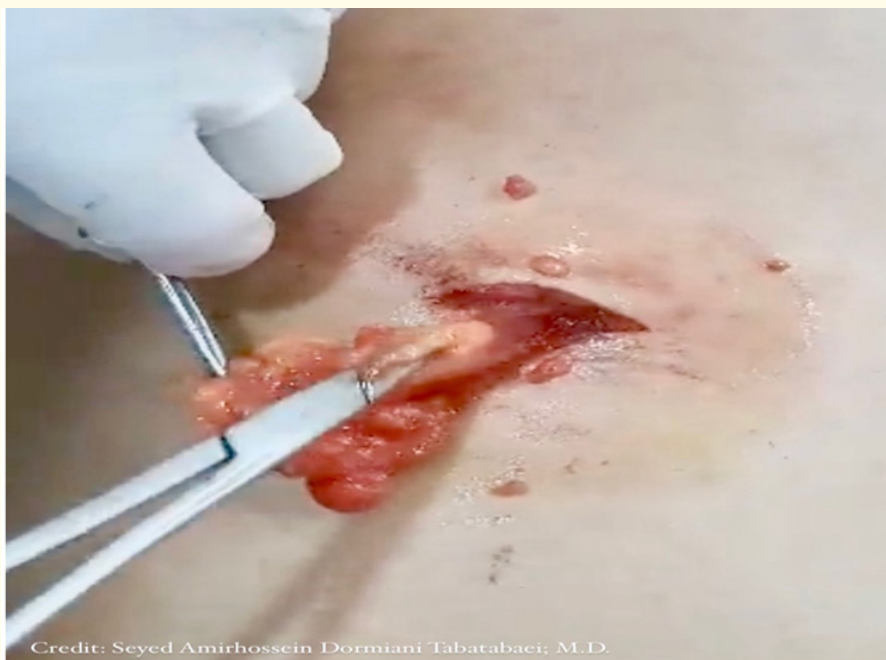

Figure 3: (A) A lipomas sonogram of a 40-year old man with a 4-year history of a right buttock mass. (B) lipoma sonogram of a 60-year old man with superficial abdominal mass. The arrow shows a lipoma’s hyperechoic capsule. Credit: Seyed Amirhossein Dormiani Tabatabaei; M.D.

Treatment

Lipomas do not regress spontaneously. Unchanging lesions often are observed without intervention. The majority of the patients desire treatment for lipomas due to cosmetic reasons (50). However, The decision to employ surgical excision relies on considerable factors, including size of lesion (especially in cases with

the size of greater than 10 cm), rapid growth, location, patient comorbidities and symptoms such as pain or itching. liposuction is an alternative removing strategy for large lipomas [36]. Complete surgical excision of the capsule and lobules is recommended for a better outcome [37]. (Figure 4).



Credit: Seyed Amirhossein Dormiani Tabatabaei; M.D.

Figure 4: The exisional biopsy of a subcutaneous lipoma located on the back of a 41-year old woman. The patient complained of swelling and itching over the upper trunk around the site of mass. Intraoperatively, the lobulated tumor was found to resect completely. Eight months after resection, there was no recurrence.

Liposuction and lipolytic injection therapies are used in the management of lipomas [38]. Employing injections of Prednisolone (a corticosteroid agent) and isoproterenol (a β -2 adrenergic agonist agent) in combination is also a modality of treatment that induces the lipolysis and decreases superficial subcutaneous lipoma's volume by 50% over 4 weeks in addition to the ease of post-injection surgical removal [39]. Furthermore, intralesional phosphatidylcholine and deoxycholate have been employed to shrink tiny lipomas [40].

Complications

Lipomas seldom cause complications. However, the mass effect is reported in some cases, Operative complications include neurovascular injury, hematoma, and hemorrhage [37].

Prognosis

The prognosis is remarkable for benign lipomas and carry no risk for malignant transformation [2]. Recurrence is not expected

if the anatomical excision was complete [37]. However a 3-year follow-up is recommended. In patients with complex anatomical infiltration, follow-up MR imaging to monitor for local recurrence is reasonable if symptoms develop [38].

Malignant variation

Liposarcomas Like lipomas, usually present as a small painless mass, although high-grade lesions may develop rapidly [42]. The etiology of a liposarcoma is unknown, malignant transformation of lipomas is rare [43].

MR imaging shows thick irregular septa are enhanced with gadolinium contrast.

Treatment of liposarcomas requires wide local excision even amputation, (neo)adjuvant chemotherapy or radiotherapy are administered [44].

The most common complications of liposarcomas are recurrence and metastasis [45].

Clinical case series

To demonstrate the clinical manifestation and surveillance of lipomas, a series of 12 patients is briefly reviewed (Table 1). 8 male and 4 female patients presented at an average age of 49 years (range, 30-68). The mean tumor size was 2.3 cm × 1.4 cm × .9 cm. A miscellany of presentations was inspected that included a lesion on the body surface. The most common presenting symptoms were

the explanation of a bulk, discomfort, swelling and decreased function. Two patients complained of itching over the mass location.

Surgical incision and approach were the same. Some lipomas involved surrounding tissues such as nerves, vasculature, musculature, tendons, and skin, which demonstrated the possibility of these neoplasms to interfere with functions of the limbs. As a result, half of them needed significant dissection from adherent structures to provide complete excision. Ten of 12 patients returned for follow-up between 6 and 36 months. There were no recurrences.

Patient No.	Age	Sex	Location	Presenting symptoms	Tissue involvement	Tumor size	Treatment approach	Follow-up	Recurrence	Note
1	60	M	Lumbosacral	Painless mass × 4 years	Superficial, fixed to underlying Tissue, not fixed to overlying skin	5.1 × 2.9 × 2 cm ³	Surgery Longitudinal incision, simple dissection.	36 months	No	-
2	39	M	Anterior ulnar aspect of forearm	Painless mass × 4 years	Superficial, fixed to underlying Tissue, not fixed to overlying skin	2 × 1.1 × .5 cm ³	Surgery Longitudinal incision, simple dissection.	N/A	N/A	Figure 2
3	66	M	Posterior aspect of the left thigh	Painless mass × 12 months, Itching	Superficial, Fixed to Overlying/underlying Tissue	3.5 × 1.7 × 1.1 cm ³	Surgery Longitudinal incision, simple dissection.	12 months	No	-
4	41	F	Left shoulder	Painless mass × 16 Months	Superficial, Fixed To underlying Tissue, not fixed to overlying skin	1.8 × 1 × .9 cm ³	Surgery Longitudinal incision, simple dissection.	30 months	No	-
5	40	M	Left lower quadrant of abdomen	Painless mass × 4 years	Superficial, Fixed To underlying Tissue, not fixed to overlying skin	2.2 × 1.8 × 1.1 cm ³	Surgery Longitudinal incision, simple dissection.	30 months	No	Figure 3 (B)
6	68	M	Left Infrascapular	Painless mass × 14 months	Superficial, Fixed To underlying Tissue, not fixed to overlying skin	2.6 × 2 × 1.1 cm ³	Surveillance	N/A	N/A	-
7	41	F	Posterior upper trunk	Swelling mass × 3 Years, Itching	Superficial, Fixed To Overlying/underlying Tissue	3 × 1.6 × 1.3 cm ³	Surgery Longitudinal incision, simple dissection.	8 months	No	Figure 4
8	54	M	dorsal radial aspect of forearm	Painless mass × 14months, itching	Superficial, Fixed To underlying Tissue, not fixed to overlying skin	1.4 × 1.1 × .5 cm ³	Surgery Longitudinal incision, simple dissection.	N/A	N/A	-
9	56	M	Multiple masses	Painless mass × 6 years	Superficial, Fixed To underlying Tissue, not fixed to overlying skin	8 masses observed, the largest one Was 2.6 × 1.7 × .5 cm ³	Surveillance	26 months	No changes was noticed	Unremarkable family history
10	33	F	Anterior aspect of left thigh	Painless mass × over 10 years	Superficial, Fixed To underlying Tissue, fixed to overlying skin	3.4 × 2.4 × 1 cm ³	Surgery Longitudinal incision, simple dissection.	6 months	No	-

11	54	M	Medial aspects of right and left arms	Painless mass × 2 years	Superficial, Fixed To underlying Tissue, not fixed to overlying skin	1.1 × .9 × .5 cm ³ And 2.1 × 1.3 × .5 cm ³	Surveillance	10 months	No	-
12	30	F	Lateral aspect of left flank	Painless mass × 6 Months	Superficial, Fixed To underlying Tissue, not fixed to overlying skin	.9 × .5 × .- cm ³	Surveillance Changed to surgery	18 months	Changed to 1.4 × .9 × .6 cm ³ and another 1 × .5 × .-cm ³ Lesion detected	Pathological assessment Reported benign lipomas

Table 1: Clinical manifestation and surveillance of lipomas*.

*F: Female; M: Male; L: Left; R: Right; N/A: Not Available

Summary and Conclusion

This article summarizes the present understanding of the pathophysiology, modalities of diagnosis/treatment, and complications of lipomatous neoplasms. Lipomas stay a common benign tumor of the body. Superficial lipomas may be diagnosed by physical examination unaided. For more complex situations, Magnetic resonance imaging (MRI) is most beneficial for diagnosis and treatment planning. Most lipomas are approached by surgical excision with few complications or reproduction. Malignant permutation seems rare.

Declaration

The author would like to thank all patients who participated in this study. All participants gave their informed consent.

Author certify that have no affiliations with or involvement in any organization or entity with any financial interest or non-financial interest in the subject matter or materials discussed in this manuscript.

Conceptualization, investigation, methodology, project administration, resources, supervision, validation, visualization, and writing-review and editing were done by SADT.

Funding

The findings of this study are available from the corresponding author [SA] on request.

Bibliography

- Kosztyuova T and Shim TN. "Rapidly enlarging lipoma". *BMJ Case Reports* (2017).
- Johnson CN., et al. "Lipomatous Soft-tissue Tumors". *Journal of the American Academy of Orthopaedic Surgeons* 26.22 (2018): 779-788.
- McFarland GB and Hoffer MM. "Paralysis of the intrinsic muscles of the hand secondary to lipoma in Guyon's tunnel". *Journal of Bone and Joint Surgery-American Volume* 53.2 (1971): 375-376.
- Brodovsky S., et al. "Adiposis dolorosa (Dercum's disease): 10-year follow-up". *Annals of Plastic Surgery* 33.6 (1994): 664-668.
- Vásquez Elera L., et al. "[Familiar adenomatous polyposis: report of 2 cases]". *Revista de Gastroenterología del Perú* 38.1 (2018): 78-81.
- Baldino ME., et al. "Gardner syndrome with maxillofacial manifestation: A case report". *Special Care in Dentistry* 39.1 (2019): 65-71.
- Creytens D. "A contemporary review of myxoid adipocytic tumors". *Seminars in Diagnostic Pathology* 36.2 (2019): 129-141.
- Charifa A., et al. "Lipoma Pathology". In: StatPearls. Treasure Island (FL): StatPearls Publishing (2022).
- Weiss SW and Goldblum JR. "Benign Lipomatous Tumors". In: Enzinger FM, Weiss SW, eds. *Soft Tissue Tumors*. 3rd edition. St Louis, Mo: Mosby (1995): 381-430.
- Phalen GS., et al. "Lipomas of the upper extremity: a series of fifteen tumors in the hand and wrist and six tumors causing nerve compression". *The American Journal of Surgery* 121.3 (1971): 298-306.
- Rydholm A and Berg NO. "Size, site and clinical incidence of lipoma. Factors in the differential diagnosis of lipoma and sarcoma". *Acta Orthopaedica Scandinavica* 54.6 (1983): 929-934.

12. Salam GA. "Lipoma excision". *American Family Physician* 65.5 (2018): 901-904.
13. Panagopoulos I., et al. "Fusion of the HMGA2 and C9orf92 genes in myolipoma with t(9;12) (p22;q14)". *Diagnostic Pathology* 11 (2016): 22.
14. Ameloot E., et al. "Update of Pediatric Lipomatous Lesions: A Clinicopathological, Immunohistochemical and Molecular Overview". *Journal of Clinical Medicine* 11.7 (2022): 1938.
15. Chrisinger JSA. "Update on Lipomatous Tumors with Emphasis on Emerging Entities, Unusual Anatomic Sites, and Variant Histologic Patterns". *Surgical Pathology Clinics* 12.1 (2019): 21-33.
16. Berkovic SF., et al. "Mitochondrial dysfunction in multiple symmetrical lipomatosis". *Annals of Neurology* 29.5 (1991): 566-569.
17. Leiva SF., et al. "Lipoma in the thyroid?" *Journal of Pediatric Endocrinology and Metabolism* 17.7 (2004): 1013-1015.
18. Weinberg T and Feldman M. "Lipomas of the gastrointestinal tract". *American Journal of Clinical Pathology* 25.3 (1955): 272-281.
19. Miyake O., et al. "[Adrenal myelolipoma associated with Cushing's syndrome: a case report]". *Hinyokika Kyo* 38.6 (1992): 4-681.
20. Clayman E., et al. "Corticosteroid-Associated Angiolipomatosis". *Eplasty* 17 (2017): ic9.
21. Garfinkel HA. "A massive lipoma in a patient receiving chlorpropamide therapy". *Postgraduate Medical Journal* 47.544 (1971): 137-138.
22. Brooke RI and MacGregor AJ. "Traumatic pseudolipoma of the buccal mucosa". *Oral Surgery, Oral Medicine, Oral Pathology* 28.2 (1969): 223-225.
23. Meggitt BF and Wilson JN. "The battered buttock syndrome: fat fractures: a report on a group of traumatic lipomata". *British Journal of Surgery* 59 (1972): 165-169.
24. Herbert DC and DeGeus J. "Post-traumatic lipomas of the abdominal wall". *British Journal of Plastic Surgery* 28 (1975): 303-306.
25. Copcu E. "Can intramuscular lipoma have a post-traumatic origin". *British Journal of Dermatology* 149.5 (2003): 1084-1085.
26. Tiao WM., et al. "Lipoma arborescens of the knee: a case report". *Journal of the Formosan Medical Association* 100 (2001): 412-415.
27. Cohen S., et al. "Post-traumatic soft tissue tumors: case report and review of the literature a propos a post-traumatic paraspinal desmoid tumor". *World Journal of Surgical Oncology* 6 (2008): 28.
28. Ewing J. "Buckley lecture: Modern attitude toward traumatic cancer". *Archives of Pathology* 19 (1935): 690.
29. Posch JL. "Tumors of the hand". *Journal of Bone and Joint Surgery-American Volume* 38-A.3 (1956): 517-539.
30. Leffert RD. "Lipomas of the upper extremity". *Journal of Bone and Joint Surgery-American Volume* 54.6 (1972): 1262-1266.
31. James JJ., et al. "The Breast". In: Adam A, Dixon AK, eds. *Grainger and Allison's Diagnostic Radiology*. 5th edition. Philadelphia, Pa: Elsevier (2008).
32. Weekes RG., et al. "CT of soft-tissue neoplasms". *American Journal of Roentgenology* 144.2 (1985): 355-360.
33. Egund N., et al. "CT of soft-tissue tumors". *American Journal of Roentgenology* 137.4 (1981): 725-729.
34. Lee YH., et al. "Intramuscular lipoma in thenar or hypothenar muscles". *Hand Surgery* 9.1 (2004): 49-54.
35. Lichon S and Khachemoune A. "Clinical presentation, diagnostic approach, and treatment of hand lipomas: a review". *Acta Dermatovenerol Alp Pannonica Adriatic* 27.3 (2018): 137-139.
36. Datir A., et al. "MRI of soft-tissue masses: the relationship between lesion size, depth, and diagnosis". *Clinical Radiology* 63.4 (2008): 373-378.
37. Bancroft LW., et al. "Benign fatty tumors: classification, clinical course, imaging appearance, and treatment". *Skeletal Radiology* 35.10 (2006): 719-733.
38. Amber KT., et al. "Injection therapy for the management of superficial subcutaneous lipomas". *The Journal of Clinical and Aesthetic Dermatology* 7.6 (2014): 46-48.
39. Redman LM., et al. "Association of β -2 adrenergic agonist and corticosteroid injection in the treatment of lipomas". *Diabetes, Obesity and Metabolism* 13.6 (2011): 517-522.
40. Kopera D., et al. "Intralesional lipolysis with phosphatidylcholine for the treatment of lipomas: pilot study". *Archives of Dermatological* 142.3 (2006): 395-396.

41. Sawhney KK., *et al.* "Liposarcoma of the hand". *American Surgeon* 41.2 (1957): 117-120.
42. Sampson CC., *et al.* "Liposarcoma developing in a lipoma". *Archives of Pathology* 69 (1960): 506-510.
43. MJ, Naqvi AH., *et al.* "Predictive value of gadolinium enhancement in differentiating ALT/WD liposarcomas from benign fatty tumors". *Skeletal Radiology* 34.5 (2005): 272-278.
44. Mack LA., *et al.* "Preoperative chemoradiotherapy (modified Eilber protocol) provides maximum local control and minimal morbidity in patients with soft tissue sarcoma". *Annals of Surgical Oncology* 12.8 (2005): 646-653.
45. Loubignac F., *et al.* "Myxoid liposarcoma: a rare soft-tissue tumor with a misleading benign appearance". *World Journal of Surgical Oncology* 7 (2009): 42.