Acta Scientific Orthopaedics (ISSN: 2581-8635)

Volume 5 Issue 12 December 2022

Research Article

Osteochondral Allograft Transplantation in the Knee of a Teenage Athlete: A Case Report

Bárbara Choupina*, Inês Casais, João Dinis, Filipe Lima Santos, Paulo Jorge Carvalho and Rui Lemos

Centro Hospitalar de Vila Nova de Gaia/Espinho, Porto, Portugal

***Corresponding Author:** Bárbara Choupina, Centro Hospitalar de Vila Nova de Gaia/Espinho, Porto, Portugal.

DOI: 10.31080/ASOR.2022.05.0639

Received: October 19, 2022

Published: November 13, 2022

Abstract

Introduction: Traumatic osteochondral lesions of the knee in young athletes can result in significant morbidity. The aim of our study was to describe the results of the use of an osteochondral allograft for the treatment of an extensive knee osteochondral lesion in a skeletally mature teenager.

Methods: A 17 years old male presented with knee pain, stiffness and locking sensation after a knee trauma related to sports. Imaging studies revealed an osteochondral injury of the lateral femoral condyle with approximately 4x2 cm. The patient underwent surgical treatment, in which an osteochondral graft was used to repair the lesion and fixated with resorbable cannulated screws.

An evaluation of range of motion, pain and knee function (IKDC Score) before the surgical procedure and at the end of 24 months of follow-up was performed.

Results: Range of motion increased from 100º preoperatively to 120º; pain improved from a daily, constant pain with an intensity of 6 (VAS) preoperatively to a sporadic pain with an intensity of 1 (VAS). The preoperative IKDC score was 36.8 and increased to 92. Return to sports was allowed at 12 months. There were no complications resulting from the procedure.

Conclusions: Although many studies are available on the efficacy of allografts in adults, little is published in children about the outcomes of allograft transplantation.

In this case, the use of an osteochondral allograft allowed for the restoration of range of motion, excellent functional capability and pain relief in the affected knee.

Keywords: Osteochondral Lesion; Allograft; Transplant; Knee; Adolescent

Introduction

Osteochondral injuries in pediatric patients may occur during an acute trauma, resulting from a shearing force that produces a stress fracture through cartilage matrix or the subchondral bone [1,2]. The knee is the most frequently affected joint, especially the medial femoral condyle, accounting for approximately 69% of all lesions. The lateral femoral condyle is typically the less affected, representing 15% of all injuries [3-5].

Because the injury is usually subtle and asymptomatic, the diagnosis of acute lesions is usually delayed. If left untreated, these cartilage defects have limited ability to heal [6] and tend to progress to osteoarthritis [7]. This is particularly problematic in active pediatric and adolescent patients, that have high functional demands and long-life expectancies [8,9].

The treatment of osteochondral injuries is challenging and is dependent on their size and location. Among the many possibilities presented so far, none is ideal. Treatments options include loose body removal, microfracture [10,11], fragment fixation or more advanced cartilage replacement [12,13]. In the case of young, skeletally mature patients with large osteoarticular defects of the knee,

the use of osteochondral allografts provides a good reconstructive solution.

Osteochondral allografts involve the transfer of mature hyaline cartilage containing viable chondrocytes along with a supporting subchondral bone to fill the defect [14]. This technique shows promising results in adults but few reports are available in pediatric or adolescent patients. There are some concerns about the use of living allograft transplants in young patients because of their age and growth potential [2]. However, osteochondral transplantation has shown to be a good treatment option in young patients with large osteochondral lesions.

Methods

A 17 years old male was observed in consultation at our hospital 6 months after a knee trauma related to sports (while playing basketball). The patient presented with knee pain, stiffness and a locking sensation. At physical examination there was pain at the extremes of mobility and a limitation on the range of motion (0-100º). There was tenderness in the lateral joint line. There were no signs of instability.

The radiograph (Figure 1,2) and magnetic resonance imaging (Figure 3,4) studies revealed an osteochondral injury of the lateral femoral condyle with approximately 4 x 2 cm and 2 intra-articular loose bodies, corresponding to a Grade 4 in the ICRS classification [15].

Figure 1: Preoperative x-ray (anteroposterior view).

Figure 2: Preoperative x-ray (lateral view).

Figure 3: Preoperative MRI (coronal plane).

The patient underwent osteochondral graft reconstruction of the lateral femoral condyle through an anterolateral approach. Intra-operatively there was confirmation of the lack of viability of the osteochondral loose body and the lesion's dimensions and depth. The graft was harvested from the corresponding area of the donor lateral condyle and was trimmed to fit the size of the lesion. Two resorbable cannulated screws were used to fix the graft (Figure 5,6). An articular drain was left in place and removed in the first day after surgery.

Figure 4: Preoperative MRI (sagittal plane).

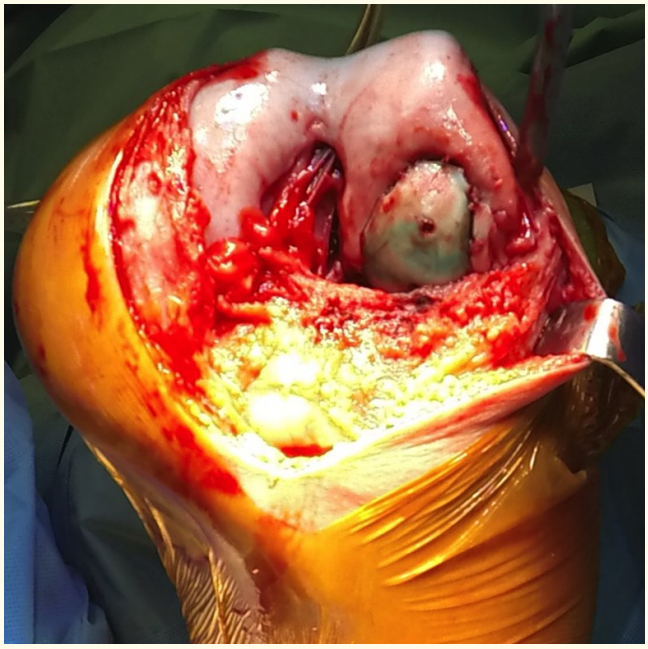

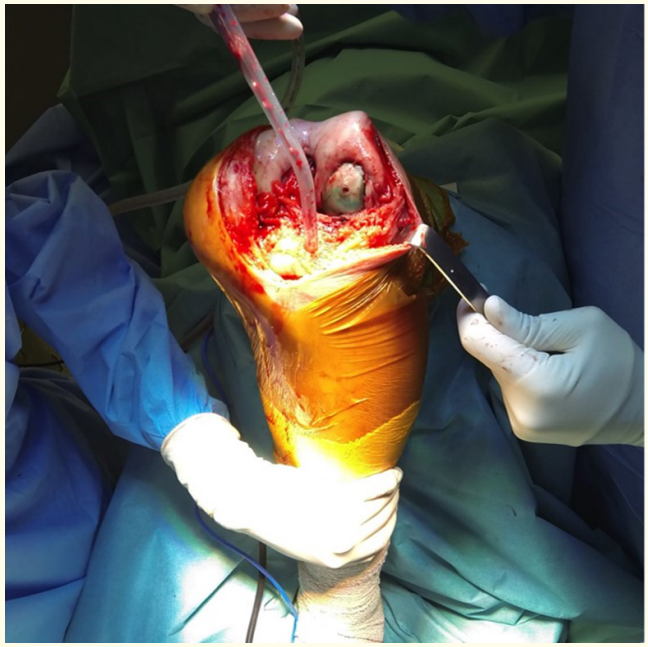

Figure 5 and 6: Intraoperative image after implantation of osteochondral allograft, demonstrating anatomic contour matching.

Mobilization started in the immediately after surgery. The patient initiated progressive weight bearing at 6 weeks postoperatively, after radiographic confirmation of graft integration. We evaluated range of motion with the use of a goniometer, pain with the visual analog scale and knee function with the use of the IKDC Score before the surgical procedure, at 6 months, at 12 months and at 24 months follow-up.

Results

- There were no complications in the immediate or late postoperative period.
- An improvement was observed in terms of range of motion, pain and functional capability.
- Range of motion increased from 100º preoperatively to 120º at the end of the follow-up.
- An improvement was also seen in pain frequency and intensity from a daily, constant pain with an intensity of 6 (visual analog scale) preoperatively to a sporadic pain with an intensity of 1 (visual analog scale) at 24 months follow-up.

- The radiograph and magnetic resonance imaging (Figure 7-9) studies in the follow-up period showed a correct graft integration and maintenance of the articular joint space.
- The preoperative IKDC score was 36.8 and increased to 92 at 24 months follow-up. Return to sports was allowed at 12 months, and the patient was able to return to its previous activity level.
- Both the patient and the parents were very satisfied with the procedure and the clinical result.

Figure 7: Postoperative x-ray (anteroposterior view).

Figure 8: Postoperative x-ray (lateral view).

Figure 9: Postoperative MRI (sagittal plane).

Discussion

Traumatic osteochondral lesions in young, active patients may be associated with immediate but also long-term morbidity and functional impairment [1-3].

These patients, due to their age and very high functional demand, are considered unsuitable candidates for total knee replacement or arthrodesis. The use of allografts has been associated with a high long-term survival rate, especially in those presenting with osteochondritis dissecans or lesions resulting from trauma. This technique is preferred in medium to large, full-thickness lesions,

or after failure of other primary surgical procedures [16-18]. Garrett., *et al*. [19] reported that in 17 knees undergoing plug allograft transplantation, 16 were a success at two to nine years after surgery. Emmerson., *et al*. [20] demonstrated in a study with a mean of 7.7 years of follow up, a 78% overall success rate in osteochondral lesions that had failed previous treatment.

Published studies in adults have stated that this treatment is associated with favorable outcomes in terms of pain, functional capability and patient satisfaction [17,18,21-25]. These results are comparable with outcomes reported for osteochondral allograft transplantation of the knee in children and adolescents. Murphy., *et al*. [2] reported in a study with 39 patients with a mean age of 16.4 years, 90% of graft survivorship at 10 years and an 88% good/excellent patient rating at final follow-up. A recent study by Lyon., *et al*. [26] showed that in 11 patients with a mean age of 15.2 years and an average lesion size of 5.1 cm, patients presented a clinical improvement, improved function and return to sport. Regarding return to sports, McCarthy., *et al*. [27] established, in a retrospective review of 13 high-level athletes at the high school, that 77% returned to play at a mean of 7.9 months, with 38% returning to preinjury level of sports.

The main drawback to this treatment is the potential for disease transmission. This risk in counterbalanced by the significant advantages - no donor site morbidity, ability to restore bone stock, and the ability to adjust allografts in size and shape to fit the defect.

Fresh allografts, obtained within 24-72 hours, provide higher chondrocyte availability but carry a higher risk for disease transmission. On the other hand, cryopreserved frozen allografts have reduced immunogenicity and disease transmission, but lower chondrocyte availability [17,18,21-23]. Emmerson., *et al*. [20] reported that in the 64 patients submitted to fresh osteochondral allograft, 10 underwent reoperation and none were reportedly for infectious disease transmission. Lyon., *et al*. [26] did not find any case of infectious disease transmission in their study.

Conclusions

Although many studies are available on the efficacy of allografts in adults, little is published in children about the outcomes of allograft transplantation.

In the presented case, the use of an allograft allowed for the restoration of range of motion, excellent functional capability (according to the IKDC Score) and pain relief in the affected knee, allowing the patient to return to sport. Patient satisfaction was high, and the graft presented with no signs of necrosis or resorption at the end of the follow-up. Larger series of patients studied and with a longer follow-up are needed in order to adequately assess the results of the use of this technique.

Bibliography

1. Boden BP., *et al*. "Patellofemoral Instability: Evaluation and Management". *Journal of the American Academy of Orthopaedic Surgeons* 5.1 (1997): 47-57.
2. Murphy RT., *et al*. "Osteochondral allograft transplantation of the knee in the pediatric and adolescent population". *American Journal of Sports Medicine* 42.3 (2014): 635-640.
3. Linden B. "The incidence of osteochondritis dissecans in the condyles of the femur". *Acta Orthopaedica Scandinavica* 47.6 (1996): 664-667.
4. Durur-Subasi I., *et al*. "Osteochondral Lesions of Major Joints". *The Eurasian Journal of Medicine* 47.2 (2015): 138-144.
5. Moktassi A., *et al*. "Imaging of osteochondritis dissecans". *Orthopedic Clinics of North America* 43.2 (2012): 201-211.
6. Steadman JR., *et al*. "Outcomes of microfracture for traumatic chondral defects of the knee: average 11-year follow-up". *Arthroscopy* 19.5 (2003): 477-484.
7. Prakash D and Learmonth D. "Natural progression of osteochondral defect in the femoral condyle". *Knee* 9.1 (2002): 7-10.
8. Bedi A., *et al*. "Management of articular cartilage defects of the knee". *Journal of Bone and Joint Surgery America* 92.4 (2010): 994-1009.
9. Gelber AC., *et al*. "Joint injury in young adults and risk for subsequent knee and hip osteoarthritis". *Annals of Internal Medicine* 133.5 (2000): 321-328.
10. Mithoefer K., *et al*. "Clinical efficacy of the microfracture technique for articular cartilage repair in the knee: an evidence-based systematic analysis". *American Journal of Sports Medicine* 37 (2009): 2053-2063.

11. Steadman JR., *et al*. "Microfracture: surgical technique and rehabilitation to treat chondral defects". *Clinical Orthopaedics and Related Research* 391 (2001): S362-S369.

12. Hunziker EB. "Articular cartilage repair: basic science and clinical progress: a review of the current status and prospects". *Osteoarthritis Cartilage* 10 (2002): 432-463.

13. Gudas R., *et al*. "A prospective, randomized clinical study of osteochondral autologous transplantation versus microfracture for the treatment of osteochondritis dissecans in the knee joint in children". *Journal of Pediatric Orthopaedics* 29 (2009): 741-748.

14. Gortz S and Bugbee WD. "Allografts in articular cartilage repair". *The Journal of Bone and Joint Surgery American* 88 (2003): 1374-1384.

15. Brittberg M and Winalski CS. "Evaluation of cartilage injuries and repair". *The Journal of Bone and Joint Surgery American* 85-A.2 (2003): 58-69.

16. Osteochondral Grafting of Knee: Clinical Policy (Effective 01/11/2016) © 1996-2017, Oxford Health Plans, LLC.

17. Boscainos., *et al*. "Knee Osteochondral Allografts. In Topics in Tissue Engineering, Volume 4. Eds, N Ashammakhi, R Reis, and F Chiellini© (2008).

18. Browne JE and Branch TP. "Surgical alternatives for treatment of articular cartilage lesions". *Journal of the American Academy of Orthopaedic Surgeons* 8.3 (2000): 180-189.

19. Garrett JC. "Fresh osteochondral allografts for treatment of articular defects in osteochondritis dissecans of the lateral femoral condyle in adults". *Clinical Orthopaedics and Related Research* 303 (1994): 33-37.

20. Emmerson BC., *et al*. "Fresh osteochondral allografting in the treatment of osteochondritis dissecans of the femoral condyle". *American Journal of Sports Medicine* 35 (2007): 907-914.

21. Willers C., *et al*. "A CURRENT REVIEW ON THE BIOLOGY AND TREATMENT OF ARTICULAR CARTILAGE DEFECTS (PART I and PART II)". *Journal of Musculoskeletal Research* 07.03n04 (2003): 157-181.

22. Falah M., *et al*. "Treatment of articular cartilage lesions of the knee". *International Orthopaedics* 34.5 (2010): 621-630.

23. Gross AE. "Fresh osteochondral allografts for post-traumatic knee defects: surgical technique". *Operative Techniques in Orthopaedics* 7 (1997): 334-339.

24. Chahal J., *et al*. "Outcomes of osteochondral allograft transplantation in the knee". *Arthroscopy* 29.3 (2013): 575-588.

25. De Caro F., *et al*. "Large fresh osteochondral allografts of the knee: a systematic clinical and basic science review of the literature". *Arthroscopy* 31.4 (2015): 757-765.

26. Lyon R., *et al*. "Can fresh osteochondral allografts restore function in juveniles with osteochondritis dissecans of the knee?" *Clinical Orthopaedics and Related Research* 471 (2013): 1166-1173.

27. McCarthy MA., *et al*. "Can Competitive Athletes Return to High-Level Play After Osteochondral Allograft Transplantation of the Knee?" *Arthroscopy* 33.9 (2017): 1712-1717.