



Ocular Surface and Pre-Operative Cataract Surgery: Much Beyond Artificial Tears

Raphael Barcelos*

Department of Ophthalmology and Visual Sciences, Unifesp, Brazil

***Corresponding Author:** Raphael Barcelos, Department of Ophthalmology and Visual Sciences, Unifesp, Brazil.

Received: October 13, 2023

Published: January 06, 2024

© All rights are reserved by **Raphael Barcelos**.

Abstract

Over time, the evolution of cataract surgery and optical biometrics has led to surgeons have on hand instruments capable of promoting the elimination of ametropia residuals and minimize optical aberrations. However, the expected results in surgery cataracts depend mainly on good surgical planning, involving aspects such as the choice of intraocular lenses and precise routines to identify pathologies that may affect the ocular surface. In this context, this study aimed to carry out a review broad bibliographical, through exploratory methodology, where databases were used digital with selected works by authors relevant to the topic. It was concluded that the evaluation of homeostasis or identification of changes in the ocular surface before performing the biometry in the preoperative period of cataract surgery is of fundamental importance for the understanding the impact of these changes, allowing early identification and the treatment of ocular surface diseases such as dry eye in its different degrees of classification, contributing to the best choice of intraocular lenses and lower chances of refractive errors and residual ametropia.

Keywords: Evaluation of The Ocular Surface; Intraocular Lenses; Cataract Surgery; Dry Eye Disease

Introduction/Justification of the Review

The choice of intraocular lens for cataract surgery is made by measuring the anteroposterior axial length and the correct measurement of the corneal curvature using biometric formulas validated for the characteristics of each eye.

Dry eye is a multifactorial disease of the tears and ocular surface that results in symptoms of ocular discomfort, visual disturbances and tear film instability, with possible damage to the ocular surface being accompanied by an increase in film osmolarity lacrimal and inflammation of the ocular surface.

The tear film is directly related to the maintenance of the regularity pattern of corneal surface. Changes in the tear film, whether qualitative or quantitative promote direct interference in the quality of image capture and, therefore, As a result, we may have a topographic image that does not correspond to reality [1].

The expected results in cataract surgery depend not only on one act well-executed surgery, with an appropriate and accurate

technique, and it is also important to your surgical planning. Currently, where intraocular lenses are implanted toric, bifocal, trifocal, extended depth of focus (EDOF), and pseudo-accommodative there is a greater demand for refractive results by patients and the surgeon must not fail to consider and give due importance to the stability of the tear film and a surface healthy eye.

The evolution of cataract surgery and Optical Biometry has meant that surgeons have in hand instruments capable of not only promoting the elimination of residual ametropia, but also to minimize optical aberrations. Cataract surgeons need to employ its routine methods to identify pathologies that may affect the ocular surface. To the significant irregularities of the ocular surface must be corrected, so that measurements keratometric measurements are more accurate and the best intraocular lens is chosen.

Search Methodology and Literature Review

Search Methodology

The search methodology included digital databases such as Medline/Pubmed and Scielo. The accesses were carried out from

May 27th to June 22nd. In the database Medline/Pubmed, the words used in the search were: “ocular surface and eye biometry”.

In addition to the databases, TFOS/DEWS II - Definition and classification: Jennifer P. Craig, MCOptom, PhD1, Kelly K. Nichols, OD, PhD1, Esen K. Akpek, MD, Barbara Caffery, OD, PhD, Harinder S. Dua, MD, PhD, Choun-Ki Joo, MD, PhD, Zuguo Liu, MD, PhD, J. Daniel Nelson, MD, Jason J. Nichols, OD, PhD, Kazuo Tsubota, MD, PhD, Fiona Stapleton, MCOptom, PhD, 2017, the book on External Eye and Cornea Diseases/Brazilian Council of Ophthalmology; coordinator: Milton Ruiz Alves; editors Ana Luisa Hoffing Lima, Maria Cristina Nishiwaki Dantas, Milton Ruiz Alves. – 4th ed. Rio de Janeiro; Cultura Medica, 2016, the book Wavefront and Topography, Tomography and Biomechanics of the Cornea: propaedeutics complementary study in refractive surgery/Renato Ambrósio Jr. [et al.], - 2nd ed., the book “Catarata.

Faria, Marco Antônio Rey”, “and the book Polisuk, Paulo - Topography of the Cornea: atlas clinician/Paulo Polisuk. – 4. ed - Rio de Janeiro: Cultura Médica, 2015 were consulted.

Literature Review

Computerized corneal topographers using placido rings are based on the principle of reflection of the rings by the cornea. The anterior surface works like a mirror convex that reflects light, which is analyzed and captured by the surveyor to create the map topographic view of its anterior curvature. The tear film is directly related to the maintenance of the regularity pattern of the corneal surface. Changes in the tear film, whether Qualitative or quantitative will directly interfere with the quality of image capture and consequently we can have a topographic image that does not correspond to reality [1]. The use of lubricants can cause an increase in the tear film in the lower region of the cornea, which can lead to the demonstration of a strong increase in inferior corneal curvature.

Therefore, if using lubricants, even those without preservatives, care must be taken and ask the patient to blink several times to spread the lubricant evenly on the cornea at the time of the examination. In addition, the examination must be carried out by least 1 minute after instilling the eye drops, so that the tear lake formed inferiorly has already been drained [2].

The use of the placido disk aims to promote greater accuracy in determination of the central corneal power, as the placido topography is still the best and most direct way to evaluate the curvature of the anterior surface of the cornea [1]. Unfortunately, such equipment does not evaluate the posterior surface of the cornea and has certain limitations to analysis of data from the corneal periphery, in addition to topography being a very examining examination dependent [1].

From the 90s onwards, segment tomographs began to be developed anterior segment, which enabled the analysis of keratometry and more variables of the anterior segment.

Initially, the combination of placido technology with slit scanning was used.

Vertical lights, to triangulate the position of thousands of points on the anterior and posterior surface of the cornea [1].

Systems that do not have placido and use only Scheimpflug images calculate the anterior curvature indirectly through mathematical algorithms and elevation analysis. Elevation is the difference between the location of the spatial point located by the system and a ideal reference surface. Elevation maps complement map information of curvature, but they do not replace it [1].

The most used reference surface is the sphere that best fits the values found (BFS, from best fit sphere). In addition to BFS, there are maps that compare an incomplete sphere, which exclude data from a small zone whose center is the most high (Belin/Ambrosio-Enhanced Display-BAD), a symmetrical asphere (BFA, from best fit asphere) and a toric asphere (BFTA, from best fit toric asphere) [1].

BFTA maps from CT scanners are enabling a better understanding of asymmetries, irregularities and roughness of the corneal surfaces that give rise to high-order optical aberrations [1].

Analysis of corneal tomography elevation made it possible to calculate the corneal posterior curvature and total dioptric power of virgin corneas or corneas undergoing refractive surgery [1].

The Scheimpflug system enables segmental analysis of the eye in sagittal planes, from the anterior surface of the cornea to the posterior surface of the lens, which makes it possible to obtain measurements and real distances between structures and quantify opacities in the media [1].

There are several devices that use this system on the market. It is currently unknown how many optical aberrations an eye can tolerate without presenting symptoms, but this could explain causes of dissatisfaction in patients with toric or multifocal IOLs diffraction and understand the real role of the cornea in the vision of these patients [1]. The analysis of Zernike polynomials on corneal tomography in the preoperative period assist with the choice of intraocular lenses ensuring greater safety in the implantation of Premium IOLs. This is due because surgeons assume that optical aberrations from the aqueous humor, posterior capsule, and vitreous humor are insignificant and those of the IOLs and cornea can be measured with greater accuracy [1].

Corneal tomographs highlight the main high-order aberrations, which can without shown in both microns and diopters, second order aberrations such as defocus and astigmatism and third order, both vertical and horizontal or oblique, as well as trefoil and eat. We also have fourth-order astigmatism, such as tetraleaf, fourth-order astigmatism. order and spherical aberrations at the center. State-of-the-art CT scanners can show us additionally aberrations of: 5th; 6th; 7th; and 8th orders and the total RMS (of total root mean square) [1].

This RMS is the square root of the variance of the sum of the squares of all the coefficients of Zernike. It works as if it were a general and non-specific representation of the aberrations of the cornea [1].

Dry eye disease is probably the most common etiology for changes in ocular surface and follows a chronological line somewhat similar to the opacification of the crystalline. Other causes of ocular surface changes include: blepharitis; dystrophies of epithelium and basement membrane; dermatochalasis; Loose eyelid syndrome; conjunctivitis allergic; Salzmann Nodular Degeneration; and bullous keratopathy [4].

The main signs and symptoms of dry eye are: burning eyes; ocular hyperemia; tearing; burning eyes; visual blurring; foreign

body sensation; irritation eyepiece; and photophobia. Dry eye is found, in practice, in more than half of patients undergoing cataract surgery [4], being Meibomius Gland Dysfunction (MGD) diagnosed in the majority of patients with dry eye disease and in more than half of candidates for refractive surgery [5].

The majority of patients undergoing cataract surgery can be asymptomatic for dry eye, but may already present changes in the osmolarity of the tear film. It is of great importance to identify changes in the ocular surface even preoperatively, as surgery can intensify or exacerbate film dysfunction subclinical lacrimal tear, generating discomfort and symptoms for the patient. Many patients do not report symptoms until they are questioned about their presence.

In addition to inaccurate preoperative calculations, untreated Dry Eye Disease that persists can generate vision instability, fluctuation and fatigue, generating dissatisfaction for the patient and surgeon in the postoperative period. Surgeries in patients with ocular surface disease are not treated can also generate more propensity for infectious processes [6].

Data from the European Society of Cataract and Refractive Surgery Clinical Survey (ESCRS) 2018, on ocular surface diseases showed that less than half of the doctors are examining the ocular surface before cataract surgery in all its patients and about 20% are examining only when the patient presents complaints or dry eye symptoms [7]. This fact occurs even though 90% of those interviewed agreed that Mild to moderate tear film dysfunction already significantly affects preoperative keratometry. surgery and IOL calculation [7].

One factor to be taken into account is the fact that the patient receives a diagnosis of tear film dysfunction and/or dry eye preoperatively in a more receptive manner than after the procedure performed.

The risk of Dry Eye Disease increases postoperatively due to various etiologies, which include pupil dilation, exposure to operating microscope light, type and duration anesthetic, antisepsis procedures such as the use of povidone-iodine, location of incisions, denervation of corneal nerves by incisions in the cornea, corneal epithelial damage, elevation of inflammatory markers with ocular

surface damage and loss of cell density goblets. Suction procedures such as those used in the femtolasers can increase the chance of dry eye disease [8].

Phacoemulsification modifies the function of the Meibomian glands, which can generate exacerbation of MGD in the postoperative period. Postoperative abnormalities often remain for 3 months, but can remain for up to 1 year after surgery [8].

In a study carried out by Gibbons, *et al.* in 2017, at the Bascom Palmer Eye Institute, it was shown that in patients undergoing cataract surgery, 35% of patient dissatisfaction was related to dry eye after surgery [9].

The compromised ocular surface in addition to affecting the pre-operative calculation of the Lens Intraocular, may affect axis and magnitude estimates of toric IOLs and promote greater surgical difficulty.

There is a certain gap in the literature regarding work on management and impacts of the dry eye in the preoperative period of intraocular surgeries, with many studies found related to dry eye in the postoperative period of cataract surgery and especially surgery refractive.

Significant irregularities of the ocular surface must be corrected, so that keratometric measurements are more precise and the Intraocular Lens is chosen in the best way possible.

Possible way [10]. Conjunctiva and all layers of the cornea should be evaluated for pathologies that may change the mean keratometry or show optical aberrations.

The Duke University study, carried out in 2018, emphasizes and supports the concept of carrying out preoperative screening for ocular surface dysfunction, without taking into account counts symptoms as an important factor, as many patients with potentially significant differences in ocular surface dysfunction are asymptomatic [11].

In this study, 80% of patients undergoing cataract evaluation had objective signs of ocular surface dysfunction preoperatively and 57% of patients did not have a previous diagnosis of ocular sur-

face disease, which suggests that ocular surface dysfunctions tear film have a high prevalence and are underdiagnosed in patients when evaluating cataract surgery [11].

Dry eye was first characterized in 1995, this being the first attempt formal way of defining and classifying dry eye disease. When was Tear Film and Ocular Surface Society (TFOS), by 1995 there were about 5,000 citations of eye work dry. In 2005 there were already more than 50,000 citations. In 2007, the first Report was published of the TFOS International Dry Eye Workshop, which became widely known as TFOS DEWS, where dry eye was more formally divided into evaporative dry eye and aqueous [5].

In 2017, a workshop, held through a 2-year effort by 12 subcommittees, composed of 150 experts from 23 countries, led to the publication of the extremely important report.

TFOS International Dry Eye Workshop II (TFOS DEWS II) [5].

The President, Vice President and Organizer of TFOS DEWS II developed the qualifications for participation and responsibility of all Workshop members. A Steering Committee appointed chairs for each of the 12 individual subcommittees. Furthermore, 139 experts in their respective fields were chosen, based on their global representation on the subject, its clinical perspectives, research perspectives and multidisciplinary patients, from a much larger group of individuals who have been appointed and/or expressed written interest in participating in TFOS DEWS II [5].

The need for DEWS II was due to the large number of works produced on dry eye since the 2007 Workshop. The Steering Committee was formed by 25 members and was responsible for strategies, tactics, structures, communication methods, schedule, assessment of policies of interest and development of work objectives that would be used in the study. This committee selected subcommittee chairs and members, proposed guidelines for determining acceptable levels of evidence and documentation methods for support this evidence and considered the most appropriate journal for which publication would be targeted [5].

DEWS II aimed to update the definition, classification and diagnosis of Dry Eye Disease, in addition to carefully evaluating its etiologies, mechanisms, distribution, impacts, its approach, management and therapy [5].

The TFOS/Dry Eye Workshop II redefined the dry eye classification as a multifactorial disease of the tears and ocular surface, which results in symptoms of discomfort, visual disturbances and tear film instability, with possible damage to the ocular surface. AND accompanied by increased tear film osmolarity and surface inflammation eye piece. This was the first time that dry eye was identified as a disease that has many associated causes, and which results in signs and symptoms, in association with hyperosmolarity of the tear film and inflammation of its ocular surface [5].

TFOS DEWS II defines

“Dry eye is a multifactorial disease of the ocular surface characterized by a loss of tear film homeostasis and accompanied by ocular symptoms, in which the instability and hyperosmolarity of the tear film, inflammation and damage of the ocular surface and neurosensory abnormalities play etiological roles” [5].

The addition of the term “loss of homeostasis” clarified, based on recent evidence peer-reviewed studies that tear film hyperosmolarity and surface inflammation ocular disorders have causal etiological roles associated with neurosensory abnormalities [5].

Hyperosmolar stress is believed to be the main factor responsible for increasing in the epithelial cells of the ocular surface the release of inflammatory factors and proteases, which will give rise to the vicious circle of dry eye and this direct or diffuse hyperosmolarity leads to loss of epithelial and goblet cells. Change in cell hyperosmolarity ocular surface epithelium triggers an inflammatory cascade with cellular signaling in response to stress (MAPkinases - Mitogen-Activated Protein Kinase) and NFkB (Kappa Light Chain Nuclear Factor, enhancer of activated B cells) and which culminate in increase in inflammatory cells (Interleukin-1 α , Interleukin- β), TNF (Necrosis Factor tumor) and extracellular matrix metalloproteinases (MMP-9). MMP-9 is a protease central action to hyperosmolar stress, which has already been suggested to be measured in tears as dry eye meter and its action leads to the breakdown of the epithelial barrier, which causes occurrence of APCs and NKs, which are components of the innate immune system and which produce tissue damage. APCs migrate to lymph nodes, where they contribute to activation of CD4 T cells, which secrete interferon gamma and IL-17 and are recruited to ocular surface generating more damage to the epithelial barrier, decreasing cell density goblets [4,5].

These inflammatory mediators also decrease glyocalyx expression, component of the outer surface of the epithelium that interacts with the muco-aqueous layers of the tear film and plays an important role in ocular lubrication. It is believed that this change in the glyocalyx expression occurs associated with tear film instability evidenced by Reduced BUT and would justify the punctate keratopathy that occurs in dry eye [4,5].

The main risk factors for dry eye are: use of topical and systemic medications; previous intraocular surgery or non-surgical procedure; use of botulinum toxin; dehydration; enlarged palpebral fissure due to anomalous anatomy or surgery plastic; changes in blinking rhythm; users of electronic devices; heat exposure; cold; low humidity; air pollution; excessive evaporation; DGM; secondary to dermatoses systemic; sex; ethnicity and age; vitamin A deficiency; allergies and use of eye drops; especially antiglaucoma eye drops.

The prevalence of dry eye disease, with and without symptoms, ranges from 5 to 50%. Its prevalence based on signs alone is even more variable, reaching 75% in some cases. populations. This is due to the great variability of methodology used in the studies and the inclusion criteria used in them. For example, few studies have been carried out on young populations, despite what has been studied so far points to a lower prevalence in them [5].

It is more common in women and patients of Asian origin. The preference for Asians appears to be a risk factor; but there is no established base reason. It is known also, that the prevalence only becomes higher in women with increasing age and that this occurs due to genetic and hormonal factors, as androgens play an important role in regulation of the ocular surface and ocular annexes, and its deficiency can cause dysfunction of the lacrimal glands and also the meibomian glands, thus contributing for both the aqueous and evaporative deficiency components [5].

Dry eye can be divided into 2 groups according to its pathophysiology. The eye dryness may be due to aqueous deficiency of the tear film (DAFL) and excessive evaporation, which, for the most part, are associated with meibomian gland dysfunction.

Regardless of the type of dry eye, the vicious circle of tears ends

up heading towards a common denominator which is tear film instability, with the initial cause becoming often indistinguishable [4,5]. Aqueous deficiency of the tear film can also be subdivided into SjOgren and Non Sj SyndromeOgren. The Sj formOgren can still be subdivided into SjOprimary gren or SjOsecondary gren [4].

In Sj formOprimary gren the patient has only SjOgren and in the secondary occurs association with some systemic disease, the most common being Rheumatoid Arthritis, but also having a relevant association with Systemic Lupus Erythematosus, Polyarteritis Nodosa, Wegener's Granulomatosis and Systemic Sclerosis. The main symptoms of Sj syndrome Ogren are: dry eye; and xerostomia. Its diagnosis is made with a marker dry eye or dry mouth, such as sialometry, a marker of the immunological basis of the disease (Anti-Ro and Anti-La and salivary gland biopsy). In JS Syndrome Ogren imaging exams like USG and MRI of glands can also help with the diagnosis [4,5].

In Non-Sj formOgren tear deficiency may occur due to insufficient production tear, obstruction of the lacrimal glands, neurotrophic keratitis with reflex block sensory production, Diabetes, chemical injury or use of systemic medications. Also may occur due to congenital alacrimia (rare form), lacrimal gland ablation and dry eye associated with age, which is the main cause No SjOgren and is characterized by a decrease in drive sensory [4,5].

Dry eye is a disease that can be accompanied by symptoms of anxiety and depression, as patients are accompanied by signs and symptoms that change their routine, style and quality of life and which are little understood even by the ophthalmologist himself.

The tear film is the first and most important refractive interface of the ocular surface, as this is where the greatest variation in the refractive index occurs: air = 1, tears = 1.34, cornea = 1.38). Its irregularity can generate inaccurate keratometric measurements in the preoperative period, in addition to corneal optical aberrations.

The tear film is divided into 3 layers: lipid; watery; and mucosa. The dysfunctions of Meibomius glands such as meibomitis cause changes in the lipid layer, causing greater evaporation and potentially generating evaporative dry eye. There is an association of blepharitis, especially posterior ones, with changes in the meibomian glands, due to large release of exotoxins that generate

inflammation of the ocular surface and irritation around of the meibomian glands.

There are several studies that report an association of neurosensory factors associated with dry eye disease, and which suggest that there is underreporting of discomfort by these patients, as this group has greater pain tolerance [11]. This reinforces the theory that most of dry eye sufferers are asymptomatic.

Dry eye is characterized by hyperosmolarity and this hyperosmolarity is the main responsible for the mechanism for inducing inflammation of the ocular surface, presenting, therefore, hyperosmolarity correlates with the severity of tear film dysfunction. In eyes with a healthy tear film, a minimum power difference of 0.1 may occur D between blinks. In eyes with unstable tear film, a higher variation may occur at 1.0 D, which can generate an error of the same magnitude when calculating the IOL power [12].

Tear film dysfunction also affects tear film accuracy and reproducibility keratometry. According to the work "Optimization of the ocular surface for biometric measurements accurate", presented at ESCRS 2019, in Paris, by Cochener-Lamard the eyes with hyperosmolarity are associated with large differences in K cylinder measurements (17% have difference of 1.0 D), and changes in IOL power, (10% had changes in K greater than 0.5 D) [12]. These changes in K can have a significant impact on the actual diagnosis of the astigmatism and its necessary treatment, especially in multifocal and toric lenses.

Dry eye treatment should be performed before surgery, ideally before surgery. Biometry, and can be performed clinically or surgically, in very severe cases. Treatment must be individualized and is staggered. In the clinical form, it should include education of the patient in relation to their pathology, identification and treatment of environmental conditions, behavioral conditions and conditions such as the use of contact lenses, guidance on the importance of flashing, guidance on using electronic devices more appropriately (placing the ceiling of the computer at a lower level to reduce the palpebral fissure and reduce evaporation lacrimal), avoid trigger factors such as dust, air conditioning, cigarette smoke and advise adequate oral hydration. Patients with blepharitis should be advised to practice correct eyelash hygiene. Commercial substances

or those manipulated with tea tree oil are more effective than use of children's shampoo.

The use of artificial tear substitutes is recommended, with preference for preservative-free lubricants, which is the first line treatment. Night gels can be indicated mainly in those patients with complaints in the morning, as patients stop blinking at night during REM sleep. Patients with lagophthalmos can require night occluders.

Oral supplementation with polyunsaturated essential fatty acids, such as omega 3 (richly present in linseed oil and fish oil) help combat inflammatory process proving to be effective in practice, as they act by reducing markers inflammatory processes, but their process has not yet been completely elucidated with results varied as in several studies reported in DEWS. It is known that they have great potential of help in treatment, but it is not the main determinant in treatment as there is a individual variation in the metabolism of these fatty acids and despite recent developments, poorly tolerated by many patients. It has systemic contraindications: fibrillation atrial; bleeding disorders; and liver diseases.

The use of therapeutic soft lenses can also be used in non-keratitis. infectious diseases, such as filamentary keratitis, where after removing filaments in a Manually, a therapeutic contact lens is used for better patient comfort [4,5].

The exchange of soft lenses for scleral lenses can also be without proposals, as the sclerals maintain better corneal lubrication [4,5].

In more serious cases, autologous serum can be used, which is rich in growth, but it is difficult to obtain for use in Brazil [4,5].

Blood products are indicated in dry eyes due to aqueous deficiency that is difficult to treat and that cannot be resolved with eye drops. No preservatives.

Stimulation of tear production can be used in aqueous deficiency with the use of systemic secretagogues such as pilocarpine or sevimeline and topical production stimulators of mucin. The treatment of the evaporative component can be done by guidance, treatment of Meibomius gland dysfunction, use of special glasses

and lenses, humidifiers of air, occlusion of tear points, and use of high intensity pulsed light [4,5].

Occlusion of tear punctums with plugs is efficient in aqueous dry eye, but its Use is controversial in evaporative dry eye [4,5]. The most commonly used are point occluders. collagen tear pads that have an average lifespan of 1 to 16 weeks. Non-absorbable ones are generally made of silicone and are a very interesting tool in very symptomatic after refractive surgery. In this case, they are removed 6 months after surgery. corneal when the innervation has already been reestablished [4,5]. The plugs only have an indication after control of inflammation. In moderate and severe cases anti-inflammatory treatment may be done through the use of corticosteroids or immunomodulators such as cyclosporine or tacrolimus and aim to reduce symptoms. Topical corticosteroids should be used for a short period of time period of time with rapid regression and act by inhibiting MAPK, cytokines and metalloproteinases [4,5].

Studies suggest that starting fluorometholone before topical cyclosporine promotes a faster improvement in the Schirmer Test, dye test and symptoms when compared to the use of cyclosporine alone. After these first weeks, gradual weaning of corticosteroids. This association promotes better adherence to treatment.

Cyclosporine 0.05% or Restasis (immunomodulator with anti-inflammatory action) is a drug in an oily vehicle, without preservatives and which acts by inhibiting calcineurin and reducing the production of IL-2 and T lymphocytes. Its onset of action is later, requiring a period of treatment of at least 6 months. Tacrolimus 0.03% and 0.01% is an option for patients who do not obtained a good response or did not tolerate cyclosporine due to its greater potency, however have low acceptance 4.5 being better tolerated in those patients with Rosacea and blepharitis and with better acceptance at a reduced concentration (0.01% or 0.02%).

Surgical treatment in more extreme cases may involve tarsorrhaphy or bone transplantation.

Salivary glands [4,5]. Debridement of the eyelid margin can also be performed (Line Marx) with the aim of releasing the orifices of the ducts obstructed by the process of hyperkeratinization.

There is a consensus that there is a need for routine preopera-

tive assessment to assessment of the risk of developing or worsening dry eye disease in all patients. It is believed that in most cases, around 80%, only 2 minutes are needed estimated to evaluate the ocular surface and only 5 minutes in patients at higher risk of Dry Eye disease or who have symptoms.

Tests for diagnosing dry eye have sensitivity and specificity highly dependent on the inclusion criteria for DED, study population and severity of the disease group.

In the United States of America, it is recommended to carry out a questionnaire associated with carrying out an objective test for all patients in the preoperative period of surgery of cataracts.

These objective tests include measuring tear film osmolarity and/or metalloproteinase dosage.

Research evidence suggests that the best form of screening would be to use questionnaires and analysis of risk factors of the patient’s past history accompanied by a very detailed anterior bio-microscopy. According to DEWS-II, eye is diagnosed dry eye, if dry eye is suspected, that is, the patient presents anamnesis, risk factors for dry eye and a positive result for screening questionnaires such as: 5-item Dry Eye - DEQ-5 (Figure 2); or the Ocular Surface Disease Index (OSDI) (Figure 3) associated with an objective test, with the 3 standardized tests being staining by 1% fluorescein tear osmolarity test or Tear film break-up time (Figure 1).

Source: “Figure 5. DED diagnostic test battery. The screening

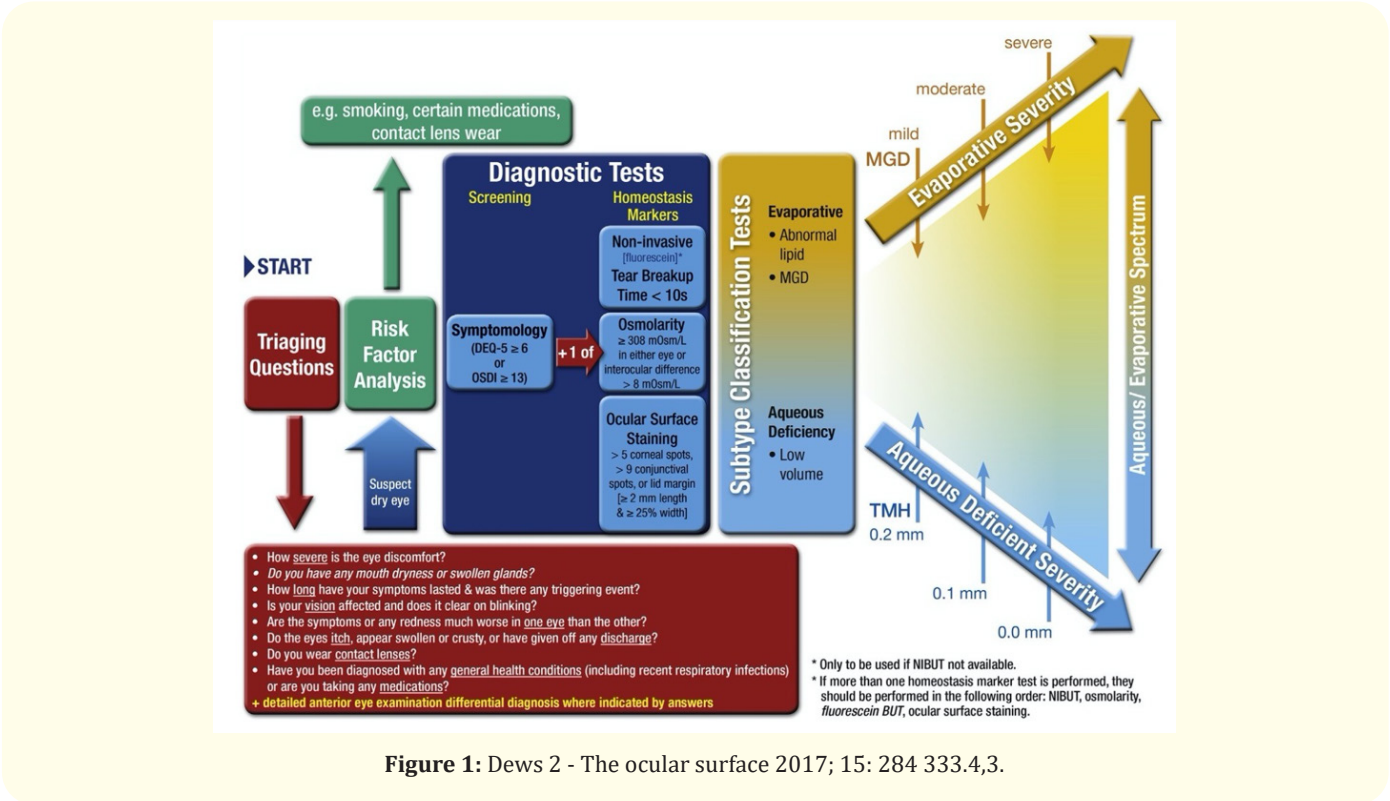


Figure 1: Dews 2 - The ocular surface 2017; 15: 284 333.4,3.

DEQ-5 or OSDI confirms that a patient might have DED and triggers the diagnostic tests of non-invasive breakup time, osmolarity [measured prior to breakup time if FBUT used] and ocular surface staining with fluorescein and lissamine green (observing the cornea, conjunctiva and eyelid margin). On initial diagnosis, it is important to exclude conditions that can mimic DED with the aid

of the triaging questions (Section 9) and to assess the risk factors which may inform management options [380]. Marked symptoms in the absence of clinically observable signs suggest that there may be an element of neuropathic pain. DED is a subset of OSD; signs alone may still warrant management to prevent DED manifestation and to optimize the optical corneal surface such as prior to refractive surgery or contact lens wear [4]. MGD [483] lipid thickness/

dynamics and tear volume assessment and their severity inform the subtype classification of DED (as predominantly evaporative or predominantly aqueous deficient) which helps inform the management of DED. MILD MGD is indicated by a secretion grade 4-7, an expressibility grade of 1 and an amorphous/color fringes lipid pattern. MODERATE MGD is indicated by meibomian gland orifice plugging, lid margin vascularity, a secretion grade 8-12, an expressibility grade of 2 and a meshwork or wave (flow) lipid pattern. SEVERE MGD is indicated by lid margin meibomian gland orifice drop-out or displacement, a secretion grid! 13, an expressibility grade of 3 and an absent, globular or abnormal colored fringes lipid pattern. Videos of these diagnostic and sub-classification techniques are available on the TFOS website. Sjogren’s syndrome should be suspected if the DEQ-5 score is > 12. Further testing will help identify treatment mechanisms worthy of targeting but are beyond the scope of this Diagnostic Methodology report” 4.3.

The DEQ-5 assesses variables such as: eye discomfort; dry eye sensation; and quantify these symptoms in frequency and intensity (Figure 1). 4.3.

The Ocular Surface Disease Index (OSDI) consists of 12 questions about ocular signals and environmental triggers and uses markers of ocular homeostasis (BUT) and tests with surface dyes. 4.3 It is the most used and has been validated in Brazil. Classify patients in a numerical stratification through the assessment of symptoms as described below:

- Normal: 12
- Light: 13-22
- Moderate: 23-32
- Severe: >33

Other tests such as meibography, lipid layer interferometry, evaporation of the tear film, can help determine the predominant type of dry eye and better guide the most appropriate therapy for each case. Often the failure of the treatment lies in determining the underlying cause of dry eye, although most cases are formed by the two components [5].

Imaging exams allow documentation and accelerate diagnosis and are becoming increasingly included in dry eye treatment in recent years.

Interferometry does not yet have a well-established diagnostic

DEQ 5

1. Questions about EYE DISCOMFORT:

a. During a typical day in the past month, how often did your eyes feel discomfort?

0 ☐ Never

1 ☐ Rarely

2 ☐ Sometimes

3 ☐ Frequently

4 ☐ Constantly

b. When your eyes felt discomfort, how intense was this feeling of discomfort at the end of the day, within two hours of going to bed?

Never have it

Not at all intense

Very intense

0 ☐

1 ☐

2 ☐

3 ☐

4 ☐

5 ☐

2. Questions about EYE DRYNESS:

a. During a typical day in the past month, how often did your eyes feel dry?

0 ☐ Never

1 ☐ Rarely

2 ☐ Sometimes

3 ☐ Frequently

4 ☐ Constantly

b. When your eyes felt dry, how intense was this feeling of dryness at the end of the day, within two hours of going to bed?

Never have it

Not at all intense

Very intense

0 ☐

1 ☐

2 ☐

3 ☐

4 ☐

5 ☐

3. Question about WATERY EYES:

During a typical day in the past month, how often did your eyes look or feel excessively watery?

0 ☐ Never

1 ☐ Rarely

2 ☐ Sometimes

3 ☐ Frequently

4 ☐ Constantly

Score:

1a

+

1b

+

2a

+

2b

+

3

=

Total

+

+

+

=

Figure 2: Dews II - The ocular surface 2017;15: 284 333.4,3. Source: Figure. Five-item Dry Eye Questionnaire (DEQ-5) reproduced with permission (Indiana University) [37]. 4.3.

contribution. A meibography is carried out using infrared, where it is possible to demonstrate the quantity and quality of the meibomian glands, always being evaluated in conjunction with other clinical parameters. Idra and Keratograph 5 M can be of great importance in dry eye documentation. Through devices like the OCULUS-Keratograph 5M you can If non-invasive tear break-up time (NITBUT) is performed, hyperemia scores conjunctival, tear meniscus height (TMH) and meibography It is believed that image will present greater significance in the next DEWS update.

There is no objective test for the diagnosis of dry eye, and the diagnosis is made through the association of tear surface evaluation tests associated with anamnesis, clinical history and adequate physical examination [4].

Slit lamp evaluation is the most useful exam to diagnose chang-

Have you experienced any of the following during **the last week**:

	All of the time	Most of the time	Half of the time	Some of the time	None of the time
1. Eyes that are sensitive to light?	<input type="checkbox"/>	<input type="checkbox"/>	<input type="checkbox"/>	<input type="checkbox"/>	<input type="checkbox"/>
2. Eyes that feel gritty?	<input type="checkbox"/>	<input type="checkbox"/>	<input type="checkbox"/>	<input type="checkbox"/>	<input type="checkbox"/>
3. Painful or sore eyes?	<input type="checkbox"/>	<input type="checkbox"/>	<input type="checkbox"/>	<input type="checkbox"/>	<input type="checkbox"/>
4. Blurred vision?	<input type="checkbox"/>	<input type="checkbox"/>	<input type="checkbox"/>	<input type="checkbox"/>	<input type="checkbox"/>
5. Poor vision?	<input type="checkbox"/>	<input type="checkbox"/>	<input type="checkbox"/>	<input type="checkbox"/>	<input type="checkbox"/>

Have problems with your eyes limited you in performing any of the following during **the last week**:

	All of the time	Most of the time	Half of the time	Some of the time	None of the time	N/A
6. Reading?	<input type="checkbox"/>	<input type="checkbox"/>	<input type="checkbox"/>	<input type="checkbox"/>	<input type="checkbox"/>	<input type="checkbox"/>
7. Driving at night?	<input type="checkbox"/>	<input type="checkbox"/>	<input type="checkbox"/>	<input type="checkbox"/>	<input type="checkbox"/>	<input type="checkbox"/>
8. Working with a computer or bank machine (ATM)?	<input type="checkbox"/>	<input type="checkbox"/>	<input type="checkbox"/>	<input type="checkbox"/>	<input type="checkbox"/>	<input type="checkbox"/>
9. Watching TV?	<input type="checkbox"/>	<input type="checkbox"/>	<input type="checkbox"/>	<input type="checkbox"/>	<input type="checkbox"/>	<input type="checkbox"/>

Have your eyes felt uncomfortable in any of the following situations during **the last week**:

	All of the time	Most of the time	Half of the time	Some of the time	None of the time	N/A
10. Windy conditions?	<input type="checkbox"/>	<input type="checkbox"/>	<input type="checkbox"/>	<input type="checkbox"/>	<input type="checkbox"/>	<input type="checkbox"/>
11. Places or areas with low humidity (very dry)?	<input type="checkbox"/>	<input type="checkbox"/>	<input type="checkbox"/>	<input type="checkbox"/>	<input type="checkbox"/>	<input type="checkbox"/>
12. Areas that are air conditioned?	<input type="checkbox"/>	<input type="checkbox"/>	<input type="checkbox"/>	<input type="checkbox"/>	<input type="checkbox"/>	<input type="checkbox"/>

Scoring Instructions

Item scoring

The total OSDI score is calculated based on the following formula:

$$OSDI = \frac{(\text{sum of severity for all questions answered}) \times (100)}{(\text{total \# of questions answered}) \times (4)}$$

where the severity was graded on a scale of

0 = none of the time,

1 = some of the time,

2 = half of the time,

3 = most of the time,

4 = all of the time.

Interpretation

A score of 100 corresponds to complete disability (a response of "all of the time" to all questions answered), while a score of 0 corresponds to no disability (a response of "none of the time" to all questions answered). Therefore, change from baseline of -12.5 corresponds to an improvement by at least one category in half of the questions answered.

Subscale Scoring

Subscales scores are computed similarly with only the questions from each subscale used to generate its own score. Therefore, any subscales analyzed separately would also have a maximum possible score of 100.

The three subscales (vision-related function, ocular symptoms and environmental triggers) are broken out as follows:

Subscale	Questions
Vision-Related Function	4, 5, 6, 7, 8, 9
Ocular Symptoms	1, 2, 3
Environmental Triggers	10, 11, 12

Figure 3: Dews II - The ocular surface 2017; 15: 284 333.4,3.

Source: "Figure. Ocular Surface Disease Index (OSDI©) Version 1 Copyright 1995 Allergan Inc. Irvine, CA, USA. All rights reserved". 4.3.

es in ocular surface. Biomicroscopy shows a reduction or absence of the tear meniscus, conjunctival hyperemia, meibomitis, debris on the corneal surface and even punctate keratitis and/or filamentary. It is important to carefully evaluate the corneal epithelium, as the glycocalyx is responsible by the adhesion of the tear to the surface.

Eyelids should always be evaluated in relation to the characteristics of their edges, eyelash positioning, meibomian gland orifices and presence of flaccidity. Presence of hyperemia, scaling, crusts, collarettes around eyelashes, thickening or eyelid margin irregularities suggest the diagnosis of blepharitis. Eyelid occlusion, presence of lesions, frequency of blinking rhythm and Bell's phenomenon should be tested.

In some cases, osmolarity testing can identify patients with susceptibility to develop the syndrome after surgery, as hyperosmolarity is related to decrease in goblet cells. This test is performed by collecting samples from the meniscus lacrimal. A state of hyperosmolarity can be considered when the test is higher

or equal to 308 mOsm in each eye or the difference between the eyes is greater than 8 mOsm. 5 Um dry eye with an osmolarity greater than or equal to 308 mOsm is considered an initial dry eye and a dry eye with an osmolarity greater than or equal to 316 mOsm is considered a dry eye advanced. In the works described there is also an evaluation of the protein profile of the tear film, where a reduction in the concentration of lactoferrin, lysozyme and immunoglobulins is evident. There are also the tear film crystallization test where tear samples are evaluated with light polarized forming crystals that have a "fern" appearance when normal and According to the appearance of these crystals, the degree of tear film deficiency is assessed. Those The tests described are not routinely used in ophthalmology clinics.

The Asia Dry Eye Society recommends treating dry eye when it occurs.

Association of tear film instability and the presence of signs or symptoms of dry eye [13].

The tear film breakup time or "Break Up Time" is a clinical test used to assess the evaporative component of dry eye and may be reduced in these cases indicating deficiency in the lipid layer (MGD) and/or mucin. The results of the Test Schirmer or vital

staining of the ocular surface are not mandatory requirements for dry eye diagnosis [4].

BUT is assessed by instilling 1 drop of 1% sodium fluorescein (with preferably, without preservatives) in the bottom of the bag with subsequent observation of the film pre-corneal tear solution, in a slit lamp, without prior use of any other eye drops or eyelid manipulation. After instillation, the patient should be asked to blink for several times. The patient is then instructed to keep their eyes open without blinking and the time is observed of rupture of this film through the use of cobalt blue filter [4]. The interval between the last complete blink and first appearance of any disturbance, repeating the test 3 times and averaging the measurements [4].

BUT of 10 or more seconds is considered normal 3 and a value lower than that can already indicate tear film instability [4]. It is a highly sensitive test that can be altered by other pathologies such as pterygia, pingueculae and calcium deposits. After observation of BUT, the presence of fluorescein must be taken advantage of to evaluate how the color of the ocular surface and whether there is the presence of epithelial erosions [4].

1% fluorescein stains cells in more advanced suffering, cells that already lost their intercellular adhesions, showing areas of absence of epithelial cells. A lissamine green and rose bengal stain devitalized cells on the ocular surface, staining more the conjunctiva than the cornea and mainly evaluate the conjunctiva and palpebral margin, marking plus loss of the glycocalyx. The assessment should always be done between 1 and 4 minutes after instillation of eye drops. Green lissamine is more pleasant, generating less eye discomfort for patients. Patients are stratified according to the Van Bijsterveld Score. All 3 dyes Vital vitals can help in the diagnosis of punctate keratitis, indicating, therefore, dysfunction of the tear film [4].

The Schirmer Test can be performed with and without local anesthetic and is used to assessment of the production and volume of the aqueous component of tears [4]. Can be divided into type I, II and basal tear secretion test. In type I, no anesthetic is used and it is classically requested for evaluation of Sjögren's Syndrome. It is the most used and most valid among ophthalmologists. It is normal for the tape to impregnate more than 10 mm. Lesser impregnation that 5 mm defines severe dry eye. Type II is performed with stimulation

of the nasal mucosa and the basal tear secretion test is used with anesthetic.

It is necessary to investigate comorbidities and medical treatment of other diseases. Patients people with JS SyndromeOgren often have severe dry eye and film instability lacrimal, as well as patients with other autoimmune diseases. There is association with processes inflammatory and infiltrative diseases such as: Sarcoidosis; Lymphomas; Graft x host disease; radiotherapy; cicatricial conjunctivitis; and sensory block (both afferent and efferent). O use of drugs such as antidepressants, serotonin reuptake inhibitors, anxiolytics, anti-histamines, beta-blockers, antispasmodics, diuretics, use of NSAIDs orally eye drops with benzalkonium chloride can induce dry eye and are risk factors that are modifiable factors to develop the syndrome. Assessment of the patient's medical history as well can help and raise a warning signal [4,5].

Evaporative dry eye may be associated with changes such as: MGD; dysfunction of blink; changes in the eyelid opening; vitamin A deficiency; ocular surface diseases such as ocular allergy and iatrogenic causes such as dry eye associated with contact lenses and previous eye surgeries.5Patients undergoing fistulizing glaucoma surgeries, blepharoplasties, facectomies and vitreoretinal surgeries often present with dysfunction of the significant tear film. Diabetes patients undergoing surgery vitreoretinal cells usually have epithelium with worse adherence to tears. Another factor is trauma limbal, mainly related to retinopexies.

Meibomius Gland Dysfunction is the main cause of evaporative dry eye 4 and is characterized by being a chronic disease that must be treated in all patients who will undergo cataract surgery due to the risk of endophthalmitis.14The glands of meibomius are holocrine glands. On average, an adult individual has 30 to 50 glands in the upper eyelid and 20 to 40 in the lower eyelid. Clinical signs of your dysfunction may include visualization of gray line, telangiectasias and practically absent glands due to such an obstruction [4].

Many factors are responsible for MGD. The most recent research includes a combination of genetic factors, environmental factors and dietary factors.

In addition to the known association of MGD with Acne Rosacea and Seborrheic Dermatitis, there are studies that report an as-

sociation between MGD and dyslipidemia.4.5It can occur due to a state of high lipid release such as Seborrheic Dermatitis and Ocular Rosacea, where there is a large release of fat with expression from the glands or due to a state of low lipid release or Obstructive MGD, which is the most common cause of MGD [4,5].

Obstructive MGD can be of the cicatricial type when there is a narrowing of the terminal ducts and displacement of their orifices from their original portion to a portion with most posterior location of the eyelid margin. In this case it can be primary, or secondary to diseases that affect the conjunctiva such as Trachoma and Pemphigoid.

Obstructive MGD may also be non-scarring, where a process of keratinization with formation of a keratotic plaque associated with thickening of the meibo. There is association of obstructive MGD with atopic dermatitis and psoriasis. The use of isotretinoin via Oral treatment for acne can also generate atrophy of the gland [4,5].

Treatment is based on ruling out any primary infectious process, using warm compresses (ideally around 40 degrees for 5 minutes, changing every 2 minutes to maintain temperature, local hygiene, gland expression, oral omega-3 supplementation, non-steroidal topical preparations, steroids and antibiotics systemic drugs, such as Doxycillin, Minocycline and Azithromycin, presenting several regimens of dose in the literature. Tear film dysfunctions and MGD should be treated at least 2 weeks [4,5].

Tetracyclines reduce inflammation due to a decrease in the activity of the matrix of metalloproteinases, production of IL-1, TNF and collagenases. However, this conventional therapy for dry eye treatment has limited effectiveness in moderate to advanced disease due to the difficulty in adhering to treatment for many patients, present side effects, development of bacterial resistance, cost, accessibility, low level of evidence and need for continuous treatment for a long period. Intraductal probing helps in improvement of ductal permeability, release of secretion and greater access to medications topical treatment of the glands, but their long-term efficacy has not yet been established [14].

A reduction in dry eye symptoms with the use of pulsed light was observed incidentally by Dr. Rolando Toyos in patients who were

receiving treatment for Acne Rosacea for over a decade [14,15]. Intense pulsed light therapy in the area periocular in dermatology in the treatment of excessive periorbital pigmentation and rosacea already has been carried out for a long time in the medical field, showing good results [14], being approved for dermatological use in 1995 by the FDA.

Intense pulsed light has several applications in dermatology, including use in vascular lesions, pigmented lesions, acne treatment, hair removal and rejuvenation.

Later, other authors confirmed these initial findings and documented an improvement in the number of functional meibomian glands and a reduction in inflammatory markers of the ocular surface [14,17-19]. This is due to the improvement of the layer lipid and increased expressibility of the gland.

Studies on the Safety and Efficacy of Intense Pulsed Light Treatment for MGD suggest that a series of two or more intense pulsed light treatments can improve patient symptomatology and tear film characteristics, including BUT.

It is believed that the use of pulsed light improves the symptoms of MGD by several mechanisms and that promotes a cumulative action and this improvement in symptoms would be greater by neuromodulatory effect. In ophthalmology, the vascular effect would be much more localized than in dermatology. The anti-inflammatory effect would depend on the light spectrum and could be a probable reason for the improvement in symptoms. The main advantage of pulsed light would be the control of signs and symptoms of evaporative dry eye with fewer medications and in those patients who they are unable to carry out the treatment in the best possible way.

The infrared light would heat the skin internally up to 50°C, liquefying the contents lipids more efficiently than using warm compresses [14].

Pulsed light is a system made up of xenon lamps. It's a polychromatic light with broad spectrum, absorbed by different chromophores, non-coherent, divergent, with wavelength spectrum from 500 - 1200 nm [14]. The impulses are released in the form sequence of pulses with precisely determined distance, energy and spectrum to stimulate the Meibomius glands to regain their

normal function. Its basic principle involves the thermal relaxation time, which is the time necessary for 50% of the energy dissipate without affecting adjacent normal tissue.

The thermal relaxation time involves selective photothermolysis, in which light in contact with tissue is preferentially reabsorbed by a chromophore and converted into heat [14]. The skin has target chromophores, such as melanin and oxyhemoglobin. The pulsed light can reach oxyhemoglobin (red vessels) and deoxyhemoglobin (blue vessels). For restrict its use, as it is not selective, filters are used to restrict the ranges of wave-length.

Yellow light wavelengths are able to pass through the layers of the skin without excessive absorption of light energy by melanin. The absorption of yellow light by Oxyhemoglobin, which has an absorption peak at 578 nm, generates conversion of light into energy thermal, leading to coagulation and ablation of superficial blood vessels generating a process local thrombosis, with closure of the telangiectasias of the eyelid margins [14,19]. The pulsed light also reduces the bacterial load and Demodex species by photocoagulation, decreasing the amount of exotoxins in the tear film and, consequently, the inflammatory response to these exotoxins [14,19].

Demodex is believed to have an important role in chronic posterior blepharitis, mainly Folliculorum, which is associated with meibomitis. Pulsed light also would promote ocular collagen remodeling, which could lead to better function of the meibomius glands and improvement in blinking.

A recent study demonstrated that pulsed light decreases interleukins 17 and 6 in ocular surface after a series of 3 consecutive treatments spaced 4 weeks apart between them.

It has also been demonstrated that intense pulsed light treatment targets cytochrome oxidases in mitochondria, generating strong modification of mitochondrial activity in meibomian glands, which can initiate a photo biomodulation cycle, which can generate more energy and begin the cell repair and healing process by stimulating the glands to function more effectively [14].

Close attention should be paid to patients with melasma, as there are reports of it worsening with the use of pulsed light. There are also reports of damage to tooth enamel and this is why it is rec-

ommended the associated use of a protector or moist gauze soaked in the oral region. There are case reports of retinal burn and iris atrophy in patients who did not use protective glasses during shots.

Recent study, published in 2017, by Spanish Society of Ophthalmology, concluded that treatment with high-intensity pulsed light can be very useful in dry eye evaporative agent produced by DGM, but it is not very effective when related to isolated deficiency of the aqueous or mucinous component. In this study, 72 eyes were evaluated, 36 had dry eye disease and 60 had undergone surgery previous procedures, including phacoemulsification and refractive surgeries and underwent 4 sessions of pulsed light every 15 days.

According to this study, patients eligible for pulsed light must have phototype I, II and III of the skin, as darker skins (phototype IV) have a greater relative propensity to side effects, such as loss of pigmentation [20]. This study was based on information a 1988 editorial produced by Fitzpatrick [21].

This study showed an increase in TBUT in 54.17% of patients, although only 29.17% were longer than 3 seconds, but 51% of patients were satisfied with the treatment. It was also evidenced that patients undergoing refractive surgery with the microkeratome or femtosecond did not show significant improvements, as in these patients tear dysfunction occurs due to excimer laser-induced stromal ablation [20].

Second Research Paper "Randomised double-masked placebo-controlled trial of the cumulative treatment efficacy profile of intense pulsed light therapy for meibomian gland dysfunction" authored by Jennifer P. Craig, *et al.* published in The Ocular Surface-Journal in April 2020, Pulsed Light therapy showed improvements in dry eye symptoms, improvement of the lipid layer of the tear film. The results also showed greater clinical efficacy with application of 5 flashes during each treatment when compared to 4 flashes and suggested that an initial course of 4 treatments would be necessary to allow establishment of sustained cumulative therapeutic effects, before evaluating efficacy general treatment [22].

Due to these benefits, there has been increasing use of intense pulsed light in treatment of evaporative dry eye, mainly in its moderate and severe forms.

The clinical and surgical treatment of patients with dry eye before surgery cataract is beneficial and essential in the preoperative period of cataract surgery.

Conclusion

Assessment of homeostasis or identification of ocular surface changes prior to Performing biometrics in the preoperative period of cataract surgery is of fundamental importance for understanding the impact of these changes, which influence the decision more assertive when choosing intraocular lenses. Such analysis allows for early identification and the treatment of ocular surface diseases in their different classification levels and helps in the best choice of intraocular lenses, generating greater precision in the choice of lenses and lower chances of refractive errors and residual ametropia.

Bibliography

1. Renato Ambrósio Jr., *et al.* "Wavefront and Topography, Tomography and Corneal Biomechanics: propaedeutics complementary in refractive surgery".
2. Polisuk Paulo - Topography of the Cornea: clinical atlas / Paulo Polisuk. - 4th edition -Rio de Janeiro: Medical Culture, (2015).
3. "External Eye and Cornea Diseases". Brazilian Council of Ophthalmology; coordinator: Milton Ruiz Alves; editors Ana Luisa Hoffing Lima, Maria Cristina Nishiwaki Dantas, Minton Ruiz Alves. -4 ed. Rio de Janeiro; Cultura Medica (2016).
4. Stapleton F., *et al.* "TFOS DEWS II Epidemiology Report". *The Ocular Surface* 15 (2017): 334-365.
5. Lemp M., *et al.* "Distribution of aqueous-deficient and evaporative dry eye in a clinic-based patient cohort: a retrospective study". *Cornea* 31.5 (2012): 472-478.
6. Lemp M., *et al.* "Distribution of aqueous-deficient and evaporative dry eye in a clinic-based patient cohort: a retrospective study". *Cornea* 31.5 (2012): 472-478.
7. Cochener B., *et al.* "Prevalence of meibomian gland dysfunction at the time of cataract surgery". *Journal of Cataract and Refractive Surgery* 44 (2018): 144-148.
8. SCRS. "Clinical Survey Data: ocular surface" (2018).

9. Marco Antonio Del Rey, Walter Nose Catarata, Catarata: Official Theme of XXXVIII Brazilian Congress of Ophthalmology: 2015, 1 ed- Rio de Janeiro: Medical Culture (2015): 38.
10. Sullivan BD., *et al.* "An objective approach to dry eye disease severity". *Investigative Ophthalmology and Visual Science* 51 (2011): 6125-6130.
11. Tomlinson A., *et al.* "Tear film osmolarity: determination of a referent for dry eye diagnosis". *Investigative Ophthalmology and Visual Science* 47 (2006): 4309-4315.
12. Cochener-Lamard. "Optimization of the ocular surface for accurate biometric measurements". Presented at ESCRS 2019, Paris, France and Filomena Ribeiro MD, The importance of treating OSD in cataract refractive practice. EUROTİMES (2019).
13. Labetoulle M., *et al.* "Management of dry eye disease to optimize cataract surgery outcomes: Two tables for a daily clinical practice". *Journal Français d'Ophtalmologie* 42 (2019): 907.
14. Gibbons A., *et al.* "Causes and correction of dissatisfaction after implantation of presbyopia-correcting intraocular lenses". *Clinical Ophthalmology* 10 (2016): 1965-1970.
15. Preeya K Gupta., *et al.* "Prevalence of ocular surface dysfunction in patients presenting for cataract surgery evaluation" (2018).
16. Tsubota K., *et al.* "New perspectives on dry eye definition and diagnosis: a consensus report by the Asia Dry Eye Society". *The Ocular Surface* 15 (2017): 65-76.
17. Rolando Toyos., *et al.* "Evaluation of the Safety and Efficacy of Intense Pulsed Light Treatment With Meibomian Gland Expression of the Upper Eyelids for Dry Eye Disease". *Photobiomodulation, Photomedicine, and Laser Surgery* 37.9 (2019): 527-531.
18. Julie M Albietz., *et al.* "Intense pulsed light treatment and meibomian gland expression for moderate to advanced meibomian gland dysfunction". *Clinical and Experimental Optometry* 101.1 (2018): 23-33.
19. Julie M Albietz., *et al.* "Intense pulsed light treatment and meibomian gland expression for moderate to advanced meibomian gland dysfunction". *Clinical and Experimental Optometry* 101.1 (2018): 23-33.
20. Dell SJ., *et al.* "Prospective evaluation of intense pulsed light and Meibomian gland expression efficacy on relieving signs and symptoms of dry eye disease due to Meibomian gland dysfunction". *Clinical Ophthalmology* 11 (2017): 817-827.
21. Vegunta S., *et al.* "Combination therapy of in-tense pulsed light therapy and Meibomian gland expressions (IPL/MGX) can improve dry eye symptoms and Meibomian gland function in patients with refractory dry eye: a retrospective analysis". *Cornea* 35 (2016): 318-322.
22. Vora GK and Gupta PK. "Intense pulsed light therapy for the treatment of evaporative dry eye disease". *Current Opinion on Ophthalmology* 26 (2015): 314-318.