

## A Comparative Study between Sutureless, Glue-less Conjunctival Autograft vs Sutured Limbal Conjunctival Autograft for Primary Pterygium

Mandeep Singh Rai<sup>1</sup>, Neenu Kalra<sup>2</sup>, Anand Aggarwal<sup>1\*</sup>, Rajinder Khalsa<sup>1</sup>, Divjot Kaur<sup>1</sup>, Indu Khosa<sup>1</sup>, Ravneet Kaur<sup>1</sup> and Surmila Meena<sup>1</sup>

<sup>1</sup>Department of Ophthalmology, Government Medical College Patiala, Punjab, India

<sup>2</sup>Director, Kalra Eye and Maternity Hospital, Yamunanagar, Haryana, India

**\*Corresponding Author:** Anand Aggarwal, Cornea, Glaucoma and Refractive Surgery Services, Department of Ophthalmology, Government Medical College Patiala, Punjab, India.

**DOI:** 10.31080/ASOP.2022.05.0480

**Received:** February 25, 2022

**Published:** March 10, 2022

© All rights are reserved by Anand Aggarwal, et al.

### Abstract

**Purpose:** To compare and evaluate efficacy of two surgical techniques for management of primary pterygium in terms of post-operative signs, symptoms and complications.

**Design:** This was a comparative, prospective, randomized, open labelled parallel study.

**Setting:** Department of Ophthalmology, Government Medical College, Patiala, Punjab.

**Methods:** The study included 60 patients with primary pterygium. The mean age was  $42 \pm 10$  years (range 22-62 years). Simple excision under local anaesthesia was performed followed by closure of the bare sclera by suture less and glue free conjunctival autograft in 30 patients (Group I), versus conventional method of a sutured conjunctival autograft in 30 patients (Group II).

**Results:** At Visit 1, 6 patients (20%) of Group I had Graft edema in comparison to 5 patients (16.67%) in Group II. Subcutaneous haemorrhage was noted in 6 (20%) patients in both the groups. Graft retraction was noticed in 4 patients (13.33%) in Group I and in 2 patients (6.66%) in Group II. Graft dislodgement was observed in 1 patient (3.33%) in Group I.

One (3.33%) case of recurrence was reported at 6 months in Group I whereas 2 (6.67%) cases were reported in Group II. One case of Granuloma was reported in Group II.

There were significantly lower post-operative signs and symptoms in group I as compared to group II in the first post-operative week and the difference between the two groups was statistically significant (p value < 0.05) at visit 1 and visit 2. The satisfaction survey revealed higher overall satisfaction score for group I as compared to group II.

**Conclusion:** Sutureless technique may be considered as a viable alternative to sutured technique in terms of surgical outcomes. It scores better in terms of post-operative symptoms when compared to sutures.

**Keywords:** Pterygium Surgery; Sutureless Glue Free Conjunctival Autograft; Conjunctival Autograft

### Introduction

Pterygium is a benign wing shaped fibro vascular, sub epithelial, bulbar conjunctival growth of degenerative tissue over the limbus onto the cornea [1,2]. It is more common on the nasal hori-

zontal side. Depending on the population studies, the prevalence of pterygium lies within the range of 1% to more than 30% with the median at about 10% [3]. It is prevalent in countries closer to the equator especially the tropics, the area being labelled as the Pte-

rygium Belt [4]. The risk factors include older age, male gender and outdoors occupation. Exposure to sunlight, especially UV B rays is considered an important environmental risk factor [5]. Dry eye has also been implicated as an important risk factor for the development of pterygium [6]. This ocular surface pathology occurs as a result of alterations in local ocular surface homeostasis.

Pterygium progression is considered to be the result of two consecutive events in limbal area; firstly, due to primary disruption of limbal barrier due to chronic UV exposure, and secondly subsequent extensive proliferation of subconjunctival fibrous tissue, blood vessels, and inflammatory cells over adjacent cornea through an active process called conjunctivalization. Recurrence occurs due to the reactivation of the inflammatory process. Sometimes the surgical trauma serves as an enhancer of the inflammatory response.

A pterygium consists of three distinct parts: A head at the pterygium apex, usually with an avascular cap at the leading edge, the neck of the pterygium lies between the head and the limbus, straddling the cornea, while the body represents the main bulk of the pterygium over the sclera and extending from the canthal region. Tan and colleagues graded the pterygium based on tissue translucency [7]. They believed that loss of translucency was correlated with the thickness of fibrovascular tissue. Another grading system evaluates the effect of pterygium on corneal topography, which is determined by the extension of the head over the Cornea [8,9] and is graded as

- Grade 0 - No Pterygium
- Grade 1 - Head of Pterygium at the limbus
- Grade 2 - Head of pterygium between the limbus and the undilated pupil margin
- Grade 3 - Head of Pterygium at the pupil margin
- Grade 4 - Head of pterygium within the pupil margin

The common indications for the management of pterygium is cosmesis, induced astigmatism, increased chronic signs and symptoms, a documented history of progression, recurrent inflammation and concern about malignant change [3]. Medical management includes the use of ultraviolet filters in glasses and lubricant tear drops, there is little data available on the efficacy of this approach [10,11].

Surgery is considered as the mainstay of treatment of pterygium. For many years, a bare sclera technique, in which the

pterygium was simply excised from the cornea, leaving only bare sclera exposed was the standard approach. Hence, alternative reconstructive surgical procedures were sought including the use of Amniotic membrane (AM) or a Conjunctival Autograft (CAG) onto the bare sclera. Therefore, thorough pterygium and Tenon's tissue removal combined with a CAG transplantation is currently considered the gold standard surgical procedure [12]. CAG in pterygium surgery can be attached by sutures or fibrin glue or autologous in situ blood coagulum. Attaching CAG with autologous in situ blood coagulum is a new technique that has been in practice for the past few years. The advantages of autologous in situ blood coagulum are ready availability of patient's own blood, no additional cost, no risk of transmission of blood related diseases and no suture related complications [13,14]. Many adjuvant therapies have been used in pterygium surgery to varying degrees of success. The benefits of fibrin glue include shorter duration of surgery, and less postoperative discomfort [15]. Topical cyclosporine, Mitomycin-C (MMC), 5-fluorouracil (5-FU), and beta-irradiation have also been used, though usage of these may cause multiple adverse effects [16].

Therefore, the aim of our study was to compare the two most commonly used techniques for conjunctival autograft transplantation i.e. Sutureless, Glue free autologous in situ blood coagulum technique and the one using sutures besides comparing their outcomes postoperatively: Both immediate and short-term complications and post-operative signs and symptoms were noted.

## Materials and Methods

This was a comparative, prospective, randomized, open labelled parallel study which was conducted on 60 patients of primary Pterygium attending Outpatient Department of Ophthalmology, Government Medical College, Patiala. Patients fulfilling the inclusion criteria and having none of the exclusion criteria were enrolled in the study after obtaining written informed consent in accordance with declaration of Helsinki. The patients included age range from 18 to 80 years, were willing for enrolment and free from any ocular or extraocular diseases other than pterygium. Patients not willing for enrolment, recurrence of pterygium, having ocular or extraocular diseases other than pterygium such as blepharitis, ocular allergy, lacrimal system disease, with coagulation disorder or taking aspirin/anticoagulant therapy were excluded. After meeting the inclusion and exclusion criteria pterygium patients were examined in detail including history pertaining to symptoms, relevant

medical history and treatment history. The patients were subjected to a routine general physical examination and detailed ocular examination including Uncorrected Visual Acuity (UCVA), Best Corrected Visual Acuity (BCVA), Intraocular Pressure (IOP) and Slit lamp examination followed by photo documentation of every case. After undergoing general physical examination and detailed ocular examination, all the 60 patients were divided randomly (through use of random tables) into two groups -

- Group I (G1) 30 patients - This group was operated upon for pterygium surgery combined with conjunctival autograft transplantation by using sutureless, glue free autologous in situ blood coagulum technique
- Group II (G2) 30 patients - This group was operated upon for pterygium surgery combined with conjunctival autograft transplantation anchored using 10-0 nylon sutures.

### Surgical steps

The eye was marked for surgery and was anaesthetized using peribulbar anaesthesia (Xylocaine 2%). An eyelid speculum was inserted. Handheld cautery was used to outline the edge of the pterygium to be excised, about 4 mm from the limbus on the conjunctival side of pterygium. Local Xylocaine 2% was used to balloon the pterygium separating it from the sclera. Pterygium head was separated from the body at the limbus using corneo scleral scissors. The head was avulsed from underlying cornea with guarded traction using two lins forceps. The remaining tags were separated using crescent knife and smooth corneal surface was achieved. The body of pterygium was separated from its edges using corneoscleral scissors and the whole tissue was excised along with Tenon's capsule, leaving bare sclera. Then, the size of bare sclera was measured using callipers and the area was documented in mm<sup>2</sup>.

For harvesting the conjunctival autograft, superior temporal quadrant of bulbar conjunctiva was injected with 1 cc of local anaesthesia (Xylocaine 2%) to facilitate separation of the conjunctiva from the Tenon's capsule. A marker was used to mark the four corners of the conjunctival limbal graft to be created, about 2 mm larger in width and length than the recipient bed. A small opening was created and careful blunt dissection with Westcott scissors was performed until the entire graft was free from Tenon's capsule reaching the limbus to include limbal stem cells that act as a barrier to the conjunctival cells migrating onto the corneal surface. Subse-

quently, the edges of the graft were cut by vannas scissors. Forceps were used to gently slide the graft on to the recipient bed with the epithelial side up and keeping the limbal edge towards the limbus.

In group I (sutureless), haemostasis on the scleral bed was allowed to occur spontaneously without the use of cautery to provide for autologous fibrin to glue the conjunctival autograft naturally in position without tension and the scleral bed was viewed through the transparent conjunctiva to ensure that residual bleeding did not lift the graft. The edges of graft were undermined and tucked under bulbar conjunctiva. Small central haemorrhages were tamponed with direct compression with cotton bud. The graft was held in position for 10 minutes by application of gentle pressure over the graft with fine non toothed forceps. The stabilization of the graft was tested in the centre and on each edge to ensure firm adherence to the sclera. The eye was bandaged for 48 hours.

In group II (with sutures), the graft was sutured in position with 10-0 Nylon. First, the two limbal corners were sutured into the episclera and conjunctiva. Then the posterior corners of the graft were sutured to the bulbar conjunctiva. The additional sutures were placed close the wound edges.

Both the groups were given subconjunctival injection of corticosteroid and antibiotic at the end of surgery on the temporal side of bulbar conjunctiva carefully, in such a way that it did not lift or dislodge the graft.

At the 3<sup>rd</sup> visit (V3), the sutures were removed under topical anaesthesia with 15 no. blade.

Visits (V): During the study, patients visited the hospital on the following days -

- Day 1: V1
- Day 7: V2
- Day 30 (1 month): V3
- Day 180 (6 months): V4

All the cases were evaluated postoperatively on each visit based on complications (Both early and late) and post-operative signs and symptoms. The patients were evaluated for immediate post-operative complications at Day 1 and Day 7 i.e., Graft edema, subconjunctival haemorrhage, graft Retraction, graft dislodgement,

infection and delayed post-operative complications at 1 month and 6 months i.e. recurrence and granuloma.

The patients were provided with a questionnaire at each follow up visit. They graded the symptoms - pain, foreign body sensation, photophobia, hyperemia, and chemosis into four given grades as per the intensity

- 0 = Nothing
- 1 = Mild
- 2 = Moderate
- 3 = Severe

Satisfaction survey was conducted at the end of study at 6 months. The patients graded their subjective experience of the procedure they underwent as : 1 - Not satisfied; 2 - Less satisfied; 3 - Satisfied; and 4 - Highly satisfied.

Statistical analysis

Descriptive statistics was done for all data and were reported in terms of mean and percentages. All analysis was performed on an intention to treat basis. Appropriate statistical tests of comparison were applied i.e., unpaired ‘t’ test and chi square test. The data obtained was statistically analysed using SPSS (ver 22.0 Chicago, Illinois, USA) and Microsoft Excel 2021. The results were finally presented in tables and graphs. The p value of < 0.05 was considered statistically significant.

Observations

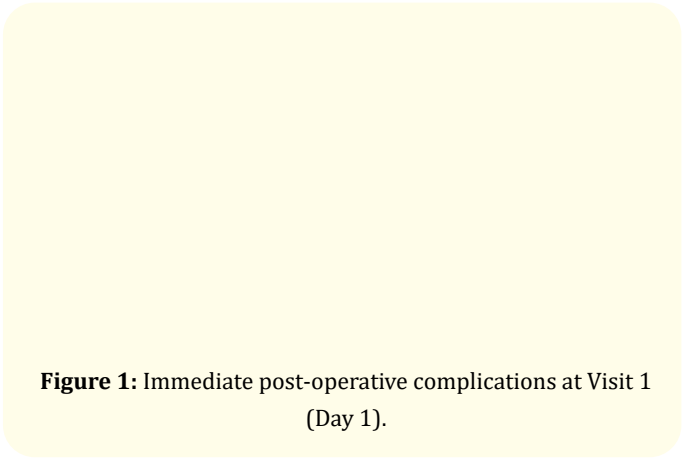


Figure 1: Immediate post-operative complications at Visit 1 (Day 1).

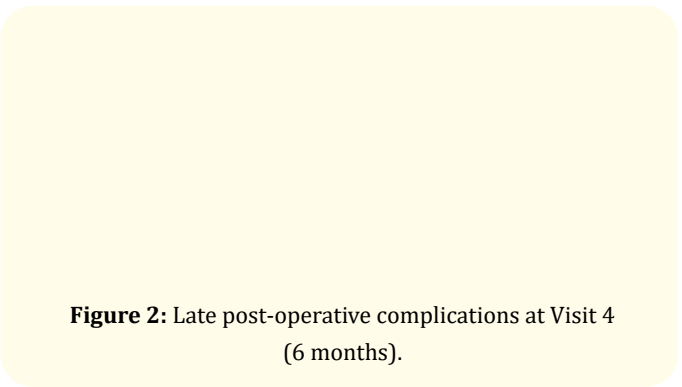


Figure 2: Late post-operative complications at Visit 4 (6 months).

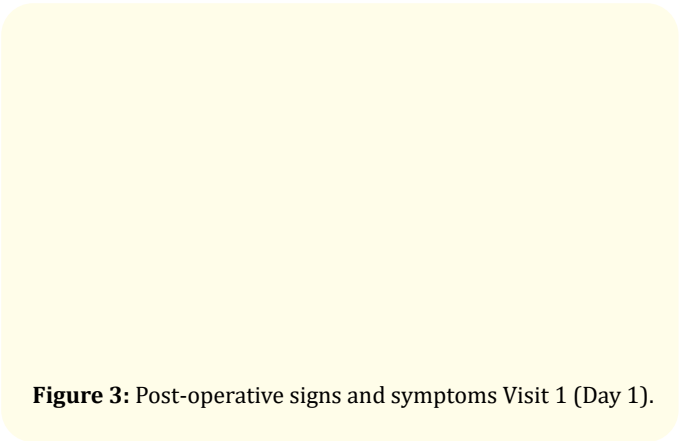


Figure 3: Post-operative signs and symptoms Visit 1 (Day 1).




Figure 4: Post-operative signs and symptoms Visit 2 (Day 7).

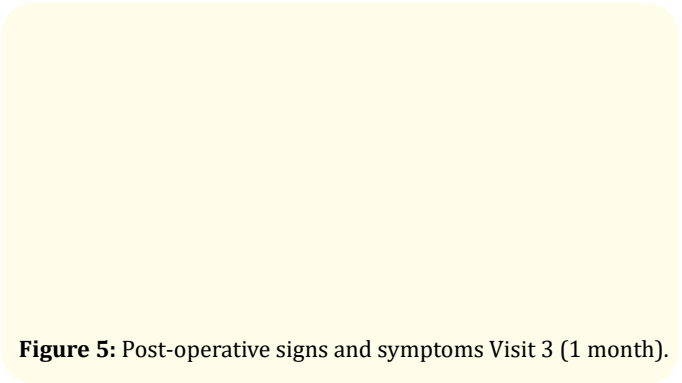
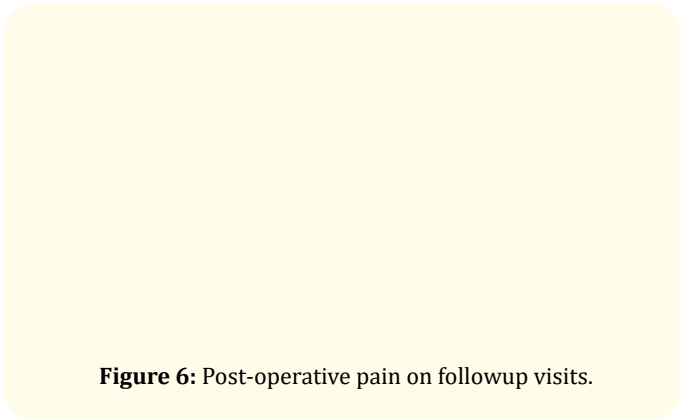



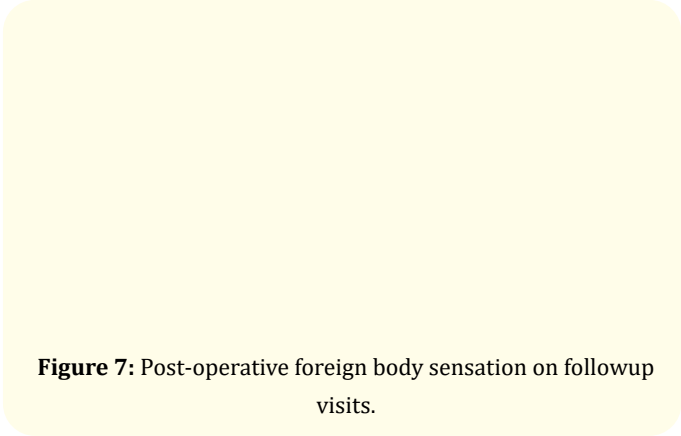
Figure 5: Post-operative signs and symptoms Visit 3 (1 month).



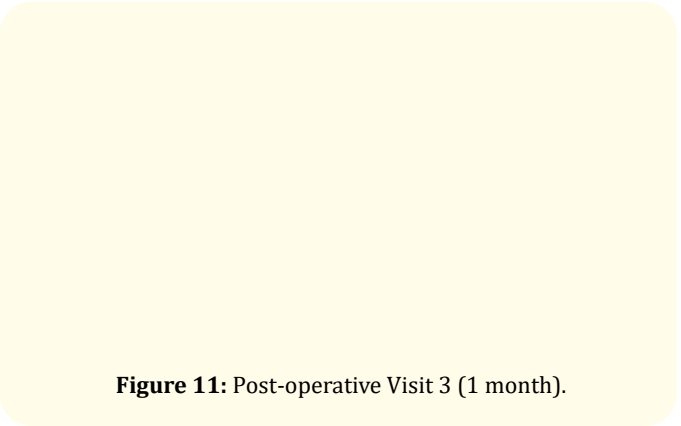
**Figure 6:** Post-operative pain on followup visits.



**Figure 10:** Post-operative Visit 2 (Day 7).



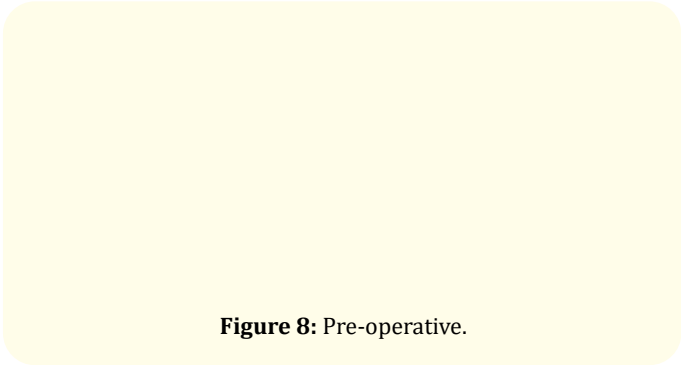
**Figure 7:** Post-operative foreign body sensation on followup visits.




**Figure 11:** Post-operative Visit 3 (1 month).

Photographic documentation

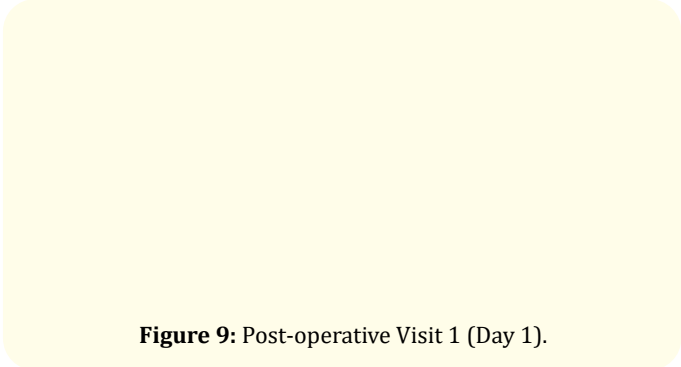
Sutureless technique



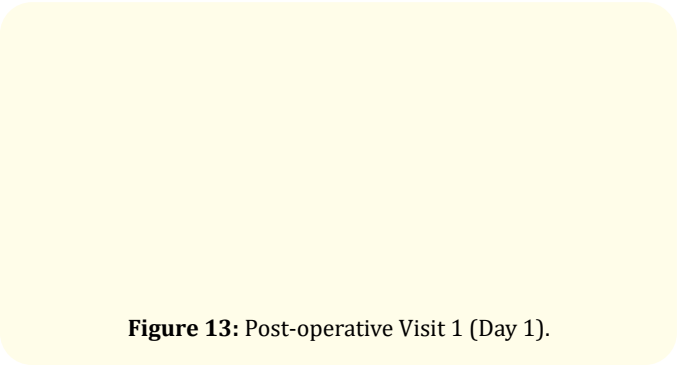
**Figure 8:** Pre-operative.



**Figure 12:** Pre-operative.



**Figure 9:** Post-operative Visit 1 (Day 1).



**Figure 13:** Post-operative Visit 1 (Day 1).

**Figure 14:** Post-operative Visit 2 (Day 7).**Figure 15:** Post-operative Visit 3 (1 month).

## Results

The age range was 22-62 years and the maximum number of patients were found to be in the age group of 41-50 years in both the groups. The mean age of the patients of the Group I (Sutureless) and Group II (Sutured) of the present study was  $42.2 \pm 10.12$  years and  $42.82 \pm 9.64$  years respectively. Group I (Sutureless) had 11 (36.67%) females and 19 (63.33%) males and Group II (Sutured) had 13 (43.33%) females and 17 (56.67%) males. Hence a total of 36 (60%) patients were males and 24 (40%) were females in both the groups. The male female ratio in our study was 1.5:1. At post-operative visit 1, 6 patients (20%) of Group I had Graft edema in comparison to 5 patients (16.67%) in Group II, which went down considerably by Visit 2 i.e. 7 days (Figure 1). Subcutaneous haemorrhage was noted in 6 (20%) patients in both the groups at visit 1. The subconjunctival haemorrhage went down gradually at subsequent visits i.e. visit 2 and visit 3 (Figure 1). Both these findings were insignificant at V4 at 6 months (Figures 3-7). Graft infection was not seen in any of the patients of both the groups at any visit during follow-up.

Graft retraction with exposure of scleral bed was noticed in 4 patients (13.33%) in Group I and in 2 patients (6.66%) in Group II at visit 1 (Figure 1). One case of retraction occurred due to retention of adherent Tenon's capsule to the graft. The causes attributed for others were chemosis and significant conjunctival edema. All the cases of graft retraction were managed conservatively and graft was repositioned with blunt forceps under topical anaesthesia using slit lamp. Graft dislodgement was observed in 1 patient (3.33%) in Group I and none in Group II (Figure 1). The case of Graft dislodgement needed review surgery and 10-0 nylon sutures were used to reposition the graft.

There was 1 (3.33%) case of recurrence reported at Visit 4 (6 months) in Group I (Sutureless) whereas 2 (6.67%) cases were reported in Group II at visit 4. One case of granuloma was reported at visit 4 in Group II and none in Group I at 6 months (Figure 2).

Our study revealed clinically significant difference between the two groups in the postoperative mean score for signs and symptoms on visit 1 and visit 2. The mean scores were significantly lower for Group I as compared to Group II for each factor graded and were statistically significant ( $p$  value  $< 0.05$ ) at visit 1 and visit 2. Our results confirmed significantly lower post-operative signs and symptoms in group I in the first post-operative week. All these signs and symptoms were insignificant at the end of 1 month and 6 months in both the groups.

A satisfaction survey was conducted amongst the patients at 6 months. Both the groups evaluated their experience of undergoing the respective technique of surgery and scoring them on the basis of their overall satisfaction with the surgery. The survey revealed higher overall satisfaction score for group I as compared to group II. These findings were consistent with the scoring for signs and symptoms experienced by the respective groups during immediate post-operative visits.

## Discussion and Conclusion

Pterygium is a triangular fleshy fibrovascular growth of bulbar conjunctiva onto the cornea. It is linked to multiple risk factors notably to UV rays and dry eye. It presents with various symptoms like irritation, watering and redness but the most important causes to undergo surgery are cosmesis and refractive changes.

Various modalities are used to treat pterygium, with surgery at the forefront. Many advancements have taken place since the intro-



duction of concept of Conjunctival autograft. It can be applied onto the surgical site by various methods namely with suture, with glue or by using in vivo autologous blood at the surgical site itself. The most commonly used techniques for transplantation of conjunctival graft are with sutures. But sutureless technique has been used lately for its range of benefits. Our study was done to compare the results of both these and evaluate them.

Our study revealed the patients age ranged between 22-62 years and the maximum number of patients were found to be in the age group of 41-50 years in both the groups. The study by Thatte., *et al.* [17] conducted on a total of 151 patients, the age ranged between 21-64 years. This study had most patients in the age group of 35-50 years. The mean age of the patients of the Group 1 and Group 2 of our study was  $42.2 \pm 10.12$  years and  $42.82 \pm 9.64$  years respectively. Shaaban., *et al.* [18] found the mean age of the patients to be  $49 \pm 12$  years. Bhargava., *et al.* [19] and Das., *et al.* [20] had similar findings in their study.

In the present study, a total of 36 (60%) patients were males and 24 (40%) were females in both the groups. The male female ratio in our study was 1.5:1. Thatte., *et al.* in their study on 151 patients, had 87 (57%) females whereas 64 (43%) males. The male to female ratio was 1:1.35. Similarly, Das., *et al.* [20] in their study on 50 patients had a male to female ratio of 1.17:1. Shaaban., *et al.* [18] and Bhargava., *et al.* [19] too had identical observations.

In our study, Graft edema was noticed in 6 (20%) patients of Group 1 and 5 patients (16.67%) in Group 2 which went down considerably at the end of first week i.e. 7 days. Subcutaneous haemorrhage was noted in 6 patients in both the groups. Both these findings went down gradually in following visits and were insignificant at the later visits. Graft infection was not seen in any of the patients of both the groups at any visit during follow-up. The incidence of immediate postoperative complications in both the groups on visit 1 & visit 2 was comparable. Shaaban., *et al.* [18] also reported similar findings in a study on 150 patients. The incidence of Graft edema was 8 (16%) in Group 1 of 50 patients with sutureless conjunctival autograft and 6 (6%) in Group 2 of 100 patients with sutured conjunctival autograft. Bhargava., *et al.* [19] found incidence of Graft edema in 25 (8.33%) patients out of 300 patients. Thatte., *et al.* [17] reported subcutaneous haemorrhage in 24 (16%) patients operated upon for pterygium out of 151 patients by suture-

less technique. Incidence of Graft retraction was noticed more in the sutureless group when compared to the group operated upon with sutures. Graft dislodgement was observed only in one patient of sutureless group. Similar study by Elwan., *et al.* [18] had an incidence for Graft Retraction in 6 (12%) in 50 patients of Group 1 (Sutureless) and 6 (6%) in 100 patients of Group 2 (Sutured). Similarly, Malik K., *et al.* [21] and Foroutan., *et al.* [22] reported identical findings. Our study revealed there was no statistically significant difference in terms of graft stability between both the groups.

At 6 months recurrence was observed in both the groups and the difference was statistically insignificant. Elwan., *et al.* [18] reported recurrence in 3 out of 50 patients (6%) in Group 1 treated by sutureless technique and 8 out of 100 (8%) in Group 2 treated by applying sutures to the graft, implying similar observations. Thatte., *et al.* [17] reported incidence of recurrence in 2 patients (1.32%) in a group of 151 patients. 1 case of Granuloma was observed in current study associated with the use of sutures. Foroutan., *et al.* [22] also reported similar observations in their study.

Our study revealed lower post-operative signs and symptoms at all visits in group I in the first post-operative week when compared to group II, implying that sutureless technique is better than sutures. The mean scores were significantly lower for Group 1 as compared to Group 2 for each factor graded and were statistically significant ( $p$  value < 0.05) at visit 1 and visit 2. All these signs and symptoms tapered off gradually in follow up visits and were insignificant at the end of 1 month and 6 months in both the groups (visits 3&4). The findings of satisfaction survey revealed similar findings with sutureless technique scoring better. The inferences drawn from these findings indicate better post op results when patient is operated upon with sutureless technique. Das., *et al.* [20] reported similar incidence with sutured group experiencing more post-operative symptoms as compared to sutureless group. They reported most of the post-operative symptoms on Day 1. Bhargava., *et al.* [19] reported 70% incidence of post-operative pain on Day 1 which decreased significantly at the end of first week. They also reported hyperemia in 127 patients out of 300 (42%) which dropped to 6% at the end of 1 month. Shaaban., *et al.* [18] reported similar findings with Group 1 with sutureless technique experiencing significantly lesser symptoms than the Group 2 operated with sutures.

Our current study had several limitations. including less sample size with very short term follow up of six months. Our study had little statistical power to effectively compare the outcomes and potential complications inherent to the two techniques So, the data cannot be extrapolated to general population in current circumstances. Future prospective studies are warranted with a greater number of patients and longer follow up to reach more robust statistical conclusions about comparative efficacy of the two techniques.

So, we conclude that sutureless glue free technique for primary pterygium surgery with conjunctival autograft transplantation is equally efficacious when compared to the technique using sutures for stabilizing the conjunctival autograft, in terms of post-operative complications. Sutureless technique is statistically better than the one using sutures in terms of immediate post-operative signs and symptoms (p value <0.05). The same results have reflected in patient Satisfaction Survey at the end of study, in which Group I has scored better than Group II (p value <0.05). Sutureless, glue free autologous in situ blood coagulum technique may, therefore, be considered as a viable alternative to sutured technique both in terms of patient satisfaction and surgical outcomes.

### Conflict of Interest

The authors have declared no conflict of interest.

### Bibliography

1. Young AL., *et al.* "The evolving story of Pterygium". *Cornea* 37 (2018): S55-S57.
2. Mohammed I. "Treatment of pterygium". *Annals of African Medicine* 10.3 (2011): 197-203.
3. Shahraki T., *et al.* "Pterygium: an update on pathophysiology, clinical features, and management". *Therapeutic Advances in Ophthalmology* 13 (2021): 1-21.
4. Singh SK. "Pterygium: epidemiology prevention and treatment". *Community Eye Health* 30.99 (2017): S5-S6.
5. McCarty CA., *et al.* "Epidemiology of pterygium in Victoria, Australia". *British Journal of Ophthalmology* 84.3 (2000): 289-292.
6. Ishioka M., *et al.* "Pterygium and dry eye". *Ophthalmologica* 215.3 (2001): 209-211.
7. Tan DT., *et al.* "Effect of pterygium morphology on pterygium recurrence in a controlled trial comparing conjunctival autografting with bare sclera excision". *Archives of Ophthalmology* 115.10 (1997): 1235-1240.
8. Maheshwari S. "Pterygium-induced corneal refractive changes". *Indian Journal of Ophthalmology* 55.5 (2007): 383-386.
9. Tan C., *et al.* "Epidemiology of pterygium on a tropical island in the Riau Archipelago". *Eye* 20.8 (2006): 908-912.
10. Sandford-Smith J. "Eye diseases in hot climates". Elsevier (2014): 63-78.
11. Bahuva A and Rao SK. "Current concepts in management of pterygium". *Delhi Ophthalmological Society* 25.2 (2015): 78-84.
12. Fuest M., *et al.* "New treatment options for pterygium". *Expert Review of Ophthalmology* 12.3 (2017): 193-196.
13. Mejía LF., *et al.* "Comparison of 4 techniques for limbal-conjunctival autograft fixation in primary pterygium surgery". *European Journal of Ophthalmology* 27.4 (2017): 466-469.
14. Yan B., *et al.* "Modified sutureless and Glue-free method versus conventional sutures for Conjunctival autograft fixation in Primary Pterygium Surgery: A Randomized Controlled Trial". *Cornea* 38.11 (2019): 1351-1357.
15. Wang X., *et al.* "Comparison of fibrin glue and Vicryl sutures in conjunctival autografting for pterygium surgery". *Molecular Vision* 23.4 (2017): 275.
16. Chu WK., *et al.* "Pterygium: new insights". *Eye* 34.6 (2020): 1047-1050.
17. Thatte S., *et al.* "Efficacy of autologous serum in fixing conjunctival autografts of various sizes in different types and grades of pterygium". *Journal of Ophthalmic and Vision Research (JOVR)* 14.2 (2019): 136.
18. Elwan SA. "Comparison between sutureless and glue free versus sutured limbal conjunctival autograft in primary pterygium surgery". *Saudi Journal of Ophthalmology* 28.4 (2014): 292-298.
19. Bhargava P., *et al.* "Pterygium excision followed by sutureless and glue free infero-temporal conjunctival autograft". *Delhi Ophthalmological Society* 30.1 (2019): 32-35.



20. Das PJ, *et al.* "Pterygium surgery with conjunctival autograft with sutures versus suture-less and glue-less: A prospective comparative study". *International Journal of Ocular Oncology and Oculoplasty* 5.4 (2019): 194-200.
21. Malik K, *et al.* "Efficacy of sutureless and glue free limbal conjunctival autograft for primary pterygium surgery". *Nepalese Journal of Ophthalmology* 4.2 (2012): 230-235.
22. Foroutan A, *et al.* "Efficacy of autologous fibrin glue for primary pterygium surgery with conjunctival autograft". *Journal of Current Ophthalmology* 23.1 (2011): 39-47.

#### Assets from publication with us

- Prompt Acknowledgement after receiving the article
- Thorough Double blinded peer review
- Rapid Publication
- Issue of Publication Certificate
- High visibility of your Published work

**Website:** [www.actascientific.com/](http://www.actascientific.com/)

**Submit Article:** [www.actascientific.com/submission.php](http://www.actascientific.com/submission.php)

**Email us:** [editor@actascientific.com](mailto:editor@actascientific.com)

**Contact us:** +91 9182824667