

CuRRL Syndrome: A Case Series

Tan Aik Kah**Clinique d'ophtalmologie, Normah Medical Specialist Centre, Malaysia****Corresponding Author:** Tan Aik Kah, Clinique d'ophtalmologie, Normah Medical Specialist Centre, Malaysia.**Received:** October 03, 2018; **Published:** November 05, 2018**Abstract**

Patients with increased cup:disc ratio are mostly asymptomatic and are detected incidentally during eye screening. While glaucoma often comes to the mind of the clinicians, there are other causes of increased cup:disc ratio. Retinal blood vessels have marked morphological and physiological similarities with cerebral blood vessels. Patients with cerebrovascular disease are known to have detectable pathologies in the retinal vasculature. This case series describes the tetrad of increased Cup: Disc Ratio, Retinal Ganglion Cell Complex thinning, Radial Peripapillary Capillary Network Density Reduction and Leukoaraiosis (CuRRL syndrome). While the evidence may not be convincing enough for CuRRL syndrome to be considered as a specific disease, recognition of this interesting association and further research will guide clinicians on early intervention towards prevention or reduction cerebrovascular morbidity and mortality.

Keywords: Cup: Disc Ratio; Retinal Ganglion Cell; Leukoaraiosis; Radial Peripapillary Capillary

Abbreviations

CDR: Cup: Disc Ratio; GCC: Ganglion Cell Complex; IOP: Intraocular Pressures; IOP: Inner Plexiform Layer; MRI: Magnetic Resonance Imaging; OCT: Optical Coherent Tomography; RGC: Retinal Ganglion Cell; RNFL: Retinal Nerve Fiber Layer; RPC: Radial Peripapillary Capillary

Background

The optic disc is the place within the eye where the retinal nerve fibres converge to form the optic nerve. The outer pink area that contains the retinal nerve fibres is the neuroretinal rim. Whereas the inner pale area (optic cup) does not contain any retinal nerve fibres. The cup:disc ratio (CDR) is dependent on the size of the optic disc [1]. Normal CDR is about 0.3. Patients with increased CDR are mostly asymptomatic and are detected incidentally during eye screening. It is only at a very late stage when patients start to complain of visual problems. While glaucoma often comes to the mind of the clinicians, there are other causes of increased CDR. The word "syndrome" is used in medicine to describe a group of features [symptoms, signs or test results] that tend to occur together, sometimes without a clear enough understanding of their cause to be considered a specific disease [2]. For example Down syndrome was first described in 1862, but the cause for Down syndrome

[trisomy 21] was only discovered ninety seven years later; in 1959 [3]. This case series describes the presence of leukoaraiosis associated with increased CDR, thinning of the retinal ganglion cell complex (GCC) and reduction in radial peripapillary capillary (RPC) network. These patients were found to have cerebrovascular risk factors. The hypothesis of this association arise from the fact that retinal blood vessels have marked morphological and physiological similarities with cerebral blood vessels [4].

Case Presentation**Patient 1**

A 46-year old gentleman presented with right upper eyelid pyogenic granuloma. He was noted to have xanthelasma and his blood pressure was 140/100. CDRs were 0.5 bilaterally (Figure 1A). The intraocular pressures (IOPs) were 12 mm Hg (right) and 10 mm Hg (left). There was no visual field defect. Optical coherent tomography (OCT) scan showed some decrease of the GCC in both eyes (Figure 1B). Otherwise the retinal nerve fiber layers (RNFL) were within normal limit. In the OCT angiography, the RPC network density was reduced superiorly in the right eye (Figure 1C). Magnetic resonance imaging (MRI) of the brain showed leukoaraiosis in the frontal-parietal and parietal occipital regions (Figure 1D).




Figure 1A




Figure 1B




Figure 1C

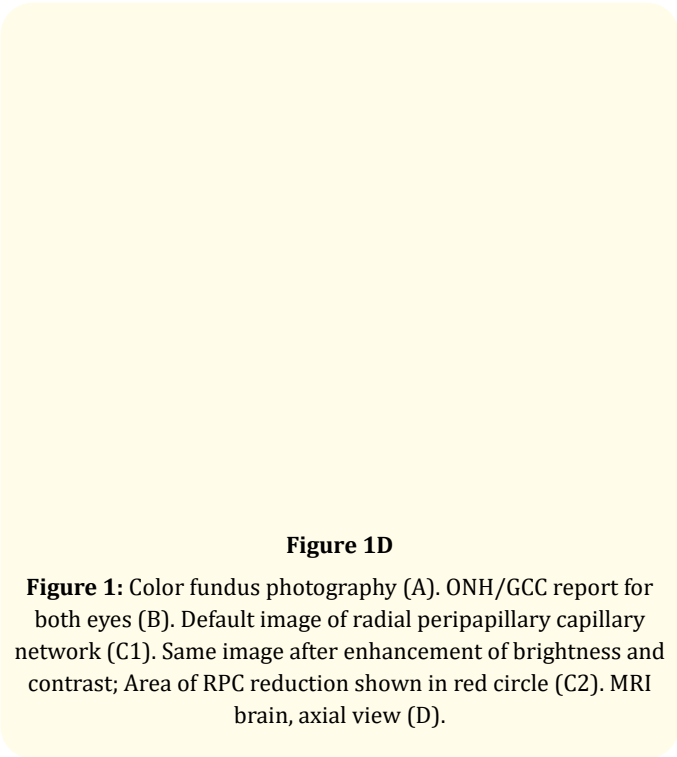


Figure 1D

Figure 1: Color fundus photography (A). ONH/GCC report for both eyes (B). Default image of radial peripapillary capillary network (C1). Same image after enhancement of brightness and contrast; Area of RPC reduction shown in red circle (C2). MRI brain, axial view (D).

Patient 2

A 65-year old gentleman with type 2 diabetes mellitus, hypertension and dyslipidaemia, presented with right corneal foreign body. CDRs were 0.6 (right), 0.5 (left) (Figure 2A). The IOPs were 12 mm Hg bilaterally. There was no visual field defect. OCT showed reduction of the GCC in both eyes; more on the right (Figure 2B). The RNFL was thinner superiorly in the right eye. In the OCT angiography, the RPC network density was reduced superiorly in the right eye (Figure 2C). MRI showed extensive leukoaraiosis (Figure 2D).




Figure 2A




Figure 2B




Figure 2C

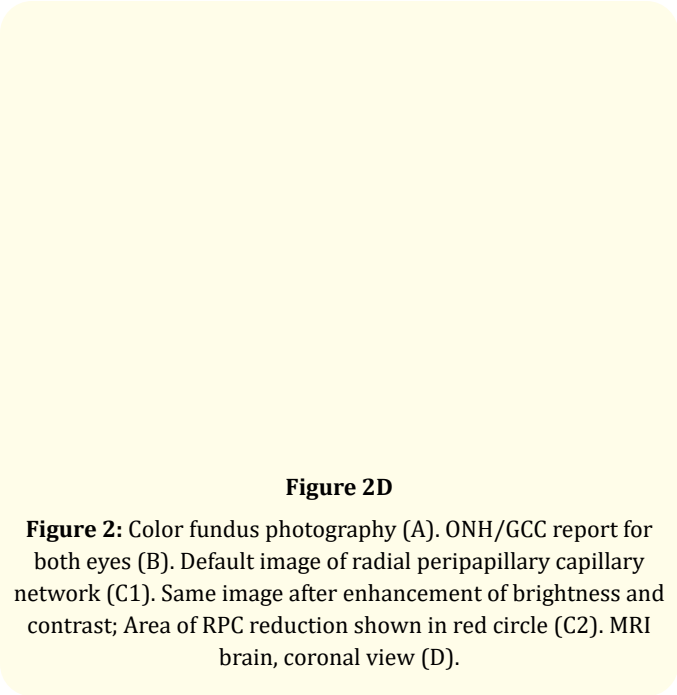


Figure 2D

Figure 2: Color fundus photography (A). ONH/GCC report for both eyes (B). Default image of radial peripapillary capillary network (C1). Same image after enhancement of brightness and contrast; Area of RPC reduction shown in red circle (C2). MRI brain, coronal view (D).

Patient 3

A 56-year old gentleman with hypertension, presented with dry eyes. CDRs were 0.6 bilaterally (Figure 3A). The IOPs were 14 mm Hg bilaterally. There was no visual field defect. OCT showed significant reduction of the GCC in both eyes (Figure 3B). The RNFLs were normal bilaterally. In the OCT angiography, the RPC network density was reduced superiorly in the right (Figure 3C). MRI showed extensive leukoaraiosis (Figure 3D).



Figure 3A




Figure 3B




Figure 3C

Figure 3D

Figure 3: Color fundus photography (A). ONH/GCC report for both eyes (B). Default image of radial peripapillary capillary network (C1). Same image after enhancement of brightness and contrast; Area of RPC reduction shown in red circle (C2). MRI brain, axial view (D).

The above are incidental findings. The optic disc cupping and OCT scans were not characteristics of glaucomatous optic neuropathy. All three patients have normal higher mental functions and no neurological deficit. They were referred to physician for the management of cerebrovascular risk factors and were prescribed aspirin 100 mg daily.

Discussion

The term leukoaraiosis was coined by Hachinski., *et al.* to describe lesions due to reduction in density (araiosis) of the white matter (leuko) of the brain. On computed tomography scan, leukoaraiosis is hypodense, whereas on MRI, it is hyperintense on T2-weighted images [5]. Leukoaraiosis is a result of cerebral ischemia and is characterized by thickening of the cerebral blood vessel wall [6] due to chronic atherosclerotic disease [7]. The severity of leukoaraiosis is directly proportional to the degree of stenosis of the medullary arterioles due to arteriosclerosis [4].

Patients with primary open angle glaucoma are found to have higher likelihood of leukoaraiosis [8,9]. This is due to the fact that retinal blood vessels have marked morphological and physiological similarities with cerebral blood vessels [4]. The RPCs originate from the arterioles that supplied the peripapillary tissue of the retina and is closely associated with the inner portion of the superficial retinal nerve fibres at the posterior pole [10]. Radial peripapillary capillaries (RPCs), like any other retinal

blood vessels, undergo similar pathophysiological changes as cerebral medullary arterioles; with aging, hypertension, diabetes and other diseases [4]. Hence there are plausible explanations for the association between the reduction in RPCs density (in OCT angiography) and leukoaraiosis (in MRI).

In the patients above, the retinal ganglion cell complex (GCC) scans showed abnormalities that is not consistent with glaucomatous optic neuropathy. Retinal ganglion cells begin with dendrites in the inner plexiform layer (IPL) layers. The cell bodies are located in the retinal ganglion cell (RGC) layer. Their axons emerge in the retinal nerve fiber layer (RNFL), converge at the scleral foramen forming the neuroretinal rim of the optic nerve head, before travelling in the optic nerve, optic chiasm, and the optic tract to end at the lateral geniculate body. The ganglion cell complex (GCC) in the OCT consists of the IPL, RGC and RNFL. The RTVue FD-OCT system (Optovue, Inc.) measures GCC thickness within an automatically rendered 7-mm² area, centered 1 mm temporal to the fovea. Acquired GCC thicknesses are compared with values from a normative database and displayed as a color-coded significance map [green: p > 5% within normal, yellow p < 5% borderline, red p < 1% outside normal]. In retinal ganglion cell injury or death, the earliest changes are seen in the IPL, followed by the RGC [11], with eventual thinning of the RNFL (due to phagocytosis of the axons) [12] and increased of CDR (due to thinning of the neuroretinal rim).

Therefore, GCC scan (around the macula) is more sensitive than RNFL scan (around the optic nerve head) to detect subtle changes involving the retinal ganglion cells. While most of the research focused on glaucomatous optic neuropathy, any pathologies along the course of the retinal ganglion cells (from the IPL to the lateral geniculate bodies in the midbrain) are detectable in the GCC scan.

Conclusions

When the condition was first described in 1986, leukoaraiosis was not known to be associated with any definite pathological changes or clinical manifestations. It is now known that leukoaraiosis is commonly found in patients with ischemic stroke [13]. This case series describes the tetrad of Increased Cup:Disc Ratio, Retinal Ganglion Cell Complex thinning, Radial Peripapillary Capillary Network Density Reduction and Leukoaraiosis (CuRRL syndrome). The clinical significance of the above associations is yet to be fully understood. However, it is recommended to perform OCT and OCT angiography, in addition to fundus photography for patient with increased CDR. These will help clinicians to decide if MRI is further indicated.

Future Research

While the evidence may not be convincing enough for CuRRL syndrome to be considered as a specific disease, recognition of this interesting association and further research will guide clinicians on early intervention towards prevention or reduction cerebrovascular morbidity and mortality. Further research is needed in this area to quantify the relationship between RPC reduction and the presence of leukoaraiosis, to better identify the subset of patients that require MRI, to determine the risk of ischemic stroke in patient with leukoaraiosis, and to determine the role of anti-platelet therapy in the prevention of ischemic stroke in patients with clinically silent leukoaraiosis.

Competing Interests

The authors declare that he has no competing interests.

Funding Funding

No grants or funds were received for this study.

Bibliography

1. Garway-Heath D., *et al.* "Vertical cup/disc ratio in relation to optic disc size: its value in the assessment of the glaucoma suspect". *British Journal of Ophthalmology* 82.10 (1998): 1118-1124.

2. Shmerling R. "The times, they are a-changin' (and bringing new syndromes)" (2016).

3. Mégarbané A., *et al.* "The 50th anniversary of the discovery of trisomy 21: the past, present, and future of research and treatment of Down syndrome". *Genetics in Medicine* 11.9 (2009): 611-616.

4. Patton N., *et al.* "Retinal vascular image analysis as a potential screening tool for cerebrovascular disease: a rationale based on homology between cerebral and retinal microvasculatures". *Journal of Anatomy* 206.4 (2005): 319-348.

5. Hachinski VC., *et al.* "Leuko-araiosis: An ancient term for a new problem". *The Canadian Journal of Neurological Sciences* 13.4 (1986): 533-534.

6. Auriel E., *et al.* "Clinical, radiological and pathological correlates of leukoaraiosis". *Acta Neurologica Scandinavica* 123.1 (2011): 41-47.

7. Einor Ben-Assayag., *et al.* "Leukoaraiosis Is a Chronic Atherosclerotic Disease". *The Scientific World Journal* (2012): 532141.

8. Mercieca K., *et al.* "Primary Open Angle Glaucoma is Associated with MR Biomarkers of Cerebral Small Vessel Disease". *Scientific Reports* 6 (2016): 22160.

9. Johannes Schoemann., *et al.* "Cerebral Microinfarcts in Primary Open-Angle Glaucoma Correlated With DTI-Derived Integrity of Optic Radiation". *Investigative Ophthalmology and Visual Science* 55.11 (2014): 7241-7247.

10. Paul Henkind. "Radial Peripapillary Capillaries of the Retina. Anatomy: Human and Comparative". *British Journal Of Ophthalmology* 51.2 (1967): 115-123.

11. Feng L., *et al.* "Sustained ocular hypertension induces dendritic degeneration of mouse retinal ganglion cells that depends on cell type and location". *Investigative Ophthalmology and Visual Science* 54.2 (2013): 1106-1117.

12. Fortune B., *et al.* "Relative course of RNFL birefringence, RNFL thickness and retinal function changes after optic nerve transection". *Investigative Ophthalmology and Visual Science* 49.10 (2008): 4444-4452.

13. Smith EE. "Leukoaraiosis and Stroke". *Stroke* 41.10 (2010): S139-S143.

Volume 1 Issue 3 November 2018
© All rights are reserved by Tan Aik Kah.