

Transcutaneous Serdev Suture® Suspensions for Lifting or Volume Augmentation in Face and Body

Nikolay P Serdev*

Honorary Professor, Director of the International Program in Aesthetic/Cosmetic Surgery at the New Bulgarian University and Head, Medical Centre "Aesthetic Surgery, Aesthetic Medicine and President the Bulgarian Society for Aesthetic Surgery and Aesthetic Medicine, Sofia, Bulgaria

***Corresponding Author:** Nikolay P Serdev, Honorary Professor, Director of the International Program in Aesthetic/Cosmetic Surgery at the New Bulgarian University and Head, Medical Centre "Aesthetic Surgery, Aesthetic Medicine and President the Bulgarian Society for Aesthetic Surgery and Aesthetic Medicine, Sofia, Bulgaria.

Received: February 06, 2020**Published:** June 29, 2021© All rights are reserved by **Nikolay P Serdev**.**Abstract**

Scarless closed approach suture liftings present skeletal fixation with skin punctures without incisions as a first alternative to classic excision lifts. We started the anatomy study, instrument creation and thread selection in 1990 and the whole topographic anatomy, instrumentarium and technique understanding of this new method was ready in 1993 [1-4]. Needle preparation and selection of threads was experimental. For threads we have performed stretch, elasticity and cut through tests. Thread long term absorption is crucial in our method. In the year 1993 - 1994 [2] we have operated 54 patients to correct early ptosis and flabbiness in areas of face and body and published our results. Our contribution is that our closed approach suture techniques lift SMAS and fascias without traditional incisions. Operations are ambulatory with excellent results, reported by the patients. The trauma is minimal and the follow-up period is no longer than hours to 3 days with fast, sometimes immediate return to work and social life. There are no visible scars, the needle perforations on the skin are not visible after days.

Keywords: Serdev Suture®; Augmentation; Face and Body

Technique and anatomical fixations

Operations are ambulatory without hospital stay. The techniques consist of passing closed sutures, by needle perforations only, to lift movable fascias and fix them to non-movable skeletal structures in several facial and body areas [1-23].

We perform the following scarless closed approach suture lifts:

I. In face areas:

- Ambulatory temporal and supra-temporal SMAS Lift;
- Brow lift,
- Lateral canthus lifting,
- Glabella muscle ligation,
- Mid face SMAS suture lift,

- Cheekbone SMAS lift and volume creation,
- Lower SMAS face and neck lift,
- Chin enhancement, form and position correction by suture;
- Nasal tip refinement; nasal tip rotation; nasal alar base narrowing;
- Scarless Serdev suture® method in prominent ears,
- Dimple formation in chin and smiling point etc.

II. In body areas:

- Scarless buttock lift by suture,
- Scarless breast lift by suture,
- Scarless Serdev suture to reposition breast implants in symmastia and false position

- Abdominal flaccidity tightening,
- Inner thigh lift.

Results

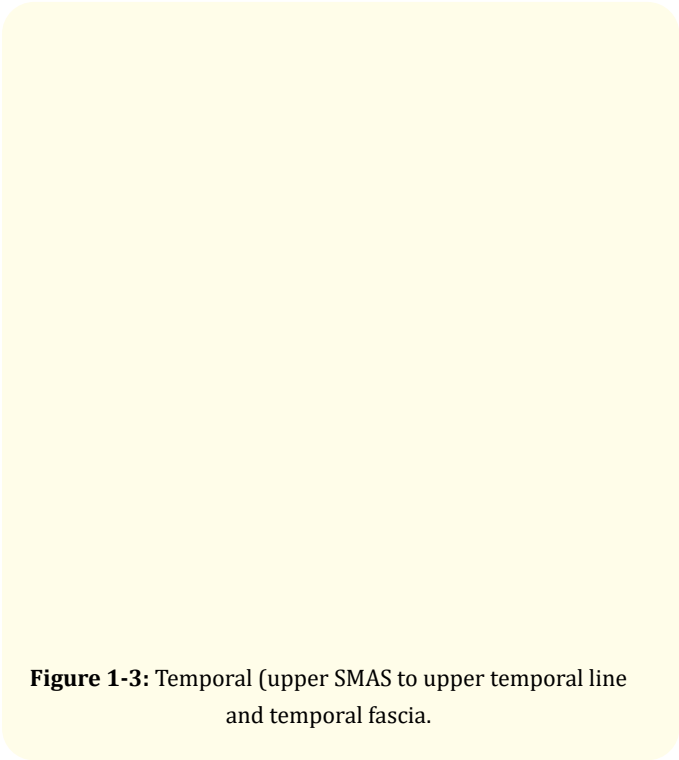


Figure 1-3: Temporal (upper SMAS to upper temporal line and temporal fascia).

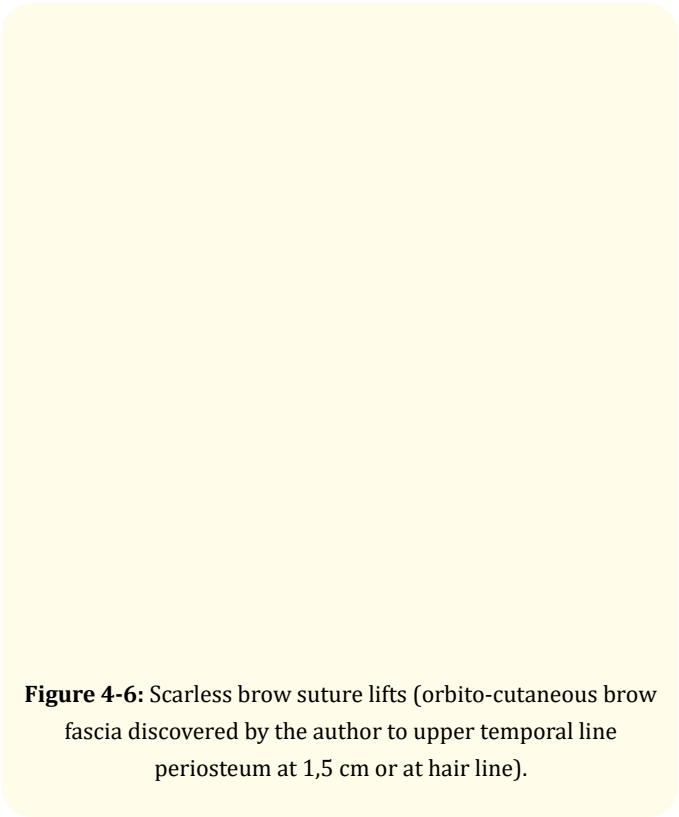


Figure 4-6: Scarless brow suture lifts (orbito-cutaneous brow fascia discovered by the author to upper temporal line periosteum at 1,5 cm or at hair line).




Figure 7 and 8: Mid-face suture lifts (SMAS zygomatic extension to upper temporal line periosteum or to temporo-parietal tendon).

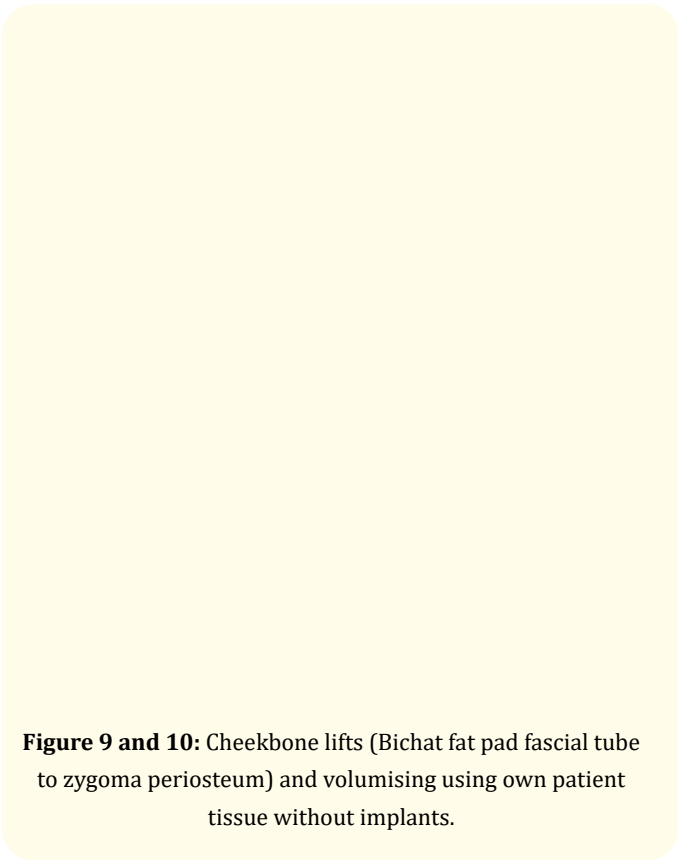


Figure 9 and 10: Cheekbone lifts (Bichat fat pad fascial tube to zygoma periosteum) and volumising using own patient tissue without implants.

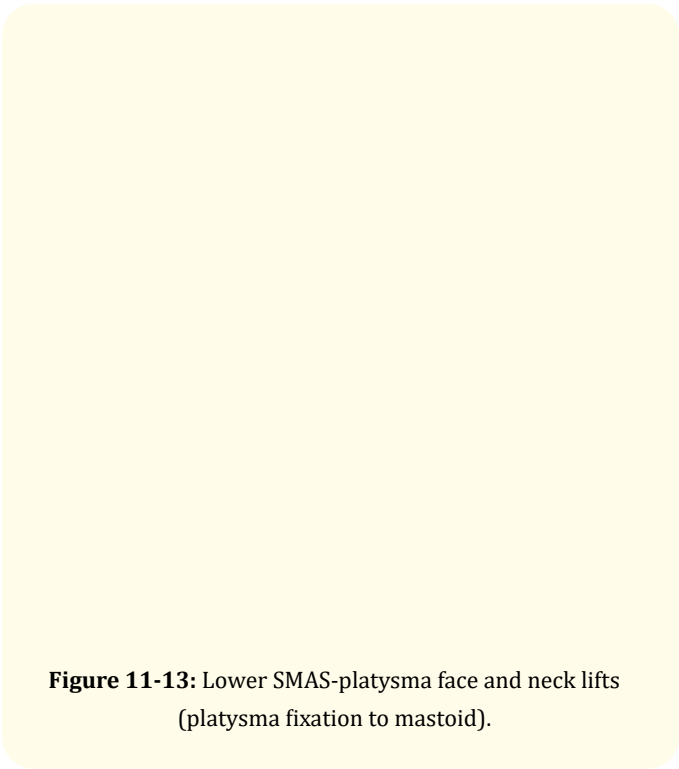


Figure 11-13: Lower SMAS-platysma face and neck lifts (platysma fixation to mastoid).



Figure 14-16: Chin enhancements, form and position corrections with or without fixation to the menton.

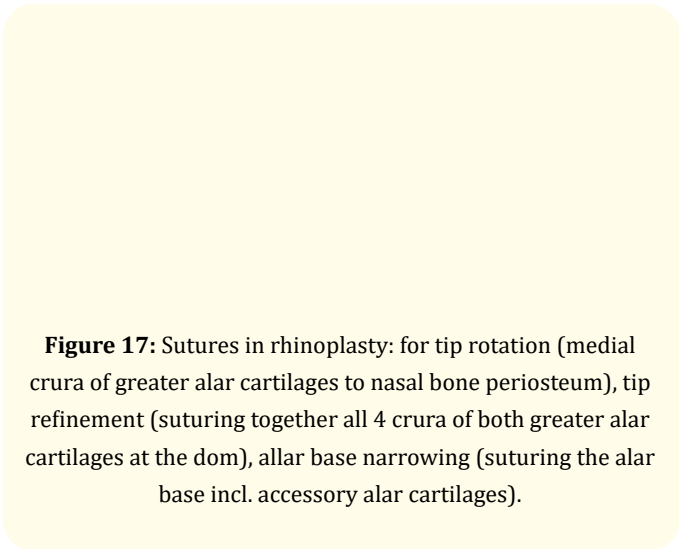


Figure 17: Sutures in rhinoplasty: for tip rotation (medial crura of greater alar cartilages to nasal bone periosteum), tip refinement (suturing together all 4 crura of both greater alar cartilages at the dom), allar base narrowing (suturing the alar base incl. accessory alar cartilages).

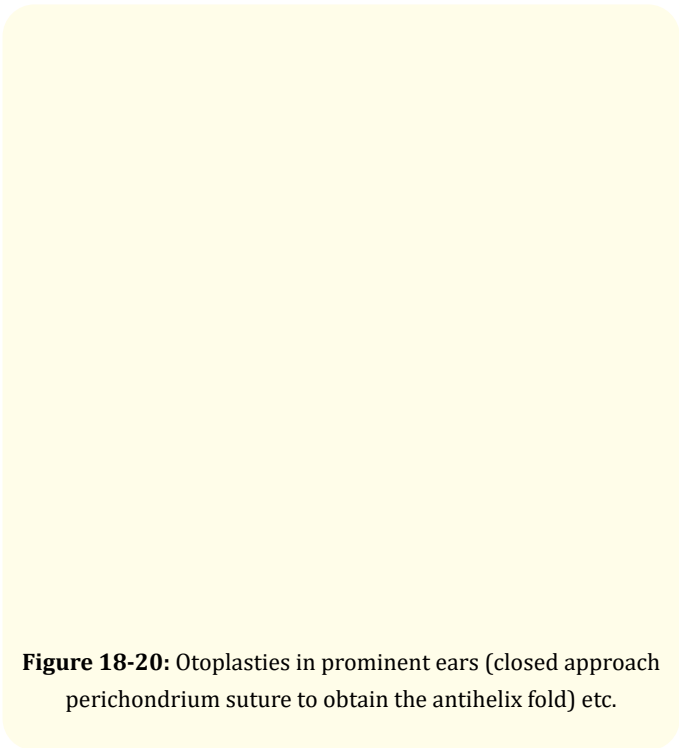


Figure 18-20: Otoplasties in prominent ears (closed approach perichondrium suture to obtain the antihelix fold) etc.

In body areas

Results in all our patients are more than satisfactory. Patients are mostly amazed by the immediate beautification, rejuvenation and the great difference before and after without scars and with nearly immediate return to work and social meetings.

The cosmetic results were evaluated with preoperative and postoperative photographs and by patient satisfaction. Patient were satisfied with the results and all of them considered their results as excellent or good.

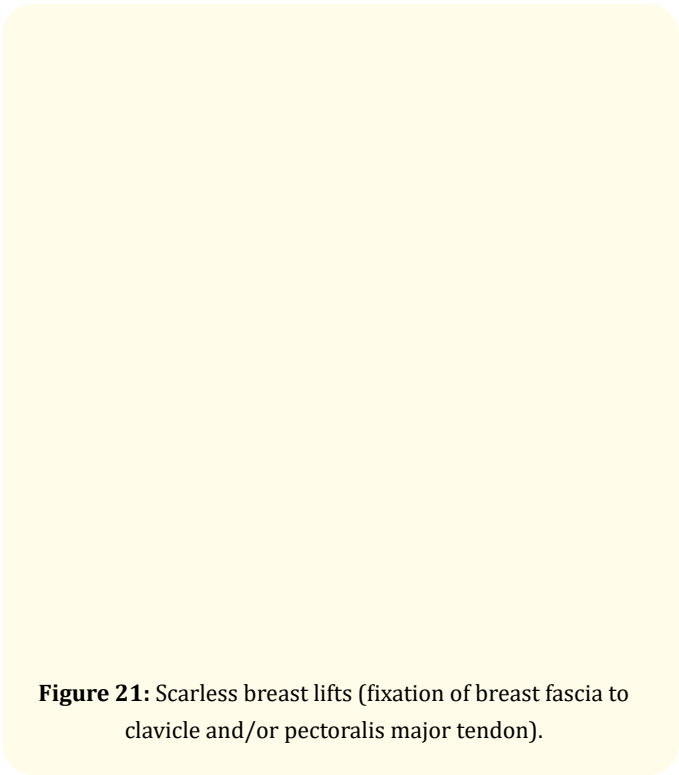


Figure 21: Scarless breast lifts (fixation of breast fascia to clavicle and/or pectoralis major tendon).



Figure 22-24: Buttock lifts (fixation of the fibrous tissue to the sacro-cutaneus fascia, found by the author).

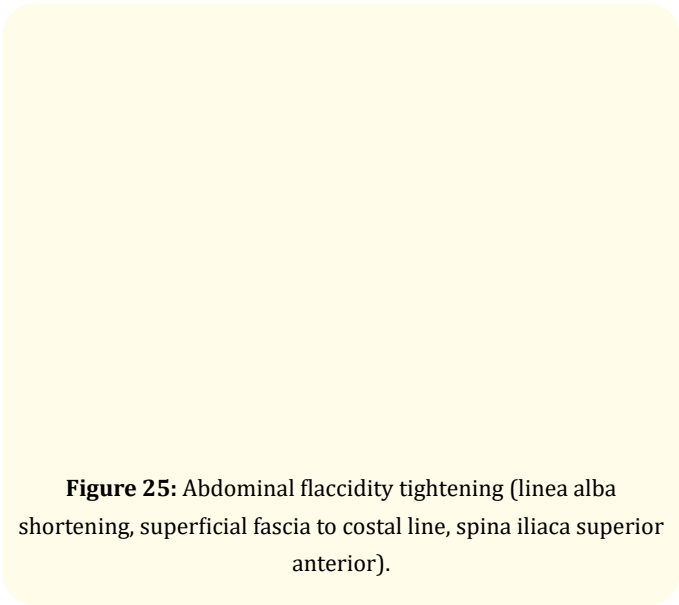


Figure 25: Abdominal flaccidity tightening (linea alba shortening, superficial fascia to costal line, spina iliaca superior anterior).




Figure 26: Inner thigh lift.

We have observed no other complications, except some local infections in one of the perforation points in the early postop period, treated in a day or two. No nerve damage by the suture was observed. Cheekbone sutures were removed in one Asian patient due to patient’s aesthetic considerations.

Discussion

Nowadays these methods are preferable in the modern society where business does not allow long time of absence. Closed approach suture methods have shown priority over classic excision liftings requiring hours of operation, marked trauma, long postoperative swelling and downtime.

Serdev suture® liftings require about 15 min of operating time per side, no blood loss or transfusions, no stay at the clinic, no nursing care and not more than a day or two off work. Results are immediate with no downtime. Most of the patients work next day after operation that is most appreciated by the patients.

Conclusion

We can recommend the closed suture methods for young and mid age patients with congenital problems in aesthetic appearance and in cases of initial or moderate flabbiness and tissue sagging.

Author's Suture Techniques Contributions:

- A new method for closed approach face and body liftings - a new alternative to classic excision lifts.
- Scarless, skin punctures only - no incisions and excisions.
- Mini-invasive, no downtime.
- Beautification and rejuvenation.
- When needed tissue augmentation is performed using patient's tissue - a new alternative without implants.
- Can be used in cosmetic, aesthetic and plastic-reconstructive surgery.
- Downtime is shortened from weeks into some days. No bruising, no danger of hematoma formation, no nerve damage, no scars.
- The suture methods became possible after creating special curved semi-elastic, semi-blunt needles.

Serdev needles were specially designed and developed for best use and have the following qualities:

- Elastic curve (the curve can not be changed when using pressure).
- Smooth surface (does not cut periosteum).
- Cone semi-blunt tip (trauma is minimized).
- Length and thickness depending on application from 50 to 250 mm.

Surgical threads were selected and best results were obtained with the Bulgarian polycapromide sutures Polycon, which are ensuring semi-elastic fixation of movable to non-movable tissue, they do not cut through the tissue like other available non elastic surgical threads, we have tried on experiment. Preferred thread qualities were - short elasticity, absorbable within two years - after final fibrosis formation, anti-microbial action. Our test have shown that only Polycon ensures that qualities. Polycon offers thread thickness depending on application - 3/0, 0, 2, 4, 6, 8.

Contributions

Serdev Suture® Techniques are the first lifting method to replace scarring classic excision liftings as a complete method for scarless closed approach liftings on total face and body where movable fascias (holding skin by trabecular system) can be lifted and fixed to non-movable periosteum, tendons and fascias.

Bibliography

1. Serdev NP. "Forehead Subperiosteal Masklift in Combination with McIndoe Facelift Technique and Profile Correction". The 7th IPRAS Congress European Section, Berlin, Germany (1993).
2. Serdev NP. "Year 1994, suture suspensions for lifting or volume augmentation in face and body". (English version), presented at the 2nd Annual Meeting of the National Bulgarian Society for Aesthetic Surgery and Aesthetic Medicine, Sofia, 18 March 1994". *International Journal of Surgical* 1.1 (2001): 2561-2568.
3. Serdev N. "Accessories to Face Lifting. II International Symposium of Updating on Skin Aesthetic, Sao Paulo, Brazil (1994).
4. Serdev NP. "Temporal SMAS lift without skin excision". AAARS Annual Meeting, New Orleans, USA, (1994).
5. Serdev NP. "Temporal SMAS Lifting of the Face. Life Surgery Workshop". Unidad Medica Clinica Del Country, Bogota D.C., Colombia, (1999).
6. Serdev NP. "SMAS Lifting of the Face by Minimal Incisions – the Serdev Technique. 42 Life Surgery Workshop sponsored by International Academy of Cosmetic surgery and the Balkan Academy of Cosmetic Surgery, held at the Krilig Clinic in Caracas, Venezuela (1999): 12-18.
7. Serdev NP. "Principles of Face Beautification, Ier Congresso Internacional de Cirurgia Cosmetica, Buenos Ares Argentina (1999).
8. Serdev NP. "Temporal SMAS lift, Lecture and Life Demonstration, 1st World Congress of Cosmetic Surgery with Life Demonstrations, Edsa Shangri-La Manila and Quezon City Medical Center (2000).
9. Serdev N. "Live Surgery Workshop, SMAS Lifting of the face by minimal incision – Brow, Temporal, Medial, Lower - the Serdev Technique". The International Academy of Aesthetic Surgery and Aesthetic Medicine, The Krulig Clinic, Caracas, Venezuela (1999).

10. Serdev NP. "Temporal SMAS Lifting of the Face, Combined with Liposuction and Chin Augmentation Using Suture". Life Surgery Workshop, Tel Aviv, Israel (2000).
11. Serdev NP. "Principles of face beautification, The 3-rd World Congress of ISAS, Tokyo (2000): 9W58.
12. Serdev NP. "Lifting del SMAS con Una Pequenna Incision Temporal, VIIIas Jornadas Mediterraneas de Confrontaciones Terapeuticas en Medicina y Cirurgia Cosmetica, Sitges, Barcelona (2000).
13. Serdev N. "Scarless Brow Lift Using A Special Suture". Presentations - 3rd World.
14. Serdev N. "Auriculoplasty for beautification - a post-congress workshop, Asia Pacific Craniofacial Association. Third Conference, Shanghai, P.R. China (2000).
15. Serdev N. "Principles of Face Beautification, XIas Jornadas Mediterraneas De Confrontaciones Terapeuticas En Medicina y Cirugia Cosmetica, 21-25. 03. 2001, Congress of Cosmetic Surgery with Live Surgical Demonstrations". *International Journal of Cosmetic Surgery* 2.4 (2001).
16. Serdev NP. "Tratamento De Flacides Cutanea Abdominal Com Filos Elasticos Serdev /Scarless Serdev Suture Methods For Abdominal Skin Flaccidity, 12 Congresso Brasileiro Medicina Estetica - 15 - 18 June 2005, Salvador". *International Journal of Cosmetic Surgery* (2006).
17. Serdev NP. "Scarless Serdev Suture Method In Prominent Ears (Bulgarian), Original Papers". *International Journal of Surgical* 9.4 (2009): 1-9.
18. Serdev NP. "Breast Lift: My Methods Presentations from the Congress "VI Sharing with the Experts" - San Salvador". *International Journal of Cosmetic Surgery* 9.2 (2009): 1-39.
19. Serdev NP. "Serdev Suture Techniques Breast Lift Original Papers". *International Journal of Cosmetic Surgery* (2009): 1-3.
20. Serdev NP. "Minimally Invasive Author Technique for Breast Lift Without Scars Using Sutures Abstracts - The First World Multidisciplinary Congress on Cosmetic Surgery and Medicine". *International Journal of Cosmetic Surgery* (2010): 1.
21. Serdev NP. "Eyebrow lifting by suture (from "Serdev Sutures. Scarless face and body liftings)". *International Journal of Esthetic Dentistry* 11.3 (2011): 1-2.
22. Serdev NP. "Brow lifting to the upper temporal line 1.5 cm". *International Journal of Esthetic Dentistry* 12.1 (2012): 1-62.
23. Serdev NP. "Brow lifting with fixation to the upper temporal line at the hairline". *International Journal of Esthetic Dentistry* 1 (2012): 3-6.

Volume 3 Issue 7 July 2021

© All rights are reserved by Nikolay P Serdev.