



Hepatoprotective Effect of *Balanites aegyptiaca* Extract against Paraquat-Induced Liver Toxicity

Mohammed A Hussein^{1*}, Amira M Mohamed², Aya O Mohamed², Eman E Jaafar², Mai W Abdelazem², Marwa R Hassan², Mennatallah M Mohamed², Mennatallah N Mostafa², Nada M Ahmed², Rana M El tweeki², Reem M El zoghby², Ali A Ali³ and Naglaa A Gobba⁴

Received: March 24, 2021

Published: April 29, 2021

© All rights are reserved by **Mohammed A Hussein., et al.**

¹Biochemistry Department, Faculty of Applied Medical Sciences, October 6 University, Sixth of October City, Egypt

²Department of Medical Laboratories, Faculty of Applied Medical Sciences, October 6 University, Sixth of October, City, Egypt

³Vice President of Post Graduate Studies, October 6 University, Sixth of October City, Egypt

⁴Pharmacology Department, Faculty of Pharmacy, MUST University, Sixth of October City, Egypt

***Corresponding Author:** Mohammed A Hussein, Biochemistry Department, Faculty of Applied Medical Sciences, October 6 University, Sixth of October City, Egypt.

Abstract

Paraquat-induced liver fibrosis involves two factors, direct injury by oxygen free radicals and indirect injury by inflammatory cells and fibroblasts. This study was carried out to examine the prophylactic potential of the *Balanites aegyptiaca* seeds water extract (BASWE) on paraquat-induced injury in rat. Oral administration of BASWE (100 and 200 mg/kg b.w.) to paraquat treated rats normalize significantly the serum levels of hepatic enzymes AST, ALT and ALP activity as well as liver TBARS, NO, TNF- α and IL-1 β . Oral administration of BASWE also exhibited its capacity to replenish the paraquat-induced decreased GSH levels and enhance increase in IL-10 and SOD activity.

The present results proved the protective effect of BASWE against paraquat-induced liver fibrosis by suppression of miR-122a and miR-192 gene expression as well as normalized the liver histology.

Keywords: *Balanites aegyptiaca*; Hepatoprotective; Paraquat; Cytokines; Antioxidant Enzymes; Inflammatory Mediators; miR-122a; miR-192

Abbreviations

AST: Aspartate Aminotransaminase; ALT: Alanine Aminotransaminase; ALP: Alkaline Phosphatase; TBARS: Thiobarbituric Reactive Substances; NO: Nitric Oxide; TNF- α : Tumor Necrosis Alpha; IL-1 β : Interleukin-1 β ; GSH: Reduced Glutathione; IL-10: Interleukin-10; SOD: Superoxide Dismutase

Introduction

Paraquat (1, 1'-dimethyl-4, 4' bipyridinium dichloride) is widely used as a nonselective herbicide, but it has toxic effects on various organs, including lung, liver and other organs [1]. Also, oxidative stress of paraquat by redox cycling led to produce superoxide radical [2,3] and cause lung and liver damage and kidney failure [3].

For over four thousand years *Balanites aegyptiaca* have been planted in Egypt. In the tombs of the Twelfth Dynasty [4] stones of the fruit were offered as votive offerings.

Cook, *et al.* [5] has indicated the high amount of sugar, protein, fats, minerals and vitamins in the *Balanites Aegyptiaca* fruit pulp. The total sugar of fruits pulp, as reported by the NRC [6], ranges from 40 to 70%, and contains about 5% proteins and 0.1% fat. Abdulrazak, *et al.* [7] have investigated the mineral contents of *Balanites aegyptiaca* fruit pulp.

The concentrations of were found to be 24.4, 6.33, 1.58, 0.542, 1.81 and 1.23 g/kg dry basis (DM), respectively [7].

The fruits of *Balanites aegyptiaca* are highly rich in saturated acids which can be used as cooking oil. It also contains steroids (saponins, sapogens, diosgenes), usually used for the production of contraceptives, corticoids, anabolic and other sex hormones as the raw materials for the industrial production [8].

In some skin diseases, *Balanites aegyptiaca* is also employed in curing leucoderma. In addition, the fruits and leaves are used to treat the syphilis, yellow fever, and bilharzia [9].

Balanites aegyptiaca contains large amounts of soluble tannins [10], polyphenols [11,12] and flavonoids [13] that excellent source of scavengers of reactive oxygen species and antioxidants. These reports led us to investigate other pharmacological functions of *Balanites aegyptiacas*. There are no reports on liver toxicity induced by hepatoprotection of *Balanites aegyptiaca* seeds Extension of our research on neutral products' biological significance [15-18]. In this study, we sought to estimate the preventive effects of *Balanites Aegyptiaca* seeds water extract for liver injury induced by intraperitoneal injection paraquat.

Materials and Methods

Materials

Chemicals

Paraquat dichloride and vitamin C were purchased from Sigma-Aldrich, USA. Paraquat dichloride was injected intraperitoneally in a dose of 50 mg/kg into intact animals [19].

Plant material

Balanites aegyptiaca seeds were brought from the local market in Cairo and characterized by prof. Heba A. Elgezawy, Faculty of Pharmacy, October 6 University.

Preparations of the water extract

This was prepared by extracting 0.5 kg of air-dried crashed *Balanites aegyptiaca* seeds using hot water in ratio 1:10. The extraction was carried out at 50°C for 2h with stirring at regular intervals. It was filtered into a low pressure to give viscous mass and evaporated to dryness. The extract was kept in airtight containers in a deep freeze maintained at 4°C until the time of further use.

Animals

A 30 adult female albino rats (180 ± 20 gms), were purchased from NCI, Cairo University. The conditions in the animal house were acclimatized. Standard diet and water *ad libitum* were provided to animals. Rats observed daily throughout the experimental work.

Experimental set up

This experiment was carried out to investigate, repeatedly for 2 weeks, the prophylactic potential of water extracts from *Balanites aegyptiaca* seeds against Paraquat induced hepatotoxicity in vivo, of the *Balanites aegyptiaca* seeds. For intragastric intubation of rats a 3g percent suspended solution was developed. Animal groups each of six rats were treated daily for 14 days as follows: For the following groups:

- **Group I:** Standard control was given 5 mL of saline p.o.
- **Group II:** Positive control was given 5 mL of saline p.o.
- **Group III:** WEBAS (100 mg/kg b.w.) was treated with a single daily dose of suspended water [20].
- **Group IV:** WEBAS (200 mg/kg b.w.) was treated with a single daily dose of suspended water.
- **Group V:** vitamin C (1 g/kg b.w.) was treated with a single daily dose of suspended water [21].

At day 13, i.e. one day before the last treatment, animals of all groups were fasted for 18h. At day 14, one hour after the last dose of drug treatment, all animals in groups II, III, IV and V received Paraquat dichloride (50 mg/kg.b.w.) [19].

Biochemical assays

Serum levels of glutamic-oxaloacetic transaminase (GOT) [22], glutamic-pyruvate transaminase (GPT) [22] and alkaline phosphatase (ALP) [23].

Liver specimens

At the end of the experiment, cervical decapitation sacrificed rats from each group. The liver specimens were quickly retrieved and gently opened with a scrapper, rinsed using ice-cold isotonic saline to remove all blood cell types and clots, then blotted between 2 filter documents and divided one part in biological liver GSH estimations [24], superoxide dismutase (SOD) [25], TBARS [26] and Nitric oxide [27].

Estimation of cytokines

Liver cytokines

TNF- α [28], interlinkin-1 β (IL-1 β) [29] and interleukin-10(IL-10) [30] were detected using a Multiskan Ascent UV microplate reader (Thermo Electric Corp., Shanghai, China) enzyme related immune test technique as per instructions from the manufacturer. The enzyme associated immunoassay (ELISA). Added acid stopped the reaction and a microplatform reader measured the absorption at 450 nm.

MicroRNAs extraction

A kit column miRNeasy kit (Qiagen, USA) was used to mix the 200- μ l serum sample with the 1000 μ l QiAzol solution and the microRNA extraction process was carried out in accordance with the manufacturers kit protocol. Finally, the extraction product was kept at -80°C in a freezer for later use.

cDNA synthesis and quantitative real time-PCR to detect miR-122a and miR-192

According to the manufacturer’s instructions, total RNA was prepared with an RNeasy® Mini Kit (QIAGEN, Germany). The integrity of RNA with NanoDrop2000 was verified (1.8 - 2.0; NanoDrop2000, Thermo, city, state). RNA (1 μ g), as detailed in the manufacturer’s instructions, was transcribed with a miScript II RT (Qiagen, Germany). An FastStart Universal SYBR Green PCR Master (ROX) was performed with a total volume of 10 μ L on a MxPro 3000 pp quantitative real-time PCR (qRT-PCR) test used

for measuring miR-122a and miR-192 RNA extracted from serum samples (Agilent, Palo Alto, USA). The following conditions were applied: initial denaturation at 95°C for 10 min. 40 cycles of three-step PCR (95°C at 15 sec, 55°C for 30 sec and 72°C for 30 sec) BGI supplied all primers (The Beijing Genomics Institute). For all genes, the primary sequences (5’-3’’) were shown in table 1.

miRNAs gene	Gene sequence
miR-122a	Forward:5’-CTCAACTGGTGTCTGGAGTCGGCAA TTCAGTTGAGCAAACA CCACACT-CCAGCTGGGTG- GAGTGTGACAATGG/56-FA M/TTCAGTTGAG- CAAAC ACC/31IABL FQ-3’ reverse 5’-TTCAGTTGAGCAAACACC-3’
miR-192	forward:5’-CTCAACTGGTGTCTGGAGTCGGCAAT TCAGTTGAGGGCTG TCAACACTCCAGCTGGGCTG ACCTATGAATTG/56FAM/TTCAGTTGAGCAGCTG CT/3IABLFQ-3’ reverse: 5’-TTCAGTTG AGCAAACAC-C-3’
RNU6B	forward 5’-CTC GCT TCG GCA GCA CA- 3’, reverse 5’AAC GCT TCA CGA ATT TGC GT-3’

Table 1: The primer sequences of miRNAs gene.

Histopathology assessment

Liver samples were isolated and preserved in formalin 10% then routinely processed to be embedded in paraffin. 5-mm thick paraffin sections were cut and stained with hematoxylin-eosin (HE) for light microscopic analysis according to the method of Bancroft and Steven [31].

Statistical analysis

All the grouped data were statistically evaluated with SPSS/13 software. Hypothesis testing methods included one way analysis of variance (ANOVA) followed by least significant difference (LSD) test. P values of less than 0.05 were considered to indicate statistical significance. All the results were expressed as mean \pm SD for six separate determinations.

Results

The hepatotoxic, paraquat significantly produced severe liver damage as indicated by a marked increase in serum AST, ALT and

ALP as compared with the control group. Treatment with *Balanites aegyptiaca* seeds water extract (100 and 200 mg/kg) and Vitamin C (1 g/kg b.w.) caused significant reduction AST, ALT and ALP as compared with the positive control group and exhibited a significant hepatoprotective effect (Table 2) ($P \leq 0.05$).

Group	AST (U/l)	ALT (U/l)	ALP (U/l)
Normal control (5 mL saline)	22.65 ± 3.52 ^a	13.45 ± 1.77 ^a	277.9 ± 9.78 ^a
Positive Control Paraquat dichloride (50 mg/kg b.w.)	83.46 ± 4.66 ^e	48.70 ± 6.08 ^e	865.50 ± 33.98 ^e
<i>Balanites aegyptiaca</i> seeds (WEBAS) (100 mg/kg b.w.)	64.3 ± 6.11 ^d	31.63 ± 4.52 ^d	577.35 ± 23.06 ^d
<i>Balanites aegyptiaca</i> seeds (WEBAS) (200 mg/kg b.w.)	35.25 ± 3.82 ^b	17.62 ± 2.49 ^b	315.44 ± 21.72 ^b
Vitamin C (1 g/kg b.w.)	47.80 ± 4.17 ^c	21.65 ± 2.90 ^c	516.32 ± 17.60 ^c

Table 2: Levels of serum aspartate aminotransaminase (AST), alanine aminotransaminase (ALT), alkaline phosphatase (ALP) in normal and experimental groups of rats.

Paraquat was given intraperitoneally as a single dose of 50 mg/kg.b.w. to 18 h fasted animals. It was given to all groups except the normal one. The extracts (100 and 200 mg/kg.b.w.) were orally given daily for 2 weeks and the last dose of each drug was given 1h before paraquat administration. Values are given as mean ± SD for groups of six animals each. Data followed by the same letter are not significantly different at $P \leq 0.05$.

Table 3 showed the levels of liver reduced glutathione (GSH), superoxide dismutase (SOD), thiobarbituric reactive substances (TBARS) and Nitric oxide (NO) of normal and experimental groups of rats. The levels of GSH and SOD in paraquat-treated rats were significantly lower as well as a significantly increase of liver TBARS and NO as compared with the control group ($P \leq 0.05$), whereas paraquat-treated rats which treated with the *Balanites Aegyptiaca* seeds water extract (100 and 200 mg/kg) and Vitamin C (1 g/kg b.w.) restored the altered values to the near normalcy as compared with the positive control group. The effect was more pronounced in the paraquat-treated rats which treated with *Balanites Aegyptiaca* seeds water extract (200 mg/kg).

Group	GSH mg/g protein	SOD	TBARS (nmol/mg protein)	NO (Umol/g tissue)
Normal control (5 mL saline)	13.65 ± 1.24 ^a	163.98 ± 9.87 ^a	196.56 ± 15.44 ^a	9.43 ± 0.83 ^a
Positive Control Paraquat dichloride (50 mg/kg b.w.)	4.65 ± 0.87 ^d	57.90 ± 4.16 ^e	513.98 ± 17.60 ^e	27.64 ± 4.31 ^d
<i>Balanites aegyptiaca</i> seeds (WEBAS) (100 mg/kg b.w.)	9.54 ± 1.03 ^c	127.48 ± 14.86 ^c	253.71 ± 13.70 ^c	15.44 ± 2.25 ^c
<i>Balanites aegyptiaca</i> seeds (WEBAS) (200 mg/kg b.w.)	11.80 ± 2.60 ^b	136.09 ± 10.76 ^b	234.90 ± 9.50 ^b	13.64 ± 2.05 ^b
Vitamin C (1 g/kg b.w.)	8.70 ± 1.08 ^c	110.76 ± 11.25 ^d	271.33 ± 14.66 ^d	16.70 ± 1.88 ^c

Table 3: Levels of liver reduced glutathione (GSH), superoxide dismutase (SOD), thiobarbituric reactive substances (TBARS) and Nitric oxide (NO) in normal and experimental groups of rats.

Paraquat was given intraperitoneally as a single dose of 50 mg/kg.b.w. to 18 h fasted animals. It was given to all groups except the normal one. The extracts (100 and 200 mg/kg.b.w.) were orally given daily for 2 weeks and the last dose of each drug was given 1 h before paraquat administration. Values are given as mean ± SD for groups of six animals each. Activity is expressed as: 50% of inhibition of pyrogallol autooxidation per min for SOD and the obtained values were divided by the protein concentration. Data followed by the same letter are not significantly different at $P \leq 0.05$.

Table 4 showed the levels of liver tumor necrosis alpha (TNF- α), interleukin-1 β (IL-1 β) and interleukin-10 (IL-10) in liver. The level of hepatic TNF- α , IL-1 β and IL-10 in paraquat-treated rats was significantly higher than normal rats, whereas paraquat-treated rats which treated with the *Balanites Aegyptiaca* seeds water extract (100 and 200 mg/kg) and Vitamin C (1 g/kg b.w.) restored the altered values to the near normalcy ($P \leq 0.05$) as compared with the positive control group.

Serum miR-122a and miR-192 gene expression in paraquat-treated rats were higher than those in the control group ($P < 0.05$). Treatment with *Balanites Aegyptiaca* seeds water extract (100 and 200 mg/kg) and Vitamin C (1 g/kg b.w.) significantly decreased the expression levels of miR-122a and miR-192 as compared to paraquat-treated rats (Figure 1 and 2).

Group	TNF- α (pg/g tissue)	IL-1 β (pg/g tissue)	IL-10 (pg/g tissue)
Normal control (5 mL saline)	18.90 \pm 2.98 ^a	32.65 \pm 5.32 ^a	21.90 \pm 2.65 ^a
Positive Control Paraquat dichloride (50 mg/kg b.w.)	64.77 \pm 6.15 ^e	107.25 \pm 9.80 ^e	6.80 \pm 0.76 ^e
<i>Balanites aegyptiaca</i> seeds (WEBAS) (100 mg/kg b.w.)	28.32 \pm 3.45 ^c	52.39 \pm 4.08 ^c	14.57 \pm 2.47 ^c
<i>Balanites aegyptiaca</i> seeds (WEBAS) (200 mg/kg b.w.)	23.60 \pm 2.85 ^b	40.26 \pm 3.48 ^b	18.90 \pm 2.54 ^b
Vitamin C (1 g/kg b.w.)	35.28 \pm 4.59 ^d	63.80 \pm 4.75 ^d	11.63 \pm 1.92 ^d

Table 4: Levels of liver tumor necrosis alpha (TNF- α), interleukin-1 β (IL-1 β) and interleukin-10 (IL-10) in normal and experimental groups of rats.

Paraquat was given intraperitoneally as a single dose of 50 mg/kg.b.w. to 18h fasted animals. It was given to all groups except the normal one. The extracts (100 and 200 mg/kg.b.-w.) were orally given daily for 2 weeks and the last dose of each drug was given 1h before paraquat administration. Values are given as mean \pm SD for groups of six animals each. Data followed by the same letter are not significantly different at $P \leq 0.05$.

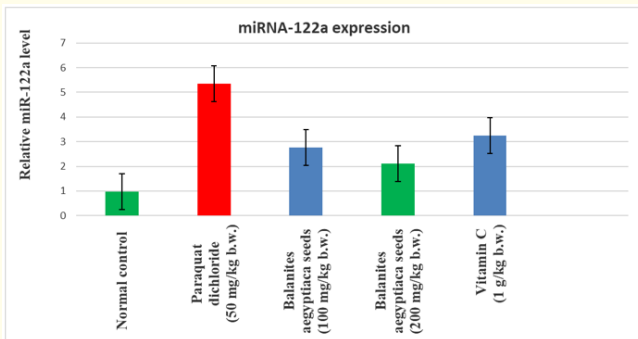


Figure 1: Effect of *Balanites aegyptiaca* seeds extract and Vitamin C on serum miRNA 122a expression in rats. Data (n = 3 per group) are presented as mean \pm SD. * $p < 0.05$.

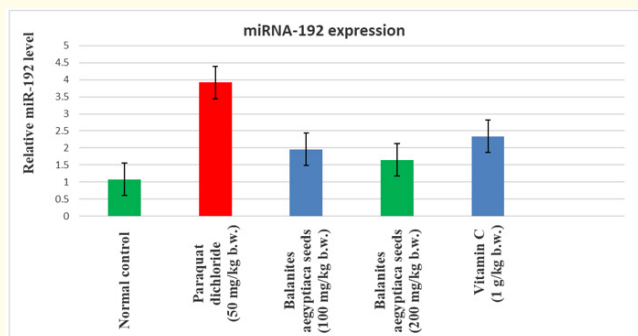


Figure 2: Effect of *Balanites aegyptiaca* seeds extract and Vitamin C on serum miRNA 192 expression in rats. Data (n = 3 per group) are presented as mean \pm SD. * $p < 0.05$.

Figure 3a-3e showed Sections stained with hematoxylin and eosin (H&E; 200 X) histological examination of rats livers of different groups compared to control group. (Figure 3a) negative control group Showed section in liver with unremarkable pathological changes. Also, figure 3b showed scattered apoptotic bodies (the black arrows). the portal tracts are expanded by inflammatory cells and fibrosis in group II which received a Paraquat dichloride (50 mg/kg b.w.) for a 15-day period. In addition, figure 3c showed congested dilated blood vessels (the arrow) in group III which treated with *Balanites aegyptiaca* seeds (100 mg/kg b.w.) for a 15-day period. Finally, figure 3d and 3e showed normal architecture with unremarkable pathological changes in groups IV and V which treated with *Balanites aegyptiaca* seeds (200 mg/kg b.w.) and Vitamin C, respectively.

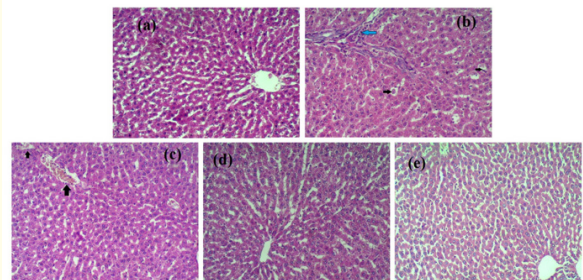


Figure 3: Sections stained with hematoxylin and eosin (H&E; 200 X) histological examination of rats livers of different groups compared to control group (a): negative control group (I); (b), Group II: positive control: (was received a Paraquat dichloride (50 mg/kg b.w.) for a 15-day period; (c): Group III: Was treated with *Balanites aegyptiaca* seeds (WEBAS) (100 mg/kg b.w.) for a 15-day period. (d); Group IV: Was treated with *Balanites aegyptiaca* seeds (WEBAS) (200 mg/kg b.w. for a 15-day period. (e); Group IV: Was treated with Vitamin C (1 g/kg b.w. for a 15-day period).

Discussion and Conclusion

Paraquat is a widely used broad spectrum herbicide which is toxic to man [32] and laboratory animals [33]. Paraquat toxicity is characterized by delayed development of liver lesions, which progresses to interstitial fibrosis [34]. Paraquat toxicity appeared to result from cyclic reduction-oxidation of the herbicide with subsequent generation of superoxide radicals. Superoxide radicals may nonenzymatically dismutate to singlet oxygen, which reacts with unsaturated lipids in cell membranes to form lipid hydroperoxides. The spontaneous decomposition of lipid hydroperoxides to lipid free radicals initiates the membrane destructive process of lipid peroxidation [35]. Previous studies show that oxidative strain happens during fibrosis and probably contributes to paraquat-induced liver injury [36]. Previous studies show that antioxidants, including N-acetylcysteine, vitamin E, silymarin, and quercetin, decrease lipid peroxidation and partially ameliorate liver injury, but the effects of antioxidants on fibrosis remain controversial [37]. Our results show a significant increase in liver enzyme activity and indicate a deteriorated integrity of the hepatocellular membrane which could end with liver dysfunction. This effect has also been shown by our findings on the liver of treatment rats. As we have confirmed from previous studies, the activation of cell molecular damage on paraquat exposure has been shown to be functional and biochemical changes, which are liver damage [33,34] and increased liver enzymes activity [35].

From these findings, it is evident that the water extract of *Balanites aegyptiaca* seeds was able to reduce all the elevated biochemical parameters as a result of hepatotoxin challenge, indicating improvement of the functional status of the liver. Significant change only suggests hepatic impairment, for example in the classical enzymes of AST, ALT and ALP because these are reliable liver toxicity indications [38]. An increase in ALP may be caused by altered skeletal muscle metabolism [39]. ALP levels are, however, useful to evaluate the lysosomal changes in vivo as marker enzymes [37].

Protective effects due to the treatment of *Balanites aegyptiaca* seed with water extract have strongly shown the potential for extracts to prevent and/or reduce any leakages of markers, to condition hepatocytes to accelerate parenchymal cell regeneration, to preserve plasma membrane integrity, and thus to restore the levels of these enzymes [37].

The magnitude of the effects vary greatly between the various plant extracts, depending on oxidative stress biomarkers SOD, GSH, NO and TBARS. The decreasing activity of the paraquat-treated rats, and increased levels of GSH, NO and TBARS in the liver tissue while the use of water extracts from *Balanites aegyptiaca*, prevented dramatic modifications in paraquat-induced SOD, GSH, NO and TBARS. *Balanites aegyptiaca* extracts significantly contributed to the intracellular antioxidant defence system through the use of single oxygen and hydroxylic radicals as strong consumers.

The role of paraquat-induced liver injury is known to be critical for the peroxidation of the lipid [40] and one of their end products is TBARS. TBARS can therefore be used in lipid peroxidation measurements. The content of the liver TBARS was significantly increased by the administration of acute paraquat [37,41]. Pre-treatment of the rats with *Balanites aegyptiaca* extract substantially lower the TBARS level of the liver tissue and support its free radical scavenging property and antioxidative effects in the anti-lipid peroxide potential of the *Balanites aegyptiaca*. It may be due to the presence of polyphenols [11,12] and flavonoids [13] which are excellent reactive scavengers, and which have a promising antioxidant effect [14] that the *Balanites aegyptiaca* can have a hepatitis protective effect.

The normal oxidative stress and elevation of liver TBARS and NO resulting in cell failure and metabolism resulting in ROS. It demonstrates that paraquat poisoning at a concentration of ROS induces cell production and thus promotes the synthesis of active cell activation and releases a large number of pro-inflammatory mediators, proteases and chemokines.

ROS expression is greatly increased in cells at this time. ROS can cause liver necrosis alpha (TNF- α) and interleukin-1 β (IL-1 β) releases, infiltrations and activations, and inhibition of interleukin-10(IL10) through NF κ B, which can accelerate environmental damage to the body and lead ultimately to organ dysfunction and failure. The results of He., *et al.* [42] on the effects of paraquat on alveolar epithelial cells, which can support the views of this experiment, are basically consistent with the results of this experiment.

Balanites aegyptiaca extract significantly reduces both TNF- α and IL-1 β and normalises IL-10. Its free radical scavenging, anti-inflammatory and antioxidative properties support the anti-inflammatory potential of *Balanites aegyptiaca*. Steroid (saponin, saponin, diosgenins) [8] can be the cause of the anti-inflammatory effects of *Balanites aegyptiaca*. Hussein, *et al.* [43] have reported the inhibition of some cytokines to anti-inflammatory activity of steroidal saponins in rats.

Our research has shown that miR-122a and miR-192 were highly expressed in paraquat treated group of rats, in line with previous studies. These results showed that miR-122a and miR-192 changes were previously diagnosed than hepatic markers. The miR-122a and miR-192 have been examined by Antoine, *et al.* to identify patients with liver injury admitted to hospital for the first time [44]. They showed that miR-122a is increased in these patients as a highly specific liver biomarker. Significantly inhibited serum miR-122a and miR-192 expression are also *Balanites Aegyptiaca* extract.

The activation of nuclear factor kappa induced by *Balanites aegyptiaca* diosgenin could abrogate tumour necrotic factor alpha (TNF α) -Light-chain enhancer of activated B cells (NF-kB) and of transcription 3 (STAT3) signal transducer induced by interleukin 6 induced by transcription cells (IL-6) [45]. The inhibition of miR-122a and miR-192 through diosgenin administration reported by Yuan Meng, *et al.* [46].

MiR-122a and miR-192 were not reported earlier in my knowledge and this study is perhaps the first such observation. The inhibition of *Balanites aegyptiaca* extract in paraquat-treated rats.

The histological findings of the study show, in rats with paraquat-induced liver toxicity, that *Balanites aegyptiaca* extract affected liver structure recovery. Indeed, in rats treated with *Balanites aegyptiaca* extract treated groups, the extent of fibrosis and a reduction of star infiltration was significantly reduced compared with that treated with paraquat. The hepatoprotective effect of *Balanites aegyptiaca* water extract was confirmed by histological results.

The phytochemical screening of the *Aegyptiaca balanites* revealed that flavonoids existed. Flavonoids are natural products that

modulate enzyme activity and affect the behaviour of many cell systems and have significant antihepatotoxic, anti-inflammatory, even antitumor and anti-oxidant activity [47-54].

Finally, the results of this study show that *Balanites aegyptiaca* has a powerful liver protection in rat for hepatic damage induced by paraquat. This can be due to the anti-oxidant activity with the ability to scavenge free radicals and inhibit lipid peroxidation, cytokines, miR-122a and miR-192.

Ethics Approval and Consent to Participate

Ethical approval for the data collection was granted by the Research Ethics Committee at the Faculty of Applied Medical Sciences, October 6 University, Egypt (No. 20201202). No Humans were used studies that are base of this research, in-vivo study using rats only.

Consent for Publication

The authors gave consent for their data to be used in the article.

Competing Interests

The authors declare no conflict of interest, financial or otherwise.

Bibliography

1. Ahmed MM. "Radio and chemo protective properties of hesperidin against genotoxicity induced by gamma radiation and/or paraquat in rat bone marrow cells". *Journal of Radiation Research and Applied Sciences* 23 (2010): 233-244.
2. Tanner CM, *et al.* "Rotenone, paraquat, and Parkinson's disease". *Environmental Health Perspectives* 119 (2011): 866-872.
3. He X, *et al.* "Resveratrol inhibits paraquat-induced oxidative stress and fibrogenic response by Activating the nuclear factor erythroid 2-related factor 2 pathway". *Journal of Pharmacology and Experimental Therapeutics* 342 (2012): 81-90.
4. Hall JB, *et al.* "*Balanites Aegyptiaca*: A monograph". School of agriculture and forest sciences Publication Number 3. University of Wales, Bangor (1991).

5. Cook AJ, *et al.* "Nutrient content of two indigenous plant foods of Western Sahel: *Balanites Aegyptiaca* and *Maerua crassifolia*". *Journal of Food Composition and Analysis* 11 (1998): 221-230.
6. NRC. "Lost crops of Africa, Fruits". The National Academic Press. National Research. Council, Washington, D,C, USA (2008).
7. Abdulrazak S., *et al.* "Chemical and mineral composition in-vitro gas production, in-sacco Depredation of Indigenous Kenyan Browes". *Live Stock Research for Rural Development* 22 (2010): 2-12.
8. Ndoye M., *et al.* "Reproductive biology in *Balanites aegyptiaca* (L) Del, a semi-arid forest tree". *African Journal of Biotechnology* 3 (2004): 40-46.
9. Abdoun SOM. "Variation in morphological, physical and chemical constituents of *Balanites Aegyptiaca* fruits between geographical sites". M.SC. Thesis in Forest science, University of Khartoum, Sudan (2005).
10. Chapagain BP and Wiesman, Z. "Larvicidal activity of the fruit mesocarp extract of *Balanites Aegyptiaca* and its saponin fractions against *Aedes aegypti*". *Dengue Bulletin* 29 (2005): 203-207.
11. Berrahmouni N., *et al.* "The Great Green Wall for the Sahara and the Sahel Initiative: Building resilient landscapes in African drylands". In Genetic Considerations in Ecosystem Restoration Using Native Tree Species; Food and Agriculture Organization of the United Nations: Roma, Italy (2014): 15.
12. Govaerts C. "World Checklist of Zygophyllaceae". Royal Botanic Gardens: Kew, UK (2016).
13. Aubergon J. "Elements de réflexion pour une stratégie dans l'amélioration variétale des arbres fruitiers (exemple de l'abricotier)". *Fruits* 42 (1987): 725-734.
14. Soloviev P., *et al.* "Variabilité des caractères physico-chimiques des fruits de trois espèces ligneuses de cueillette, récoltés au Sénégal: *Adansonia digitata*, *Balanites Aegyptiaca* et *Tamarindus indica*". *Fruits* 59 (2004): 109-119.
15. El-gizawy A., *et al.* "Chemical Composition of the Essential oil of the Leaves of *Pimenta diocia* (L.) Merr. and *Pimenta racemosa* (Mill.) cultivated in Egypt and evaluation of their *in-vitro* antioxidant and antidiabetic". *International Journal of Phyto-medicine* 4 (2018): 226-234.
16. Hussein MA., *et al.* "Resveratrol Nanoemulsion: A Promising Protector Against Ethinylestradiol-Induced Hepatic Cholestasis in Female Rats". *Journal of Biomolecular Research and Therapeutics* 8 (2020): 1-7.
17. Hussein MA. "Cardioprotective effects of astaxanthin against isoproterenol-induced cardiotoxicity in rats". *Journal of Nutrition and Food Sciences* 5 (2015): 1-6.
18. Mahmoud RA., *et al.* "Resveratrol Nanoemulsion; A Promising regulator of TGFβ1 and TFF-3 Genes Expression in DSS-Induced Ulcerative Colitis in Rats". *Acta Scientific Nutritional Health* 5 (2021): 18-29.
19. Melchiorri D., *et al.* "Paraquat toxicity an oxidative damage". *Biochemical Pharmacology* 51 (1996): 1095- 1104.
20. Montasser AO., *et al.* "Protective effects of *Balanites Aegyptiaca* extract, melatonin and ursodeoxycholic acid against hepatotoxicity induced by methotrexate in male rats". *Asian Pacific Journal of Tropical Medicine* (2017).
21. Luo Z., *et al.* "Antioxidant and iron chelating agents in cerebral vasospasm". *Neurosurgery* 37 (1995): 1054-1061.†
22. Reitman S and Frankel A. "A colorimetric method for the determination of serum glutamic oxaloacetic acid and glutamic pyruvic transaminases". *American Journal of Clinical Pathology* 28 (1975): 56-52.
23. King EJ and Armstrong AR. "Calcium, phosphorus and phosphate". In Practical Clinical Biochemistry. Edited by: Varley H. New Delhi: CBS Publishers (1988): 458.
24. Chanarin I. Textbook of Laboratory Haematology: An Account of Laboratory techniques, Churchill Livingstone, New York (1989): 107.

25. Marklund S and Marklund D. "Involvement of the superoxide anion radical in the autoxidation of pyrogallol and a convenient assay for superoxide dismutase". *FEBS Journal* 47 (1974): 469.
26. Nichans WH and Samulelson B. "Formation of malondialdehyde from phospholipid arachidonate during microsomal lipid peroxidation". *FEBS Journal* 6 (1968): 126-130.
27. Miranda KM., *et al.* "A rapid, simple spectrophotometric method for simultaneous detection of nitrate and nitrite". *Nitric Oxide* 5 (2001): 62-71.
28. Beyaert R and Fiers W. "Tumor Necrosis Factor and Lymphotoxin". In *Cytokines*, A.R.M.-S. a. R. Thorpe, eds. Academic Press, San Diego (1998): 335-360.
29. Hupa KJ., *et al.* "AIM2 inflammasome-derived IL-1 β induces postoperative ileus in mice". *Scientific Report* 9 (2019): 10602-10611.
30. Wenjun O., *et al.* "Regulation and functions of the IL-10 family of cytokines in inflammation and disease". *Annual Review of Immunology* 29 (2011): 71-109.
31. Bancroft GD and Steven A. "Theory and Practice of Histological Technique". 4th ed. Churchill Livingstone, New York (1983): 99-112.
32. Hakim D. "This pesticides Is Prohibited in Britain". Why Is It [^]ti^u Being Exported? New York Times (2016).
33. Novaes RD., *et al.* "Effect of bark extract of *Ba. The effect of thysa cuspidata* on hepatic oxidative damage and blood glucose kinetics in rats exposed to paraquat". *Toxicology Pathology* 40 (2012): 62-70.
34. Akihiro H., *et al.* "Inhibitory activity of epigallocatechin gallate in paraquat-induced microsomal lipid peroxidation; a mechanism of protective effects of EGCg against paraquat toxicity". *Toxicology* 193 (2003): 143-149.
35. Amirshahrokhi K and Bohlooli S. "Effect of methylsulfonylmethane on paraquat-induced acute lung and liver injury in mice". *Inflammation* 36 (2013): 1111-1121.
36. Novaes RD., *et al.* "Acute paraquat exposure determines dose-dependent oxidative injury of multiple organs and metabolic dysfunction in rats: impact on exercise tolerance". *International Journal of Experimental Pathology* 97 (2016): 114-124.
37. Hussein MA and Abdel-Gawad SA. "In vivo Hepatoprotective Properties of Purslane Extracts on Paracetamol-Induced Liver Damage". *Malaysian Journal of Nutrition* 16.1 (2010): 160-170.
38. Omoniyi K and Mathew C. "Protective effects of Zingiber officinale against carbon tetrachloride and acetaminophen-induced hepatotoxicity in rats". *Phytotherapy Research* 20 (2006): 997-1004.
39. Olagunju J., *et al.* "Effects of isosaline extracts of *Tetrapleura tetraptera* and *Olxax subscorpioides* on certain biochemical parameters of albino rats". *Pharmaceutical Biology* 38 (2000): 87-94.
40. El-gizawy HA and Hussein MA. "Fatty acids Profile, Nutritional Values, Anti-diabetic and Antioxidant Activity of the Fixed Oil of *Malva parviflora* Growing in Egypt". *International Journal of Phytomedicine* 7 (2015): 219-230.
41. Reyes K., *et al.* "Curcumin protects against acute liver damage in the rat by inhibiting NF-KB, proinflammatory cytokines production and oxidative stress". *Biochimica et Biophysica Acta* 1770 (2017): 989-992.
42. He Y., *et al.* "Adiponectin ameliorates the apoptotic effects of paraquat on alveolar type II cells via improvements in mitochondrial function". *Molecular Medicine Reports* 14 (2016): 746-752.
43. Hussein MA., *et al.* "Synthesis of Cinnamyl and Caffeoyle Derivatives of Cucurbitacin-Eglycoside Isolated from *Citrullus colocynthis* Fruits and their Structures Antioxidant and Anti-inflammatory Activities Relationship". *Current Pharmaceutical Biotechnology* 18 (2017): 677-693.
44. Antoine DJ., *et al.* "Mechanistic biomarkers provide early and sensitive detection of acetaminophen-induced acute liver injury at first presentation to hospital". *Hepatology* 58.2 (2013): 777-787.

45. El-gizawy HA and Hussein MA. "Fatty acids Profile, Nutritional Values, Anti-diabetic and Antioxidant Activity of the Fixed Oil of Malva parviflora Growing in Egypt". *International Journal of Phytomedicine* 7 (2015): 219-230.
46. YuanMeng LI, *et al.* "Advancements in microRNA research in dyslipidemia". *Scientia Sinica Vitae* 50 (2020): 954-965.
47. Hussein MA. "Cardioprotective Effects of Astaxanthin against Isoproterenol-Induced Cardiotoxicity in Rats". *Journal of Nutrition and Food Sciences* 5 (2010): 335.
48. Hussein MA and Boshra SA. "Antitumor and structure antioxidant activity relationship of colchicine on Ehrlich ascites carcinoma (EAC) in female mice". *International Journal of Drug Delivery* 5 (2013): 430-437.
49. Hussein MA. "A Convenient Mechanism for the Free Radical Scavenging Activity of Resveratrol". *International Journal of Phytomedicine* 3 (2011): 459-469.
50. Hussein MA. "Anti-inflammatory effect of natural heterocycle glucoside vicine obtained from *Vicia faba* L. and its aglucone (divicine) and their effect on some oxidative stress biomarkers in Albino rats". *Free Radicals and Antioxidants* 2 (2012): 44-55.
51. El Bishbishy MH and Hussein MA. "Synthesis and Characterization of Novel Rutin Derivatives with Potential Antioxidant Properties". *International Research Journal of Pharmacy* 9.11 (2018): 31-36.
52. El-gizawy HA, *et al.* "Synthesis, Molecular Docking and Structure Antioxidant Activity Relationship of Novel Acridone Derivative with its Acetylcholine esterase Inhibition". *International Journal of Drug Delivery* 10 (2018): 25-35.
53. El-gizawy HA, *et al.* "Chemical Composition of the Essential oil of The Leaves of *Pimenta dioica* (L.) Merr. and *Pimenta racemosa* (Mill.) and Evaluation of Their in-vitro Antioxidant and Antidiabetic Activities". *International journal of Phytomedicine* 10 (2018): 226-234.
54. Mohamed FT, *et al.* "Resveratrol Nanoemulsion; A Promising Inhibitor against Mitogen-Activated Protein Kinase-Dependent Inflammation and Ameliorates Nicotine Induced-lung Toxicity in Rats". *Free Radical and Antioxidants* 10.1 (2020): 35-41.

Assets from publication with us

- Prompt Acknowledgement after receiving the article
- Thorough Double blinded peer review
- Rapid Publication
- Issue of Publication Certificate
- High visibility of your Published work

Website: www.actascientific.com/

Submit Article: www.actascientific.com/submission.php

Email us: editor@actascientific.com

Contact us: +91 9182824667