



The use of Intraoperative MRI for Transsphenoidal Resection of Pituitary Tumors: A Community Hospital Experience

Alvin Onyewuenyi¹, Andrew Fishman², Andrew Chenelle³, Taras Masnyk³ and Sheri Dewan^{3*}

¹Chicago Medical School, Rosalind Franklin University of Medicine and Science, Chicago, IL USA

²Northwestern Medicine Regional Medical Group, Department of Neurotology and Cranial Base Surgery, Winfield, IL USA

³Northwestern Medicine Regional Medical Group, Department of Neurosurgery, Central DuPage Hospital, Winfield, IL USA

*Corresponding Author: Sheri Dewan, Northwestern Medicine Regional Medical Group, Department of Neurosurgery, Central DuPage Hospital, Winfield, IL USA.

Received: October 05, 2023

Published: October 29, 2023

© All rights are reserved by Sheri Dewan, et al.

Abstract

Objective: This study aims to provide insight into the experiences of iMRI use in a community hospital setting and add to the growing literature of iMRI use for transsphenoidal resection of pituitary tumors.

Methods: A retrospective review of 56 patients who underwent iMRI guided transsphenoidal pituitary tumor resection at Northwestern Medicine Central Dupage Hospital (from November 2011 to April 2018) was performed.

Results: Gross total resection was found in 67% (n = 37) of patients who underwent iMRI. 33% (n = 19) did not achieve gross total resection of their pituitary mass. IMRI was used exactly one time during the case in 96% (n = 54) of patients. IMRI was used more than once during the case in 4% (n = 2) of patients. Post operative tumor residual was found in 32% (n = 6) of patients who had available post-operative MRI studies (n = 19).

Conclusions: Our study shows that iMRI can be useful in a community hospital setting to achieve gross total resection during transsphenoidal pituitary tumor resection. It also demonstrates the ability and need to utilize iMRI only one time during a case which lends itself to operative efficiency.

Keywords: Transsphenoidal; Pituitary Tumors; Intraoperative

Introduction

Intraoperative MRI (iMRI) has emerged as a beneficial technology to help achieve maximum outcomes and limit additional surgeries during transsphenoidal resection of pituitary tumors. Its use has been documented by many groups and institutions around the world with positive outcomes related to gross total resection and extent of resection [1,2]. IMRI provides high quality images

and increases the rate of optimal resection while reducing complications [3]. IMRI has the ability to target residual tumor during the operation and provide an opportunity for the surgical team to target additional resectable lesion, thereby optimizing surgical goals. This minimizes the need for potential future operations and maximizes operative resources for better quality of overall care. IMRI is helpful and can be incorporated effectively into the standard neu-

rosurgical operating room set up and arrangement for transsphenoidal pituitary tumor resection [4].

Previous authors have documented the benefit of iMRI to provide an expanded view of the surgical field, increased rates of gross total resection, extent of resection, and decreased amounts of residual tumor [5]. It is widely documented that due to the slower rates of tumor growth seen in many pituitary tumors, iMRI provides a useful adjunctive measure to achieve gross total resection. Transsphenoidal pituitary tumor resection can be technically difficult due to sometimes unpredictable infiltration of the tumor within vital nearby neurovascular structures, particularly the cavernous sinus. IMRI can identify remnants of disease that remain in high risk areas. Intraoperative decisions to leave residual tumor and potentially treat with adjunctive measures are one of the most useful benefits of iMRI as the information provided minimizes risk of overly aggressive manipulation in these high risk areas. The use of iMRI ultimately allows the surgeon to make present time decisions for the patient’s management while being safe and efficient [6-8].

The use of iMRI for transsphenoidal resection of pituitary tumors in a community hospital setting has not yet been published in the literature. Current papers in the literature include iMRI for pituitary tumor resection being used at an multidisciplinary academically supported institution [9]. Looking at how iMRI can be used in a community hospital setting is important and can add to the growing literature on iMRI use for pituitary tumor resection because it can serve as evidence for community hospital centers that would like to acquire this technology to improve patient outcomes and care.

The specific aim of this study is to report the utility of iMRI use in a community hospital setting for transsphenoidal pituitary tumor resection. Data analyzed includes; ability to achieve gross total resection, frequency of use, postoperative outcomes as well as a discussion of time requirements and iMRI associated complications.

Methods

We performed a retrospective review of a total of 56 patients who underwent iMRI guided transsphenoidal pituitary tumor resection over a period between November 2011 to April 2018

at Northwestern Medicine Central Dupage Hospital. We defined gross-total resection as removal of the pituitary tumor in its entirety as seen during intraoperative MRI use. The endoscopic endonasal transsphenoidal approach was used to resect all of the pituitary tumors in this study. The source of the patient data that was acquired for this study was through the use of electronic medical records. Intraoperative and post-operative MRI reports were interpreted and used during analysis. The type of MRI used during surgery was the Imirs Intraoperative MRI system which supports 1.5 to 3 Tesla. This study was approved by the institution’s review board (IRB #18-054). The reporting guideline for our study includes our results, discussions, and conclusions.

Results

All n=56 of patients were charted and broken down based on factors related to gross total resection status of their tumor and frequency of use of iMRI during their procedure. Of these 56 patients, 10 of them had documented post-operative MRI results in our data set and their outcomes related to identifiable tumor residual was charted as well.

Gross total resection was observed in 67% (n=37) of patients who underwent iMRI during the resection of their tumor. 33% (n=19) of patients who underwent iMRI did not achieve gross total resection of their pituitary mass (Figure 1). The reasons for not pursuing gross total resection in these patients are further outlined in the discussion section.

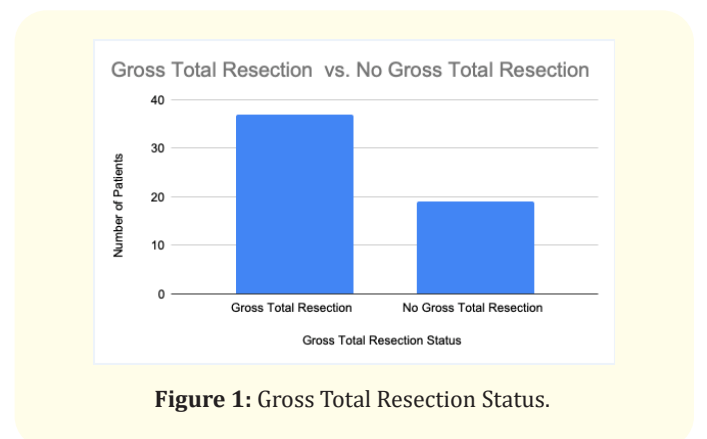


Figure 1: Gross Total Resection Status.

iMRI was used exactly one time in a single case in 96% (n=54) of patients during tumor resection. iMRI was used more than once in a single case in 4% (n = 2) of patients during tumor resection (Figure 2).

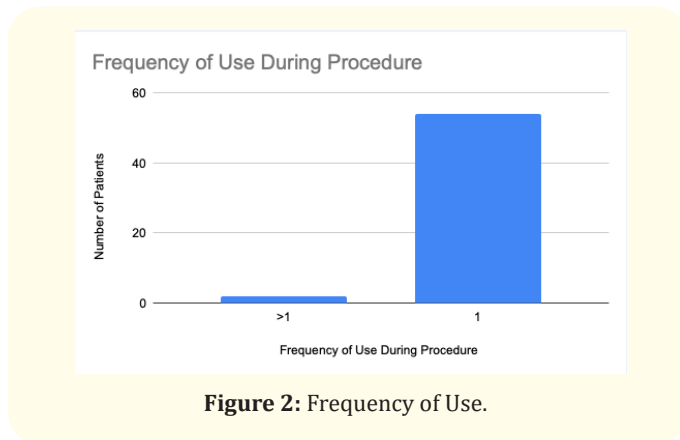


Figure 2: Frequency of Use.

Post-operative tumor residual was found in 32% (n = 6) of patients in our data set of n = 19 patients who underwent postoperative MRI (Figure 3).

Discussion

iMRI during transsphenoidal resection of pituitary tumors has the capacity to maximize outcomes in a busy community hospital setting. Our data shows that gross total resection was achieved and determined during surgery in the majority of our patients (67% compared to 33%). This shows that iMRI provides an advantage to help determine gross total resection of a pituitary mass during a case in real time. This has the potential to allow for maximal and safe complete removal of tumor bulk during transsphenoidal resection in addition to limiting overly aggressive resection in anatomically hazardous locations. The use of iMRI allowed our team to not only achieve maximum tumor resection, it also allowed the team to visualize decompression of vital nearby neurovascular structures that pituitary tumors usually adhere to. For example, decompression was able to be visualized in and around the cavernous sinus, carotid arteries, and optic apparatus.

Our study also shows that iMRI can be used typically only one time during a case. The frequency of iMRI use for our study was only one time during most cases and this allowed our team to be efficient with achieving the best results for our patients. iMRI was typically used once during two key phases of the operation. It was

used to identify intraoperative residual tumor location or to confirm gross total resection before closing. Using iMRI multiple times during a case is a rare occurrence. Using iMRI only one time during a case can help to avoid excessive increase to the usual operative timing for a surgeon and increases in personnel needed for managing the iMRI.

We also found that there was a significant difference in the evidence of post-operative tumor residual detected. Our study demonstrates that the use of iMRI to achieve gross total resection in real time has the ability to decrease the presence of residual tumor postoperatively in patients. Our study found that there may be an enough positive correlation between these two measures as residual tumor was found in less patients post-operatively (32% compared to 68%). The reason for residual tumor being seen post-operatively in 32% of our patients may hinge on the variety of presentations and extent of tumor involvement especially in unresectable high risk regions. In these cases it is our impression that iMRI facilitates the decision to cease excessive manipulation thereby improving safety and possibly decreasing time spent during surgery in specific cases.

Limitations

One of the limitations of our study was that our data set that looked at postoperative MRI outcomes for residual tumors, was seen in a smaller sample size of n=19 compared to our initial group of n=56 patients that underwent iMRI. A larger sample size may allow for a better understanding of postoperative residual tumor occurrence amongst patients undergoing iMRI for resection of pituitary tumors. We suggest that this be studied further.

Conclusion

iMRI use during transsphenoidal resection of pituitary tumors is a valuable tool that helps achieve gross total resection during cases. It also provides a medium in which during surgery, important neurovascular structures typically encased within the tumor can be decompressed effectively. There are currently no papers in the literature that show iMRI use for transsphenoidal pituitary tumor resection at a community hospital. Our paper is the first to document outcomes for iMRI use for transsphenoidal pituitary tumor resection in a community hospital setting. Our paper shows that iMRI used in a community hospital setting can be beneficial to clinical practice by providing effective resection of tumors for patients while limiting frequency of use during surgery, lending to operative efficiency.

Bibliography

1. Hlaváč M., *et al.* "Ten years' experience with intraoperative MRI-assisted transsphenoidal pituitary surgery". *Neurosurgical Focus* 48.6 (2020): E14.
2. Zaidi HA., *et al.* "The utility of high-resolution intraoperative MRI in endoscopic transsphenoidal surgery for pituitary macroadenomas: early experience in the Advanced Multimodality Image Guided Operating suite". *Neurosurgical Focus* 40.3 (2016): E18.
3. Fomekong E., *et al.* "Raftopoulos C. Intraoperative 3T MRI for pituitary macroadenoma resection: Initial experience in 73 consecutive patients". *Clinical Neurology and Neurosurgery* 126 (2014): 143-149.
4. Gerlach R., *et al.* "Feasibility of Polestar N20, an ultra-low-field intraoperative magnetic resonance imaging system in resection control of pituitary macroadenomas: lessons learned from the first 40 cases". *Neurosurgery* 63.2 (2008): 272-285.
5. Serra C., *et al.* "Pituitary surgery and volumetric assessment of extent of resection: a paradigm shift in the use of intraoperative magnetic resonance imaging". *Neurosurgical Focus* 40.3 (2016): E17.
6. Strange F., *et al.* "10 Years' Experience of Using Low-Field Intraoperative MRI in Transsphenoidal Surgery for Pituitary Adenoma: Results of the Swiss Pituitary Registry (SwissPit)". *World Neurosurgery* 136 (2020): e284-e293.
7. Berkmann S., *et al.* "Intraoperative MRI and endocrinological outcome of transsphenoidal surgery for non-functioning pituitary adenoma". *Acta Neurochirurgica* 154.4 (2012): 639-647.
8. Tabakow P., *et al.* "Surgical treatment of pituitary adenomas using low-field intraoperative magnetic resonance imaging". *Advances in Clinical and Experimental Medicine* 21.4 (2012): 495-503.
9. Jones PS and Swearingen B. "Intraoperative MRI for Pituitary Adenomas". *Neurosurgery Clinics of North America* 30.4 (2019): 413-420.