



Expansile Sinonasal Ancient Schwannoma: A Rare Cause of Long-Standing Globe Displacement

MD Abdullah¹, Kartik Manoj Multani^{1*}, Kanakam Chandrakanth¹,
Boyina Jagadishwar Rajesh² and Milap Shah³

¹Resident, Department of neurosurgery, Yashoda Superspeciality hospital,
Secunderabad, India

²Consultant, Department of Neurosurgery, Yashoda Hospital, Secunderabad, India

³Consultant and Head, Department of Pathology, Yashoda Hospital, Secunderabad,
India

*Corresponding Author: Kartik Manoj Multani, Resident, Department of
neurosurgery, Yashoda Superspeciality hospital, Secunderabad, India.

DOI: 10.31080/ASNE.2022.05.0541

Received: November 18, 2021

Published: September 16, 2022

© All rights are reserved by **Kartik Manoj
Multani.**

Abstract

Ancient schwannomas are slow growing variant of benign schwannoma. Although commonly occur in head and neck region, the Sinonasal ancient schwannoma with extension into orbit are sparsely reported. Histopathologically, these tumours develop degenerative changes due to their long-standing nature and thus can be confused with malignant nerve sheath tumours or sarcoma. Diagnosis is made by combined HPE and Immunohistochemical analysis that reveals diffuse S-100 positive staining. Treatment of choice is surgical gross total excision. We present to the best of our knowledge, a fourth in world literature report of Sinonasal ancient schwannoma with intraorbital extension presenting to our OPD with abaxial displacement of involved globe and was treated with pure endoscopic gross total removal by transnasal route.

Keywords: Expansile; Sinonasal; Long-Standing; Globe Displacement

Introduction

Schwannomas, more precisely called Neurilemmomas [1] are benign, encapsulated, well differentiated, and slow growing lesions, that originates from the nerve sheath, more specifically "the Schwann cells". These lesions are usually benign in nature and malignant changes are observed sparsely [2]. The head and neck region constitutes about 25-45% of all Schwannomas of which the most common involved structure is vestibulocochlear nerve [3]. Involvement of the Sinonasal tract is very rare, with less than 4% of the total head and neck schwannomas being from this region [4]. Histopathologically, these lesions can be classified into 5 broad categories namely Common, Plexiform, Cellular, Epithelioid and Ancient [5] recently a sixth variant Melanotic was described by Patil, *et al.* [6].

An Ancient schwannoma (AS) is a rare, slow growing variant of a benign schwannoma. Less than 100 cases of Ancient Schwannomas

have been reported to date with only 3 such cases originating from Sinonasal region. To the best of author's knowledge this paper is fourth in world literature that reports a Sinonasal ancient schwannoma in a 52-year-old female who presented with gradually progressive swelling involving forehead and orbit causing long standing globe displacement which was successfully treated by transnasal endoscopic excision.

Case Report

A 52-year-old female presented with intermittent headache for 8 years and a swelling over right eye with its deviation for 6 years. The headache was insidious in onset and localized to the right frontal region. She noticed a small swelling at inner canthus of right eye two years after the headache began, and it slowly grew to involve the bridge of nose. Patient also complained of diplopia which started within four months of her noticing the swelling. She had also noted significant watering of her right eye, to the point

where she looked to be perpetually crying. The right eye was shifted downward and outward in the orbit, but there was no protrusion of the globe out of the orbital socket. There was history of recurrent sinusitis and upper respiratory tract infections over the course of her disease.

On examination, a globular swelling was seen over the right eye extending to the nasal bridge. The skin over the swelling was non ulcerated and free. It was not possible to get under the swelling. There was abaxial deviation of eye, but no proptosis was appreciable. There was no history of nasal discharge or epistaxis. Visual acuity and extraocular movements were normal in both eyes, but she demonstrated a relative afferent pupillary defect in her right eye, and binocular diplopia was present (Figure 1).

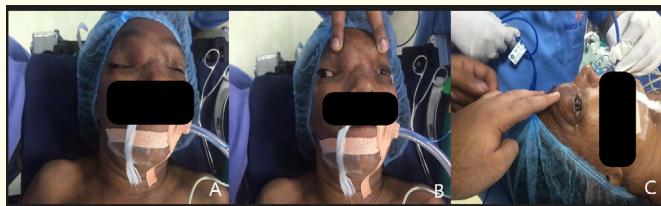

Figure 1: (A) soft tissue swelling at superomedial aspect of right orbit extending to bridge of nose causing (B) abaxial displacement of right eye (C) without any proptosis of globe.

MR Imaging revealed an T1 isointense, T2 heterogeneously hypointense and moderately enhancing soft tissue density in the bilateral frontal sinuses, more on the right side. The lesion was causing expansion of the frontal sinuses and erosion of anteroinferior and posteroinferior walls of the sinus. Erosion of the cribriform plate was also noted along with thinning of left and destruction of right lamina papyracea. Middle meatus was obliterated due to the mass. There was also suspected intracranial extension of the lesion in paramedian location adjacent to the cribriform plate. A high suspicion of malignant lesion vs fungal granuloma was raised.

CT PNS confirmed destruction of anteroinferior and posteroinferior bone of frontal sinus along with complete destruction of frontal sinus floor and left lamina papyracea post contrast CT showed a mildly enhancing soft tissue mass with extensions described as above (Figure 2 and 3).

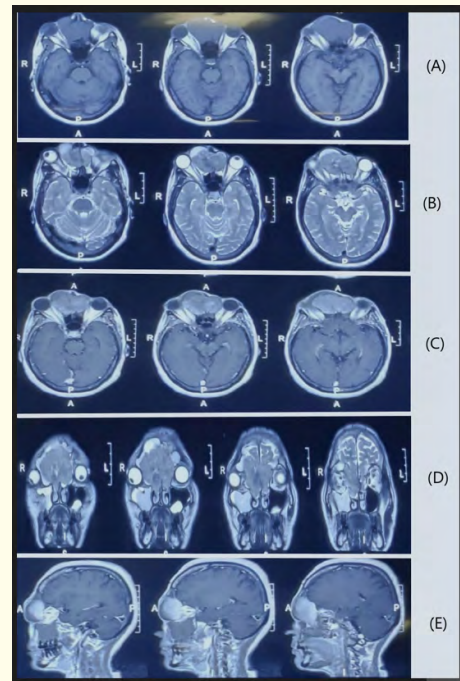


Figure 2: Preoperative MRI showing a well circumscribed Sinonasal mass with extension into right orbit with globe displacement. The mass is isointense on T1 (A), Hypointense on T2 (B/D), and moderately enhancing on post gadolinium injection (C/E).

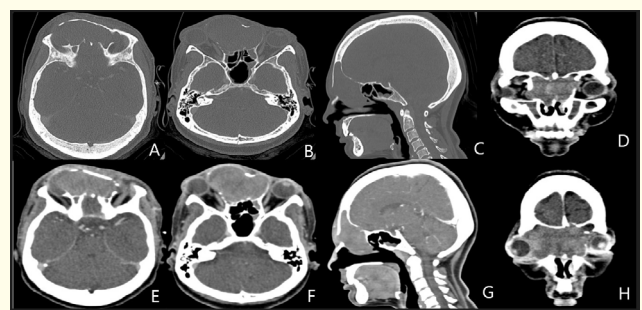


Figure 3: Preoperative plain CT PNS (A/B/C): destruction of anteroinferior and posteroinferior wall with floor of frontal sinus with destruction of right lamina papyracea. Preoperative contrast CT PNS (D-H): Mildly enhancing mass arising from frontal sinus extending into anterior ethmoids, sphenoid sinus and right orbit with suspected intracranial extension parallel to cribriform plate.

Patient underwent Transnasal endoscopic piecemeal excision of tumor under general anesthesia, intraoperatively tumor was firm and friable, moderately easy to decompress, avascular, well circumscribed (Figure 4) and a doubtful pedicle was seen along anterior ethmoid foramen; so most probably the schwannoma was arising from Anterior ethmoidal nerve, a branch of nasocilliary division of trigeminal nerve. The nerve fibers were not separately identified from the tumor and thus were not preserved during the resection.

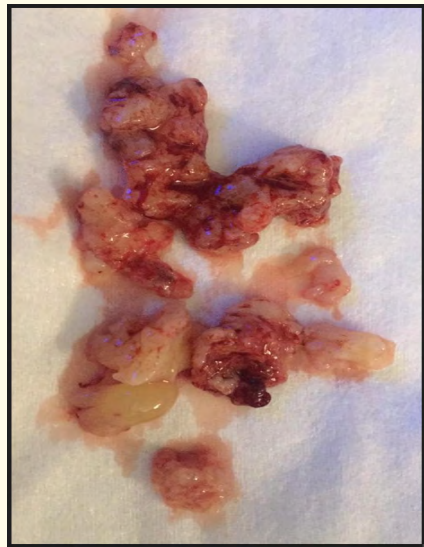

Figure 4: Intraoperatively tumour was firm, friable, avascular and was removed in piecemeal.

The excised tumor was sent for biopsy and histopathological examination. Histopathology revealed tumor tissue composed of spindle cells arranged in fascicles, with spindle to pleomorphic nuclei, with multinucleation and eosinophilic cytoplasm. Hyalinization of vessels, mitosis and hemorrhagic areas were noted. Immunohistochemistry revealed diffuse positivity for S100, and negative for SMA (smooth muscle actin) and Desmin. Thus, diagnosis of Ancient schwannoma was made (Figure 5). Postoperative period was uneventful and patient recovered well without any morbid neurodeficits. Patient remained disease free at three months follow up.

Discussion

The earliest note of “Ancient” schwannoma (AS) was made by Ackerman and Taylor in 1951 [7]. These tumours are nothing

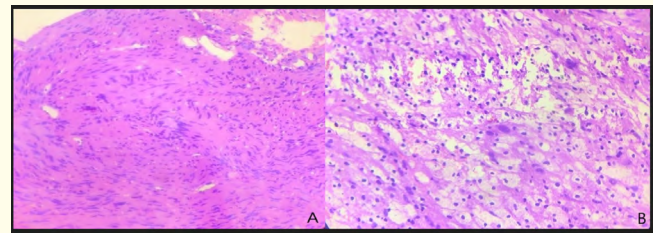


Figure 5: Histopathological examination revealed (A) schwannoma with Verocay bodies (B) Foamy macrophages suggestive of degenerative changes.

but a long-standing Schwann cell tumour with degenerative changes. On HPE these tumours show pathognomonic features of schwannoma like capsulated tumour with areas of compact spindle cells (Antoni A), hypocellular less orderly areas (Antoni B) and diffuse S-100 positivity on IHC with associated occasional bizarre degenerative changes attributed to “ageing” of tumour like marked atypia and hypercellularity, pleomorphism, large Schwann cells with hyperchromatism, and other degenerative changes like cyst formation, calcification, haemorrhage and hyalinisation [8]. Due to presence of these confounding degenerative features these tumours can be misdiagnosed as “Sarcomas” and “Malignant peripheral nerve sheath tumours” (MPNST). Sarcomas in contrast to AS are unencapsulated, not associated with any nerves and immunoreactive to SMA with S-100 negative. Similarly, MPNST can be differentiated from AS by uniform presence of cytologically malignant features, extensive hypercellularity, markedly high mitotic activity, areas of necrosis, with local infiltration in surrounding tissues [9,10]. Treatment of choice for AS is surgical excision preferably Gross Total with an attempt to preserve function of parent nerve.

AS of Sinonasal origin forms a distinct sub spectrum of the disease and present as a challenge to treating surgeons. These lesions grow in cavity and attain a significant large size before they become symptomatic and patient needs a consult, also these are long standing expansile lesion which can grow into neighbourhood compartments and can become intraorbital or intracranial. Due to these extensions and large size, there are multiple Blind areas during the surgery which can result in subtotal resection and thus resultant increased risk of regrowth and malignant transformations. Also, these lesions are thought to arise from

peripheral ramifications of sensory trigeminal nerves that supply nose and sinus mucosa and thus, unlike schwannomas arising from large nerves, the visualization and preservation of trigeminal branches is very difficult and thus results in risk of injury to same which may result in a very minimally morbid sensory deficit to patient. Surgical approach mainly depends on extensions of tumour and can range from Microscopic resection to endoscopic assisted to pure endoscopic resection. Few anecdotal evidence suggest a pivotal role of pure endoscopic surgery in achieving a better and less morbid excision of Sinonasal schwannoma [3].

To the best of author’s knowledge, till date only 3 cases with HPE proven AS of Sinonasal origin is described, all were treated with surgical gross total resection with a favourable postoperative course. Ours’ is fourth in world literature case describing Sinonasal AS and first in world literature that shows expansile nature of disease resulting in orbit intrusion and globe displacement. In present case the tumour most likely was arising from anterior ethmoid nerve before it enters anterior ethmoid foramen and was removed in toto by pure endoscopic approach.

Author and year	Location and Extension of tumour	Expected Site of Origin	Surgical Approach	Resection result	Follow up
Jonas., <i>et al.</i> 2006	Left nasal cavity till choana with septum deviation to right	NA	Microscopic	GTR	No Recurrence F/U duration NA
Kodama., <i>et al.</i> 2010	Left Posterior nasal cavity with extension into sphenoid sinus + thinning of posterior sphenoid wall	Nasopalatine Nerves	Transnasal Endoscopic	GTR	No recurrence at 2-year Followup
Panigrahi., <i>et al.</i> 2015	Left nasal cavity + left maxillary, ethmoid and sphenoid sinus + thinning of left lamina papyracea	NA	Transnasal Endoscopic	GTR	No recurrence at 2-year followup
Present study	B/L nasal cavity (right > left) + intracranial (parallel to cribriform plate) + Right intraorbital with destruction of right lamina papyracea + bowing of left lamina papyracea	Anterior Ethmoidal Nerves	Transnasal Endoscopic	GTR	No recurrence at 3 months f/u

Table 1: summary of Sinonasal ancient schwannoma published in literature till date.

Conclusion

Ancient schwannoma although rare should be kept in mind as a differential diagnosis for long standing expansile mass in Sinonasal cavity after ruling out other common nasal lesions like Polyps, Fungal granuloma etc. Although always benign in nature can lead to significant morbidity in patients. Diagnosed by Histopathologic evidence of degeneration in background of Schwann cell tumour with diffuse S-100 positivity. Treatment of choice remains gross total excision with microscopic or endoscopic technique; best possible approach to be chosen as per patient’s and tumour’s characteristics.

Bibliography

- Batsakis J. “Tumors of the head and neck: Clinical and pathological considerations”. *Baltimore, MD: Wiley* (1974): 231-249.
- SA Rasbridge NLB., *et al.* “Malignant nerve sheath tumour arising in a Benign Ancient Schwannoma”. *Histopathology* 14.5 (1989): 525-528.
- Kodama S., *et al.* “Ancient schwannoma of the nasal septum associated with sphenoid sinus mucocele”. *Auris, Nasus, Larynx* 37.4 (2010): 522-525.
- Hillstrom RP ZR and Jacobs JR. “Nerve sheath tumors of the paranasal sinuses: electron microscopy and histopathologic diagnosis”. *Otolaryngol Head Neck Surg* 102.3 (1990): 257-263.
- Klijanienko JCJ and Lagace R. “Cytohistologic correlations in schwannomas (neurilemmomas), including “ancient,” cellular, and epithelioid variants”. *Diagn Cytopathol* (2006): 517-522.
- Patil SK Chatura and Kasimsetty Chatura. “Schwannoma and its unusual variants - A histopathological study”. *Indian Journal of Pathology and Oncology* 3 (2016): 727-731.

7. Ackerman LV TF. "Neurogenous tumors within the thorax: A clinicopathological evaluation of forty-eight cases". *Cancer* 4 (1951): 669-691.
8. Shilpa B. "Ancient schwannoma-a rare case". *Ethiopian Journal of Health Sciences* 22.3 (2012): 215-218.
9. Gupta G., *et al.* "Malignant peripheral nerve sheath tumors". *Neurosurgery Clinics of North America* 19.4 (2008): 533-543.
10. Miettinen M. "From morphological to molecular diagnosis of soft tissue tumors". *Advances in Experimental Medicine and Biology* 587 (2006): 99-113.