



## Mucoepidermoid Carcinoma of Warthin's Like Variant Arising from Ectopic Salivary Tissue within an Intraparotid Lymph Node

Hussein AlZamel<sup>1\*</sup> and Imtiyaz Nawaz Bhat<sup>2</sup>

<sup>1</sup>Assistant Professor in Damascus University Syria and Consultant, Department of ENT, Al-Farwaniya Hospital, Ministry of Health, Kuwait

<sup>2</sup>ENT Surgeon, Department of ENT, Al-Farwaniya Hospital, Ministry of Health, Kuwait

**\*Corresponding Author:** Hussein AlZamel, Assistant Professor in Damascus University Syria and Consultant, Department of ENT, Al-Farwaniya Hospital, Ministry of Health, Kuwait.

**Received:** April 15, 2019; **Published:** June 07, 2019

### Abstract

Mucoepidermoid carcinomas are seen throughout all adult age groups, but are most common in middle age (30-60 years of age) [5]. However, it is the most common malignant tumour of salivary gland of childhood [4,5]. Overall, mucoepidermoid carcinomas account for 3-15% of all tumours: less than 10% of all major salivary gland tumours, 10-40% of minor salivary gland tumours but it is rarely found in ectopic salivary tissue. The Warthin tumour was the most common intraparotid lymph nodes. In this case we report a rare case of a 41 years old Egyptian male who presented with a very slow growing mass in the Left parotid region since 20 years. A CT scan was requested which showed intraparotid mass/lymph node. A preoperative fine needle aspiration suggested Warthin tumor. Patient was booked for surgery and underwent superficial Parotidectomy and specimen was sent for Histopathology but histopathology was reported as high grade mucoepidermoid carcinoma (based on a modified Brandwein scheme) oncocytic/Warthin-like variant with the bulk of the tumor was centered within the lymph node and was composed of epidermoid tumor cells with rare oncocytes lining multiple cystic cavities and also forming well defined islands (p63 IHC highlights the squamous differentiation) [Figure 3,4,5,6].

Metastasis from distant sites was ruled out clinically, and the diagnosis rendered was Mucoepidermoid carcinoma, high-grade, arising from ectopic salivary tissue in an intraparotid lymph node. Such cases are extremely rare and the presence of malignancies within lymph nodes may pose a diagnostic pitfall, which can affect patient management. Patient Underwent Total Parotidectomy as second stage surgery and second specimen was sent for Histopathology as was reported as normal parotid tissue as malignant tissue was already removed along with lymph node in first stage surgery.

**Keywords:** Intraparotid Lymph Node; Salivary Tissue; Parotid Tissue

### Introduction

The sites where can we find the ectopic salivary tissues are in the mastoid, middle ear, neck, intraparotid lymph nodes and pituitary region [1-4].

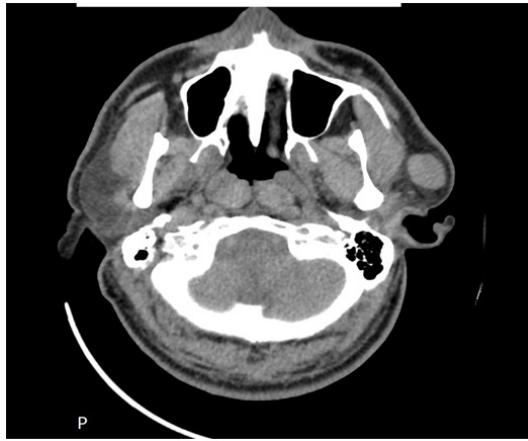
In this case, a rare case of Mucoepidermoid carcinoma arising primarily within lymph node of intraparotid is presented. To our knowledge, and to date, there have been only few similar cases reported in the literature.

A 41 years old nonsmoker Egyptian male with a mass on the Left parotid region since 20 years. There was no history of pain, facial weakness, tingling sensation of the face

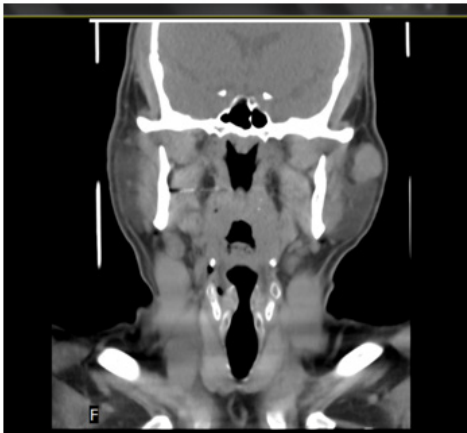On examination a 2.0 x 2.5cms, mass located in left parotid region. The mass was non tender, mobile, and firm with normal skin over it. No lymph nodes can be palpated. The facial nerve was intact.

Fine needle aspiration cytology (FNAC) was performed and reported as Warthin's tumor. The patient underwent a contrast enhanced CT to determine the extent of the lesion. The CT showed a well-defined lesion epicentered in the superficial lobe of the left parotid gland (Figure 1). A Left superficial parotidectomy was done. The tumour was superficial to the facial nerve and the postoperative period was uneventful and the facial nerve was intact. Histopathology was reported as "Sections show a high grade mucoepidermoid carcinoma (based on a modified

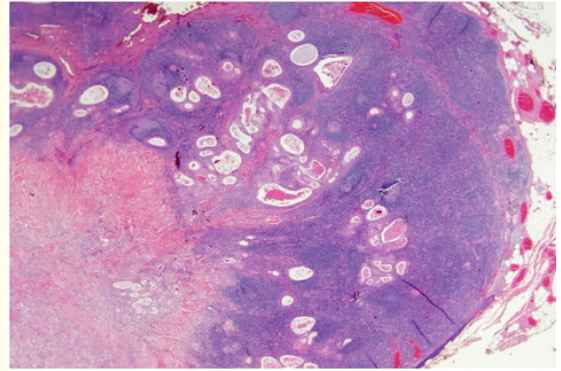
Brandwein scheme) oncocytic/Warthin-like variant with the bulk of the tumour centered within the lymph node and is composed of epidermoid tumour cells with rare oncocytes lining multiple cystic cavities and also forming well defined islands (p63 IHC highlights the squamous differentiation). The tumor component and the invasive front is predominantly solid with the cells being oncocytic with granular cytoplasm. Perineural invasion was present. S100 IHC was negative ruling out secretory carcinoma" [Figure 1-6].



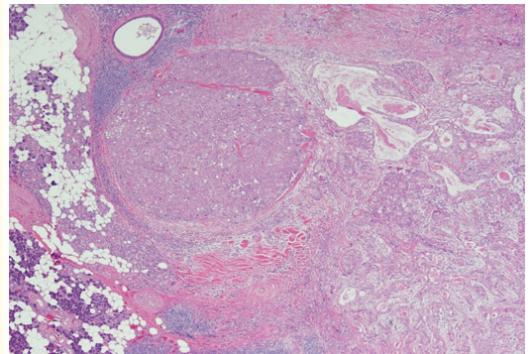
**Figure 1:** CT neck axial cut, well-defined oval-shaped mass involving the lobe of the Left parotid gland. The lesion shows an increase in density after IV contrast media injection.



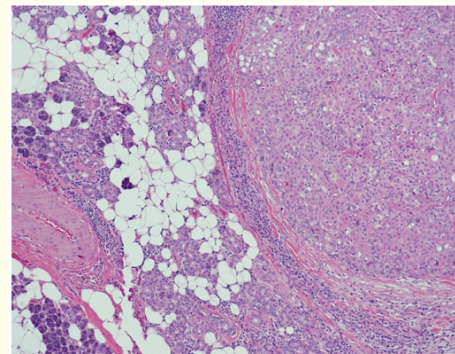
**Figure 2:** CT coronal section of the same patient showing vertical extension of the mass and involving superficial lobe of the left parotid gland.



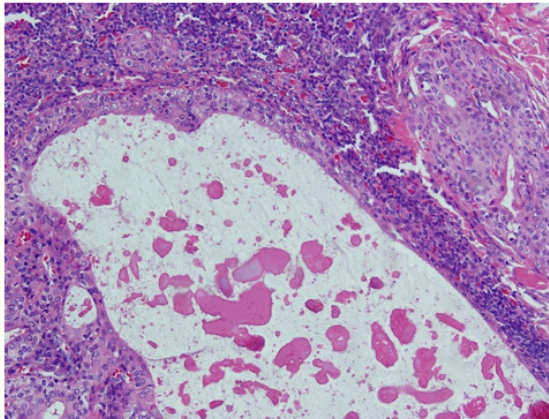
**Figure 3:** Mucoepidermoid carcinoma arising within a periparotid lymph node forming multiple cystic spaces and well defined islands. (Hematoxylin-eosin stain, X20).



**Figure 4:** Tumor invading into the parotid gland with a prominent oncocytic component forming solid sheets, nests, islands, duct-like structures, and cysts. (Hematoxylin-eosin stain, X40).



**Figure 5:** Mucoepidermoid carcinoma with prominent oncocytic tumor cells having granular cytoplasm and prominent nucleoli. (Hematoxylin-eosin stain, X100).



**Figure 6:** Cystic spaces and well defined tumor islands lined by epidermoid, intermediate and few clear type of malignant tumor cells within periparotid lymph node. (Hematoxylin-eosin stain, X200).

Metastasis from distant sites was ruled out clinically, and the diagnosis rendered was Mucoepidermoid carcinoma, high-grade, arising from ectopic salivary tissue in an intraparotid lymph node. Such cases are extremely rare and the presence of malignancies within lymph nodes may pose a diagnostic pitfall, which can affect patient management. Patient Underwent Total Parotidectomy as second stage surgery and second specimen was send for Histopathology as was reported as normal parotid tissue as malignant tissue was already removed along with lymph node in first stage surgery.

The patient was doing fine on follow up with mild facial paresis on the same side. He was referred to Cancer control center for further radio-chemo therapy as was discussed in tumour board prior to second stage surgery.

### Method

After performing the standard diagnostic workup, and Mucoepidermid carcinoma arising from ectopic salivary gland tissue intraparotid lymph nodes has been diagnosed. Total parotidectomy with or without neck dissection depending on lymph node metastasis should be done and the proposed treatment plan i.e combination of chemo radiotherapy.

### Discussion

This is a rare case of high grade Mucoepidermid carcinoma arising from ectopic salivary gland tissue intraparotid lymph nodes in healthy adult Egyptian patient with history of mass in left parotid region lasting for long time with no another complains

total parotidectomy two stages was performed and was completely resected with normal surrounding parotid tissue. The post-operative period was uneventful and one and half years follow up showed no recurrence and the facial nerve was intact.

A similar case of low grade Mucoepidermid carcinoma intraparotid lymph nodes was discussed by Smith., et al. in 1985 [1].

Ectopic salivary gland tissue can be found in many sites such as neck, ear, intralymph nodes in parotid or neck [1,3,4].

The malignant tumores arising from ectopic salivary tissue intra lymph nodes may provoke a quest to hunt for an unknown primary lesion, especially when it arises within a lymph node. Therefore, you need to be familiar with such possibilities.

The first possibility it is might be metastasis, So the pathologist and ENT specialist should be familiar with such cases and they must rule out a metastasis from distant sites. In our case the possibility of metastasis was ruled out clinically and radiology.

The second possibility it is might originated from parotid tissue and then infiltrated the lymph nodes.

In our case the histopathologist revealed the Mucoepidermid carcinoma was intraparotid lymph nodes, and the surrounding parotid gland tissue was not involved.

The third possibility the neoplasm originated from salivary gland tissue, then broke through the lymph node capsule and infiltrated inside lymph node, but in this possibility the most of tumor will be in parotid parenchyma, that mean the tumor centered in parotid parenchyma.

In our case the Mucoepidermid carcinoma was centered in lymph node.

### Conclusion

- Salivary gland neoplasms arising from ectopic salivary tissue are extremely rare and when malignant, a quest to find an unknown primary lesion may be triggered. Therefore, both the pathologist and clinician should be familiar with and consider such presentation only after a metastasis is unequivocally excluded.
- And if there is any suspicious of malignancy during surgery maybe you need frozen section.
- And we should put in our mind the possibility of ectopic salivary gland tissue (malignant or benign) intraparotid lymph node for parotid enlarged lymph nodes lasting for long time.

- And in case where a primary lesion is suspected, neck dissection and postoperative radiation therapy should be performed, along with long-term follow-up.

### Conflicts of Interest

No conflict of interest to declare by any of the authors.

### Funding

None.

### Ethical Approval

Written informed consent was obtained from the patient for publication of this case report and accompanying images. A copy of the written consent is available and can be reproduced whenever needed.

- All procedures performed in studies involving human participants were in accordance with the ethical standards of the institution.

### Bibliography

1. A Smith., *et al.* "Mucoepidermoid carcinoma arising in an intraparotid lymph node". *Cancer* 55.2 (1985): 400-403.
2. JG Batsakis. "Tumors of the Head and Neck: Clinical and Pathological Considerations". Lippincott Williams and Wilkens, 2nd edition (1979).
3. J Sáenz-Santamaria., *et al.* "Low grade mucoepidermoid carcinoma arising in cervical lymph nodes: a report of two cases with fine needle aspiration findings". *ActaCytologica* 47.3 (2003): 470-474.
4. F Martínez-Madrigal and C Micheau. "Histology of the major salivary glands". *The American Journal of Surgical Pathology* 13.10 (1989): 879-899.
5. A Kolokythas., *et al.* "Low-grade mucoepidermoid carcinoma of the intraoral minor salivary glands with cervical metastasis: report of 2 cases and review of the literature". *Journal of Oral and Maxillofacial Surgery* 68.6 (2010): 1396-1399.

**Volume 2 Issue 7 July 2019**

**© All rights are reserved by Hussein AlZamel and Imtiyaz Nawaz Bhat .**