



PEEK Implant: A Case Report Illustrating the Benefits for Correcting Craniosynostosis Asymmetry

Ogaga Urhie¹, Walid Radwan¹, Brandon Lucke-Wold², TJ Chin¹, Aaron Mason¹ and Rabia Qaiser^{1*}

¹Department of Neurosurgery, West Virginia University, Morgantown, USA

²Department of Neurosurgery, University of Florida, Gainesville, USA

*Corresponding Author: Rabia Qaiser, Department of Neurosurgery, West Virginia University, Morgantown, USA.

Received: October 22, 2018; Published: November 02, 2018

Abstract

Background: Unilateral coronal synostosis can cause aesthetically unappealing plagiocephaly, which often requires surgical correction. The techniques utilized for this operation have continued to evolve. Unfortunately, some patients who have fronto-orbital advancement will have residual asymmetry.

Case: We present a case of a 21 year-old female with residual asymmetry who was suffering from facial swelling and refractory trigeminal neuralgia. It was decided to perform an additional surgery with polyetheretherketone (PEEK) implant to restore normal symmetry and provide symptomatic relief.

Conclusion: The ideal fit PEEK implant provided excellent cosmetic results and the operation relieved her symptoms. We provide a detailed discussion on why PEEK implants are great options for these types of cases due to advanced pre-surgical planning technology, ease of placement, and durability over time.

Keywords: Unilateral Coronal Craniosynostosis; Facial Asymmetry; Trigeminal Neuralgia; Polyetheretherketone Implant

Background

A unilateral coronal synostosis is a congenital condition in which one side of the coronal suture prematurely closes. The result is a frontal plagiocephaly in which the affected side has an elevated and posteriorly displaced orbit and flat forehead while the unaffected side has a fuller forehead with a vertically narrower eye socket. Other symptoms may include dystopia from a raised eye, displacement of the ipsilateral ear, and contralateral nasal deviation [1]. The optimal time to correct this defect is between the ages of 6 and 12 months [2,3]. Open surgical techniques are often the gold standard, but the surgeon must be prepared to correct the deformity with a single surgery. Data shows increased morbidity rates if subsequent surgeries are needed due to supraorbital rim dystopia, temporal hollowing, and fronto-orbital relapse [2]. One

of the most common techniques used to correct this deformity is a fronto-orbital advancement with overcorrection. Unfortunately, patients who underwent this technique often still have residual facial asymmetry [4].

Here, we present a case of a 21-year-old woman with right-sided coronal synostosis that was treated when she was a child with the fronto-orbital advancement technique described above. She unfortunately required several surgeries and developed temporalis bunching and residual facial asymmetry. Due to these symptoms, it was decided to perform corrective surgery with a polyetheretherketone (PEEK) implant to make the skull symmetrical and re-suspend the temporalis muscle. The procedure and result are described below followed by a discussion of the benefit of PEEK implants for reconstruction surgeries.

Case

Our patient underwent a cranioplasty with right orbital advancement at the age of 6 months, but due to hardware failure, she required several subsequent surgeries. Her last surgery was at the age of 6 where she underwent a split thickness bone graft. She presented to our clinic summer 2017 with a four-day history of right-sided facial swelling and 5/10 right facial pain despite being adherent to Tegretol for underlying trigeminal neuralgia. On physical examination, she had a significantly misshapen right eye and a bunched right temporalis muscle. On CT imaging, the muscle was found to be inflamed with temporal bone sclerosis, which was thought to be the cause of her pain. Due to these debilitating symptoms, it was decided to perform corrective surgery.

The surgery was performed winter 2017. After an initial incision was made along the previous incision site, we found that our patient had a deformed and hyperostotic temporal bone. The scalp flap was raised anteriorly to the right superolateral orbital margin,

where the PEEK implant was later placed. Using curettes and periosteal elevators, the zygomatic arch and mastoid bones were then accessed. The temporalis muscle, which was scarred and folded in upon itself, was dissected from the scalp flaps and elevated out of the temporal fossa. The PEEK implant was set in place with three 6-0 midface Synthes set titanium screws. The construct was then thoroughly irrigated with a triple antibiotic solution. The temporalis muscle was re-suspended in the temporal fossa with 2-0 Prolene. The fascia was notably contracted due to the scarring and was scored to release the superior portion of the scar and allow the muscle to expand. The galea was closed with 2-0 Vicryl using a simple interrupted inverted pattern with placement of a JP drain posteriorly. The scalp was released anteriorly and posteriorly to close the field and the skin was closed on the left with a continuous Prolene suture while a simple interrupted pattern was used on the right. Our patient had an uneventful recovery, had excellent cosmetic outcome as seen by post-op imaging (Figure), and was discharged from the hospital.

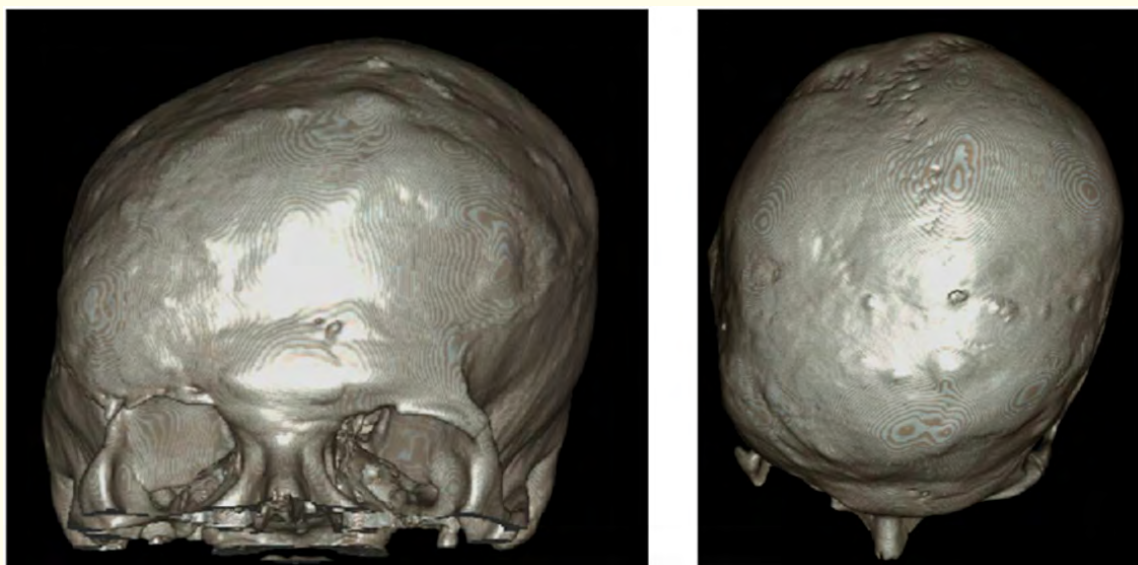


Figure: Post-op pictures showing successful closure around the PEEK implant.

Discussion

PEEK implants are widely used in craniofacial surgeries and yield satisfactory long-term results [5]. The advantages of using PEEK implants are that their physical properties closely resemble that of bone and they are radiolucent, which facilitates post-operative imaging [6]. In particular, PEEK implants have been shown to provide excellent symmetrical contour for craniosynostosis patients [7]. Typically, PEEK implants are surgically placed after bone maturity is reached [8]. In this report, our patient was 21 at time of presentation thus having full bone maturity. In older patients, the implant often must be placed with a staged approach to receive ideal symmetrical contouring [9]. Fortunately, the healing process following PEEK implant placement is typically quick and boney remodeling can be seen even at 2 weeks post-op [10].

Recent advances in 3D printing technology have allowed PEEK implants to be designed prior to the operation, which really cuts down on operating time [11]. The advancement in technology has also limited the risk of implant extrusion by allowing for the design to more carefully match the actual cranial defect [12]. This is especially important for patients that have already reached bone maturity, as the skull should not remold much around the implant [13]. The ideal fit PEEK implants are well known to have minimal tissue irritation [14]. By utilizing ideal fit implants, the skull is protected from any future trauma similar to if the bone had never been removed [15].

In conclusion, a PEEK implant was ideal for correcting the facial asymmetry and providing symptomatic relief. The patient was highly satisfied with the result. By utilizing advanced pre-surgical planning technology, the ideal PEEK implant was readily adapted for the defect, which allowed successful placement with minimal countering on no sites of extrusion.

Bibliography

- 1 Plooij JM., et al. "Unilateral craniosynostosis of the fronto-sphenoidal suture: a case report and a review of literature". *Journal of Cranio-Maxillo-Facial Surgery* 37 (2009): 162-166.
- 2 Selber JC., et al. "Long-term results following fronto-orbital reconstruction in nonsyndromic unicoronal synostosis". *Plastic and Reconstructive Surgery* 121 (2008): 251e-260e.
- 3 Mesa JM., et al. "Reconstruction of unicoronal plagiocephaly with a hypercorrection surgical technique". *Neurosurgery Focus* 31 (2011): E4.
- 4 Oh AK., et al. "Facial asymmetry in unilateral coronal synostosis: long-term results after fronto-orbital advancement". *Plastic and Reconstructive Surgery* 121.2 (2008): 545-562.
- 5 Jonkergouw J., et al. "Outcome in patient-specific PEEK cranio-plasty: A two-center cohort study of 40 implants". *Journal of Cranio-Maxillo-Facial Surgery* 44.9 (2016): 1266-1272.
- 6 Hanasono MM., et al. "Calvarial reconstruction with polyetheretherketone implants". *Annals of Plastic Surgery* 62.6 (2009): 653-655.
- 7 Ma IT., et al. "Outcomes of Titanium Mesh Cranioplasty in Pediatric Patients". *Journal of Cranio-Maxillo-Facial Surgery* 29.1 (2018): 99-104.
- 8 Radwan W., et al. "Unilateral Frontosphenoid Craniosynostosis: Case Report and a Review of the Literature". *Neurology (ECronicon)* 4.3 (2017): 80-83.
- 9 Sakamoto Y and Arnaud E. "Multiple Delayed Scalp Reconstruction for Complicated Cranial Defects". *Plastic and Reconstructive Surgery* 4 (2016): e836.
- 10 Singh R., et al. "Giant calvarial intraosseous angioliopoma: a case report and review of the literature". *Journal of Surgical Case Reports* (2016).
- 11 Tack P., et al. "3D-printing techniques in a medical setting: a systematic literature review". *Biomedical Engineering Online* 15 (2016): 115.
- 12 Larranaga J., et al. "Free flap reconstruction for complex scalp and forehead defects with associated full-thickness calvarial bone resections". *Craniofacial Trauma and Reconstruction* 5 (2012): 205-212.

- 13 Simon P, *et al.* "Craniofacial Prosthetic Reconstruction Using Polymethyl Methacrylate Implant: A Case Report". *The Journal of Indian Prosthodontic Society* 14 (2014): 303-307.
- 14 Ghosh S, *et al.* "Fronto-orbital reconstruction using polymethyl methacrylate implant". *National Journal of Maxillofacial Surgery* 8 (2017): 153-156.
- 15 Da Costa GC, *et al.* "A Unique Flask Design for Processing Cranial Prosthesis Using Heat Cured Acrylic - A Case Report". *Journal of Clinical and Diagnostic Research* 10 (2016): ZD14-ZD16.

Volume 1 Issue 1 November 2018

© All rights are reserved by Rabia Qaiser, *et al.*