



Intraepidermal Histiocytes as a Histologic Marker of Cutaneous Drug Rash

Bronagh Mc Gee^{1*} and Paul Hartel^{2,3}

¹University of Galway, School of Biological and Chemical Sciences, Ireland

²Sligo University Hospital, Department of Pathology, Ireland

³West Virginia University School of Medicine, USA

***Corresponding Author:** Bronagh Mc Gee, University of Galway, School of Biological and Chemical Sciences, Ireland.

DOI: 10.31080/ASMS.2025.09.2132

Received: June 15, 2025

Published: June 30, 2025

© All rights are reserved by

Bronagh Mc Gee and Paul Hartel.

Abstract

To evaluate the presence of intraepidermal histiocytes in drug reactions, we reviewed 20 cases of clinical drug rash and their histologic features. Rashes identified as drug-induced by a team of dermatologists were biopsied. Histologically, the prevalence of intraepidermal histiocytes were quantified using S-100 immunohistochemistry and compared with normal skin sections. We found that the prevalence of intraepidermal histiocytes in drug reactions is twice that of normal skin, as well as a small comparative sample of non-drug induced rashes. S-100 positive intraepidermal histiocytes may be a specific histologic and diagnostic marker for drug-induced rash.

Keywords: Cutaneous Drug Rash; Drug Eruption; Langerhans Cells; S-100

Introduction

Histologic features associated with drug rash include vacuolar interface dermatitis, perivascular lymphocytic infiltrate, eosinophils, dyskeratinocytes, spongiosis and epidermal hyperplasia. However, these features are non-specific and are also associated with other conditions including viral exanthem, graft versus host disease, connective tissue disease, allergic contact dermatitis, pityriasis rosea, secondary syphilis, and adult onset Still disease [1]. Cutaneous histiocytes play a crucial role as part of the monocyte-macrophage and dendritic cell system, including phagocytosis and antigen presentation to T lymphocytes. Cutaneous histiocytes include dendritic cells and macrophages in the dermis [1-3], and Langerhans cells in the epidermis [4]. Cutaneous intradermal histiocytes are reported in a specific subset of drug-induced rashes, such as interstitial granulomatous drug reaction (IGDR) and some

lichenoid drug reactions [2,3]. While intraepidermal histiocytes, or Langerhans's cells, have been associated with neoplasm, [4-6] they have not been reported in drug reactions.

We quantified intraepidermal histiocytes in clinically common drug reactions to assess their utility in the histopathologic diagnosis of these cases. Skin biopsies submitted to SUH histopathology laboratory for clinical drug rash over a one-year period were reviewed. Clinical details and histologic features were recorded. Intraepidermal histiocytes were quantified by light microscopy and S-100 immunohistochemistry per mm², with control cases of normal skin sections. Total number of intraepidermal histiocytes divided by total biopsy mm² gave an average histiocyte count per mm² of epidermis. Twenty patients, 11 male and 9 female, had a

mean age of 67 years with biopsies from trunk and upper and lower extremities. Histologic features included superficial perivascular chronic inflammation, increased eosinophils, and vacuolar interface dermatitis. Drug-induced rashes had a greater nearly two-fold prevalence of intraepidermal histiocytes compared with normal skin and non-drug rash cases.

Materials and Methods

Skin biopsies submitted by dermatologists to SUH histopathology laboratory for clinical drug rash in the year 2024 were identified by CoPath search ($n = 25$). Five cases were found to have non-drug induced diagnoses following histologic review (HPV infection = 2, Demodex infection = 1, Scabies infection = 1 and pityriasis rubra pilaris = 1). Age, gender, site of biopsy, and histologic features were recorded. Slides were stained with haematoxylin and eosin histochemistry and three histologic levels were examined for each case. Intraepidermal histiocytes were quantified per mm^2 . Due to background cutaneous inflammatory changes in drug rash biopsies, S-100 immunohistochemistry was applied to clearly identify intraepidermal histiocytes. Basal melanocytes were excluded from quantification. Control cases were normal skin sections, each of similar size, from apical skin tips of excision cases. Intraepidermal histiocytes per mm^2 by light microscopy were recorded. To control for biopsy size in study cases, the total number of high-power

fields of epidermis was divided by the appropriate microscope field size standard of 4 hpf/ mm^2 to determine the number of mm^2 per biopsy. Total number of intraepidermal histiocytes divided by total biopsy mm^2 gave an average histiocyte count per mm^2 of epidermis.

Results and Discussion

Patients ($n = 20$), 11 males and 9 females, ranged in age from 40 to 93 years ($m = 67$) and had biopsies from thigh (6), arm (5), chest (4), abdomen (3) and back (2). Histologic features were superficial perivascular chronic inflammation (11), increased eosinophils (10), vacuolar interface dermatitis (9) and spongiosis (6). Control cases of normal skin showed 4.6 intraepidermal histiocytes per mm^2 by light microscopy (range 1 to 11). Study biopsies had from 3 to 39.5 hpf ($m = 19$), with biopsy mm^2 ranging from 0.75 to 10 mm^2 ($m = 4.7$). S-100 immunohistochemistry in drug rash inflammatory skin cases showed intraepidermal histiocytes present, singly (range 1 to 131 ; $m = 44$), and in clusters (range 0 to 19 $m = 6$; Clusters were defined as 3 or more in a group or 3 or more linearly with no more than 2 squamous cells between each histiocyte; Figure 1). Intraepidermal histiocytes were 0.4 to 35/ mm^2 , $m = 12/\text{mm}^2$ and intraepidermal clusters ranged from 0 to 4.4/ mm^2 , $m = 1.4/\text{mm}^2$. The five non-drug rash cases (infection = 4, pityriasis rubra pilaris = 1) showed intraepidermal histiocytes ranged from 2 to 13/ mm^2 , $m = 6.5/\text{mm}^2$ and intraepidermal clusters ranged from 0.2 to 1.7/ mm^2 , $m = 1.1/\text{mm}^2$.

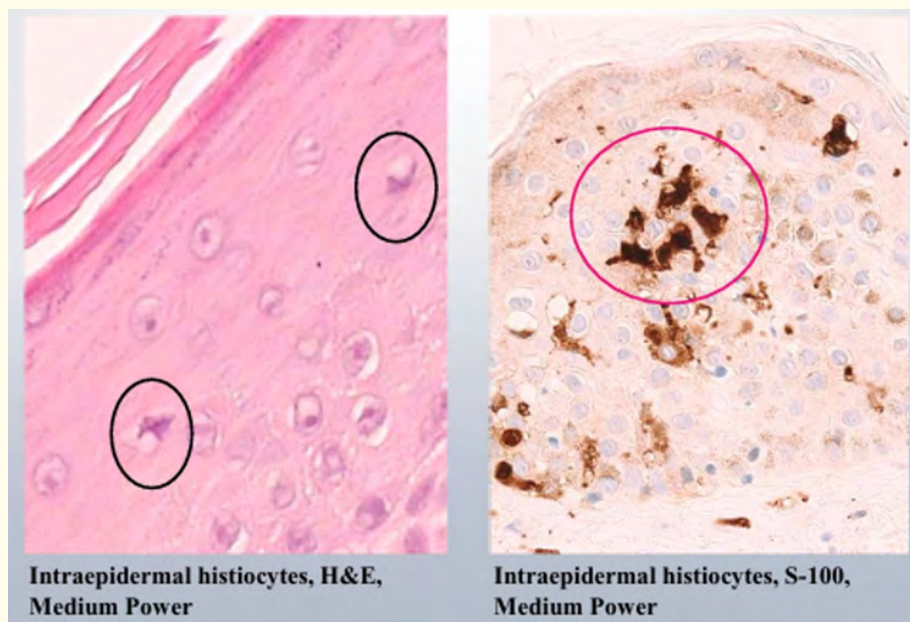


Figure 1: Intraepidermal histiocytes in normal skin (left) and S-100 positive intraepidermal histiocytes in cutaneous drug rash (right).

Drug-induced skin reactions also known as cutaneous adverse drug reactions (CADRs) are terms used to describe adverse effects on the skin mucosae and adnexa resulting from exposure to drugs or its metabolites. They affect up to 10% of hospitalized patients, occurring in 1-3% of multimedicated patients, [7] and have a wide range of inflammatory disease patterns. Conventionally, these are vacuolar interface dermatitis, superficial perivascular lymphocytic infiltrate, eosinophils, dyskeratinocytes, spongiosis and epidermal hyperplasia. More severe reactions can include vesiculobullous lesions, pustular eruptions, sclerodermoid reactions, vasculitis, folliculitis and panniculitis. In general, these histologic features and patterns are non-specific and are also associated with other conditions including viral exanthem, graft versus host disease, connective tissue disease, allergic contact dermatitis, pityriasis rosea, pemphigus, pyoderma gangrenosa, bacterial infection, adult onset Still disease and more severe drug reactions like Steven-Johnson syndrome, drug reaction with eosinophilia and systemic symptoms (DRESS) and toxic epidermal necrolysis (TEN) [1,8]. Individual drugs may elicit multiple reactions; however, no reaction pattern is exclusively linked to any one drug. While intraepidermal histiocytes, or Langerhans's cells, have been associated with neoplasm, including basal cell carcinoma, cutaneous lymphadenoma and dermatofibroma, [4-6] they have not been reported in drug reactions. We quantified intraepidermal histiocytes in clinically common drug reactions to assess their utility in the histopathologic diagnosis of these cases.

In addition to drug reactions including lichenoid drug reaction and fixed drug eruptions, vacuolar interface dermatitis and superficial chronic lymphocytic infiltrate can appear in many conditions including lichen planus and variants, graft-versus-host disease, lupus erythematosus, dermatomyositis, poikiloderma, pityriasis lichenoides, erythema multiforme, and paraneoplastic pemphigus [3]. While cells such as eosinophils are important tell-tale markers of drug-induced reactions, they may also be involved in skin rashes that have no drug association [8]. These skin eruptions can range from mild erythematous skin lesions to significantly more severe reactions like TEN, a.k.a. Lyell's syndrome [9-12]. Interstitial granulomatous drug reaction (IGDR) also known as a granulomatous drug-induced rash, is a form of dermatitis that is characterized by a diffuse interstitial infiltrate of lymphocytes and histiocytes within

the dermis, often accompanied by degradation of collagen and elastic fibres. Additional features may include the presence of eosinophils, atypical lymphocytes and changes consistent with interface dermatitis. Granuloma formation and multinucleated giant cells can be observed in some cases. IGDRs are rare, and intradermal rather than intraepidermal, histiocyte infiltration is the dominant histologic feature [13].

Cytotoxic T lymphocytes are believed to be the primary effector cells in drug rashes, and experimental data supports the involvement of both the Fas-FasL and perforin-granzyme pathways in many cases. Langerhans's cells are defined as intraepidermal immune cells myelogenous in origin, involved in the detection and amplification of the immune response [9]. That our drug rash cases had greater intraepidermal Langerhans's cells than non-drug rash cases may be a manifestation of a unique induction involving Langerhans's cells due to their interaction with drug metabolites and other immune cells.

Conclusion

We found that the prevalence of intraepidermal histiocytes in biopsies of drug rash is approximately two-fold that of normal skin as well as a small sample of non-drug induced rash cases. While clusters of intraepidermal histiocytes are similar in drug and non-drug rashes, the quantity of intraepidermal histiocytes per mm² is greater in drug-induced rashes. S-100 positive intraepidermal histiocytes per mm² of epidermis may be a more specific pathologic marker for drug-induced rash than conventional histology of vacuolar interface dermatitis, perivascular lymphocytic infiltrate, and eosinophils. Future work should compare intraepidermal histiocytes in drug rash to a greater number and wider range of non-drug rash cases.

Bibliography

1. Ernst M., et al. "Histopathologic Features of Maculopapular Drug Eruption". *Dermatopathology* 9.2 (2022): 111-121.
2. Pascucci A. "Granulomatous drug eruption associated with imipramine". *JAAD Case Reports* 4.2 (2018): 152-154.
3. Sehgal V., et al. "Lichenoid tissue reaction/interface dermatitis: Recognition, classification, etiology, and clinicopathological overtones". *Indian Journal of Dermatology, Venereology, and Leprology* 77.4 (2011): 418.

4. Mardones, *et al.* "CD1a+ Langerhans cells in the peritumoral epidermis of basal cell carcinoma". *Actas Dermo-Sifiliograficas* 100.8 (2009): 700-705.
5. Hussein, *et al.* "Immunohistochemical analysis of S100-positive epidermal Langerhans cells in dermatofibroma". *Anais Brasileiros de Dermatologia* 95.5 (2020): 627-630.
6. Fernandez-Flores A, *et al.* "Congenital cutaneous lymphadenoma". *Journal of Cutaneous Pathology* 44.11 (2017): 954-957.
7. Al Aboud, *et al.* "Cutaneous Adverse Drug Reaction (CADR)". (2020).
8. Baroni, A, *et al.* "Lyell's Syndrome". *SKINmed: Dermatology for the Clinician* 4.4 (2005): 221-225.
9. DascaluDI, *et al.* "Langerhans' cell distribution in drug eruption". *Acta dermato-venereologica* 72.3 (1992): 175-177.
10. Del Pozzo-Magaña BR, *et al.* "Drugs and the skin: A concise review of cutaneous adverse drug reactions". *British Journal of Clinical Pharmacology* (2022).
11. Ramdial PK, *et al.* "Drug-induced cutaneous pathology". *Journal of Clinical Pathology* 62.6 (2009): 493-504.
12. Tiwari, P, *et al.* "Toxic epidermal necrolysis: an update". *Asian Pacific Journal of Tropical Disease* 3.2 (2013): 85-92.
13. Williams O, *et al.* "Granuloma". PubMed. (2022).