



Uncommon Tumor of the Foot: Malignant Chondroid Syringoma. Case Report

Bao Carlos*, Rega Leonel and Perez Gabriela

Department of Ortophedics and Traumatology, Hospital José María Penna, Argentina

***Corresponding Author:** Bao Carlos, Department of Ortophedics and Traumatology, Hospital José María Penna, Argentina.

Received: September 28, 2023

Published: February 08, 2024

© All rights are reserved by **Bao Carlos., et al.**

Abstract

Introduction: Chondroid Syringoma (CS) is a rare benign tumor with mixed epithelial and mesenchymal components, making its diagnosis challenging due to its silent clinical presentation and resemblance to other skin lesions.

Case Report: We present a case of malignant chondroid syringoma in a 55-year-old male with a painless, slow-growing tumor on the dorsal aspect of the left forefoot. The tumor was successfully excised with safety margins, and the patient had an uneventful postoperative course. Histological examination confirmed the diagnosis of malignant chondroid syringoma based on the presence of infiltrative growth, pleomorphism, increased mitoses, and necrosis in the epithelial component. The tumor's histological features showed a biphasic appearance with both sweat epithelial and mucoid, fibrous, or chondroid interstitial components.

Discussion: Chondroid Syringoma's histogenetic origin remains unclear, and it is commonly misdiagnosed as other skin lesions due to its rarity and indolent nature. Malignant variants are infrequent but may exhibit local recurrence and metastasis. Proper diagnosis relies on histopathological examination, and wide excision is recommended to reduce the risk of recurrence. Radiotherapy and chemotherapy have shown limited efficacy. Regular patient follow-up is crucial for early detection of any recurrence or metastasis.

Conclusion: Awareness of the characteristic features of this tumor can aid in its prompt identification and management.

Keywords: Malignant; Chondroid Syringoma; Foot; Uncommon Tumor

Introduction

Chondroid Syringoma (CS) is a benign tumor, also called mixed skin tumor due to the presence of epithelial and mesenchymal components. It is a rare adnexal cutaneous tumor, and its histogenetic origin remains obscure [1-3].

Diagnosis is often difficult because the prevalence is rare and they have silent clinical presentations and are often overlooked or are confused with other types of skin lesions, such as sebaceous cysts, dermatofibroma, basal cell carcinomas, histiocytoma, and seborrheic keratosis [4].

Case Report

We present the case of a male patient, 55 years old, with a tumor on the dorsal aspect of the left forefoot in the metatarsophalangeal region of the second space with more than 10 years of evolution (Figure 1 A and B). The patient described his condition as painless and a very slow-growing tumor, which doesn't let him care out his daily tasks and activities. Due to the time of its evolution, he wore high-toe shoes that did not bother him while he was doing his daily tasks. There was no history of local trauma, other tumors, or infection in this area or in general. The patient consulted us because his wife was worried about his condition.

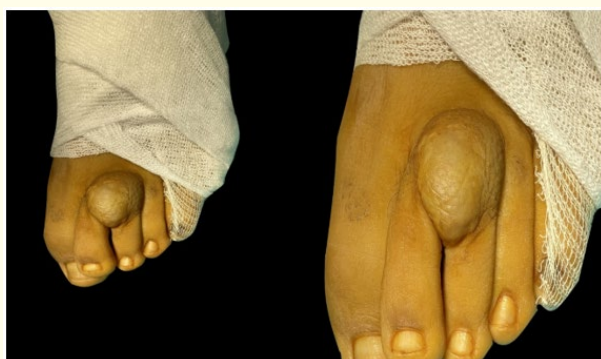

Figure 1: Clinical Image of tumor on the dorsal aspect of the left forefoot in the metatarsophalangeal region.

X-rays showed no evidence of blastic or osteolytic lesions in the forefoot. Magnetic resonance imaging showed an isointense subcutaneous mass that did not affect the joint or the bone tissue (figure 2 A, B, C and Figure 3 A, B, C).

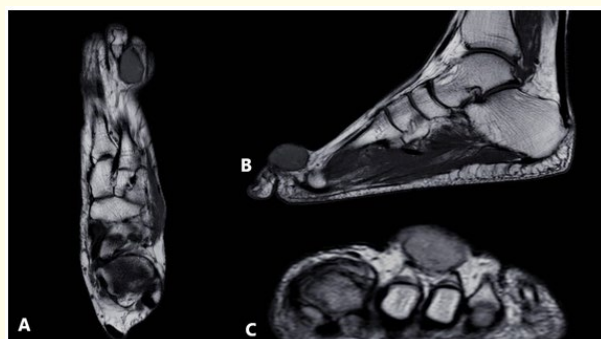

Figure 2: RNM image in T1, a well-defined mass is usually seen and isointense compared to the surrounding tissue. The isointense appearance on T1 suggests a proton density like that of the surrounding muscle tissues.

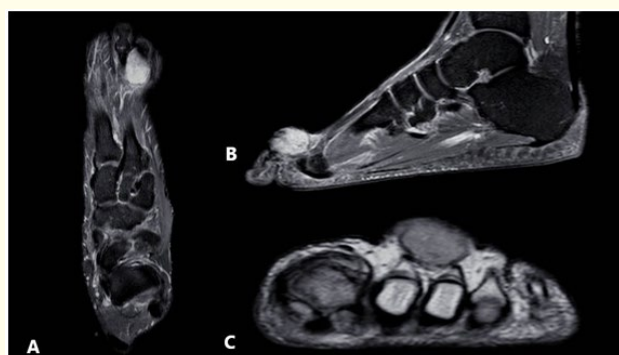

Figure 3: This hyperintense appearance on T2 suggests the presence of a component with a high concentration of water, such as the myxoid stroma or the cartilaginous component present in the tumor.

We decided to take the patient to the operation room for tumor excision. The patient was placed in a supine position under regional anesthesia and a straight incision was made over the lesion in the dorsal region, with wide skin margins. A well-circumscribed mass with no signs of invasion of adjacent structures was identified, measuring 2.0 × 3.0 × 1.2 cm. Complete resection with safety margins was performed. The specimen was sent to anatomical pathology in formalin. Wound closure was performed with vycril 3.0 and nylon 4.0 and a sterile dressing was applied (Figure 4 A, B, C and D).

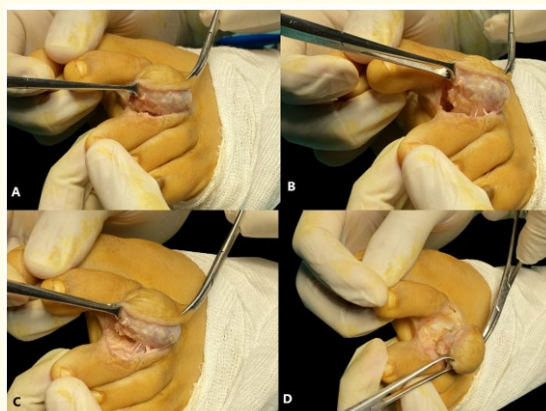


Figure 4: Intra operative image. A well-circumscribed mass with no signs of invasion of adjacent structures.

The patient started weight bearing with a Walker boot immediately after the operation. The stitches were removed after 3 weeks. The patient continued to live an everyday, pain-free life with a postoperative follow-up of 24 months. He returned to all activities of daily life without restrictions (Figure 5 A, B, C).

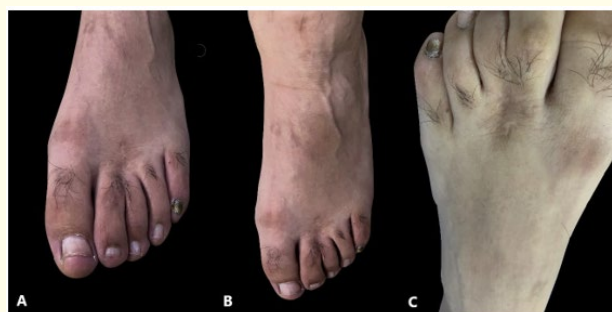

Figure 5: Image clinical after Follow up 24 months.

In the anatomical pathology report, a non-encapsulated intradermal proliferation invaded the hypodermis, forming separate lobes of myxoid and chondroid stroma. It presents an

asymmetric architecture and infiltrative edge. The epithelium is composed of nests of polygonal cells with pink cytoplasm and basophilic nuclei with atypical characteristics such as a prominent nucleolus. Focus of hemorrhage and necrosis are identified.

The immunohistochemistry performed showed positivity for keratin AE1-AE3, s-100, SOX-10, KERATIN 5. Focal positivity for p-63, being Negative for MELAN A.

The diagnosis of malignant chondroid syringoma (malignant mixed tumor) is concluded (Figure 6 A, B, C, D, E and F).

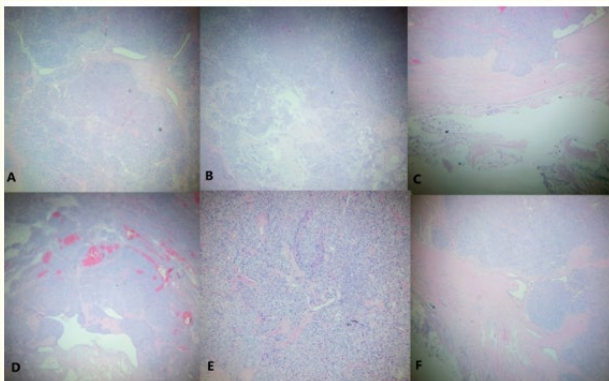


Figure 6: Non-encapsulated intradermal proliferation invaded the hypodermis, forming separate lobes of myxoid and chondroid stroma. It presents an asymmetric architecture and infiltrative edge. The immunohistochemistry performed showed positivity for keratin AE1-AE3, s-100, SOX-10, KERATIN 5.

From the histological point of view, it presents a biphasic appearance (mixed tumor) with a sweat epithelial component; apocrine (in the benign part) or eccrine, and a mucoid, fibrous, or chondroid interstitial component. Currently, your diagnosis requires identifying the sector of benignity. Malignancy criteria focus on the epithelial part and included: infiltrative growth pattern, nuclear and/or cytoplasmic pleomorphism, increased number of mitoses, hemorrhage focus, and necrosis [5].

Discussion

In 1859 Billroth described this lesion as a tumor like salivary gland tumors because they contained mucoid and cartilaginous material. Later Virchow, based on his components, referred to it as

mixed skin tumors. In 1961, Hirsch and Helwig were the first to use the term SC to describe the presence of sweat gland elements in the cartilaginous stroma. The tumor elements found to be cartilage-like led Hirsch and Helwig to suggest the name “chondroid syringoma” [1,2,6-8].

Iglesias, *et al.* and Yavuzer, *et al.* estimate its incidence to be between 0.01 and 0.1%. It affects middle-aged men (7:2) and is characterized by asymptomatic, slow-growing dermal or subcutaneous nodules. It is usually located on the head and neck, (80% of cases) on the nose, cheek, upper lip, scalp, and forehead, and less affects the axillary region, abdomen, penis, vulva, and scrotum and very rarely the extremities [1,2,6-10].

There have been reports of malignant variants, mostly in females (3:2) and located on the extremities. Occasionally malignant lesions have been described with recurrences, local invasion, and metastasis to lymph nodes (48% of patients), lungs, bone, and brain (45% of patients). Two largest case series reported in the literature, the extremities are involved 15% and 10% of the time. A review of malignant chondroid syringoma noted that the extremities were involved in 82% of cases [1,2,4,6-8,12].

The neoplasm is in the deep dermis and/or subcutaneous, forming a well-demarcated, symmetrical tumor mass bounded by fibrous septa. Malignant chondroid syringomas typically arise de novo and not from a pre-existing benign tumor. It tends to follow an unpredictable clinical course. Only thirty-six cases of this malignant tumor have been reported from 1961 to 2004. The average age of the patients was 48.3 years (13-84 years). Eight patients died. Fifty percent had local recurrences [1,2,4,13,14].

Headington classified SC into two histological varieties, apocrine and eccrine, depending on which cell type predominates. Apocrine is the most common. The epithelial component has apocrine features when it presents tubular and/or ductal structures with cuboidal cells internally and myoepithelial cells externally [1,2,6-8].

A tumor is considered to have eccrine features when the epithelial stroma is from a tiny gland, with a single layer of cells, or small islands of cuboidal cells scattered in a myxoid or chondroid stroma. However, the differentiation between eccrine and apocrine

is not always straightforward, neither by histopathology nor by immunohistochemistry. Even by electron microscopy, this differentiation may not be clear. The mesenchymal component is made of myxoid or densely collagenized areas. Chondroid areas are seen in 59% of cases. Calcification, trabeculae, and bone marrow may also be present [1,7].

In 1978, Lomax-Smith and Azopardi provided a detailed description of the characteristic cells of mixed salivary gland tumors. In the same article, they mention the presence of these cells in benign and malignant chondroid syringomas. In 1984, Mambo documented the microscopic features of hyaline cells in a case of benign chondroid syringoma. Subsequently, Moreno, *et al.* reported another case of chondroid syringoma in which hyaline cells constituted more than half of the neoplasm. In 1989, Argenyi, *et al.*, in a review of twenty cases of chondroid syringoma, they had found hyaline cells in eight tumors [2,6].

Khoo, *et al.* reported the case of a 51-year-old patient with a nodule on the lower surface of the right middle toe 6 years of evolution. The characteristic of the case is that he described a painful mass with superficial ulceration. The toe was amputated at the metatarsophalangeal joint and the patient had no recurrence [15].

Toback and Toback presented, the third documented case of chondroid syringoma occurring in a toe. They recommended wide surgical excision because there is a tendency for local recurrence which is often attributed to incomplete excision [17].

Potter, *et al.* presented a case of chondroid syringoma on a toe. The diagnosis was confirmed microscopically, and they reported that it should have been considered in the differential diagnosis of painless and slow-growing tumors in the feet [18,19].

Takahashi, *et al.* reported the case of a 22-year-old Japanese woman with an ulcerated nodule on the hallux in the left foot in 1996. The nodule was excised with a narrow margin and recurred in 2000 [13].

Ryu, *et al.* reported the case of a 46-year-old man with a nodular mass on the right heel. The mass had grown slowly over the past 10 years. It was painless and mobile, but the patient felt discomfort when he put on his shoes [12].

Gutiérrez, *et al.* reported the case of a 38-year-old female patient who presented a nodular, non-painful lesion on the fourth toe of the right foot, after 10 years of evolution. According to the patient's reference, it would have been a recurrence case, but the authors did not confirm it because they did not know the pathological anatomy of the first surgery [6].

Beals presented the case of a 42-year-old Asian woman with a mid-forefoot lesion, like our patient, who reported footwear-related symptoms. She had no history. The mass was not painful [9].

Madi, *et al.* reported a 47-year-old woman with a solitary painless slow-growing mass on the plantar aspect of the left foot. She had had this tumor for over 20 years. No medical or surgical history was reported. The patient declined surgical intervention [7].

Tunia, *et al.* reported a 45-year-old female patient with an asymptomatic lesion with several months of evolution in the right foot. An excisional biopsy was performed [8].

Sundling, *et al.* reported a 43-year-old patient with a mass on the plantar forefoot with 6 months of evolution. She described pain that was exacerbated by wearing shoes. There was no history of local trauma, other tumors, or infection in this area. An MRI image describes a mass that may be a fibrous-type tumor [4].

Lu, *et al.* described the case of a 72-year-old patient with a mass in the third toe of the right foot, which had slowly increased in the last 2 years. The patient reported no history of trauma. Due to the slow growth of the mass, they diagnosed the lesion as a benign tumor and recommended a biopsy [17].

Wernham presented the case of a 53-year-old patient with a 4-year history of a lesion on the back of the right heel. Physical examination revealed a 4 cm ulcerated exophytic nodule, not attached to the tendon or underlying bone. Peripheral examination showed no palpable lymphadenopathy or other lesions. The mass was biopsied and excised [20].

The differential diagnosis is myoepithelioma, chondroid choristoma or fibromyxoid tumor, sebaceous cyst, dermoid implantation, neurofibroma, dermatofibroma, basal cell carcinoma, squamous cell carcinoma, pilomatrixoma, histiocytoma [8].

Conclusion

We report a very infrequent neoplasm of the extremities, which due to his characteristic of slow evolution and painlessly does not generate suspicion in his diagnosis.

We recommend anamnesis and study of the lesion and wide excision of the lesion because it has been reported cases of recurrence and metastasis.

None of the cases published in the literature have reported the efficacy of radiotherapy or chemotherapy in shrinking the tumor mass.

The control of the patient is mandatory for early detection, in case of local recurrence or metastasis.

Confirmation of the diagnosis is anatomopathological, although we must be alert in case of the characteristics that have been reported.

Highlights

- Detailed clinical history, physical examination, and imaging findings.
- Histopathological analysis, including immunohistochemical staining, supporting the diagnosis of malignant chondroid syringoma.
- Differential diagnosis and the rationale behind the definitive diagnosis.
- A comprehensive review of the literature on malignant chondroid syringomas, highlighting their clinical and histopathological characteristics.
- Discussion on the therapeutic options available and the rationale for the selected treatment approach.
- Long-term follow-up results and the patient's outcome.

Bibliography

1. Franco Joanna Pimenta de Araujo., *et al.* "Caso Para Diagnóstico". *Anais Brasileiros de Dermatologia* 88.6 (2013): 997-999.
2. BANERJEE S S., *et al.* "Chondroid Syringoma with Hyaline Cell Change". *Histopathology* 22.3 (1993): 235-246.
3. Barreto Carol A., *et al.* "Intraosseous Chondroid Syringoma of the Hallux". *Journal of the American Academy of Dermatology* 30.2 (1994): 374-378.
4. Sundling Rebecca A., *et al.* "Chondroid Syringoma: A Case Report in the Foot and Ankle". *Foot and Ankle Specialist* 10.2 (2017): 167-169.
5. Wan Huiying., *et al.* "Clinical and Pathological Study on Mixed Tumors of the Skin". *Medicine* 97.36 (2018).
6. Gutiérrez-díaz-ceballos Ma Esther., *et al.* "Siringoma Condroides Con Cambios de Células Hialinas". *Informe de Un Caso* 4 (2009): 211-214.
7. Madi Khaled., *et al.* "Chondroid Syringoma of the Foot: A Rare Diagnosis". *Journal of Foot and Ankle Surgery* 55.2 (2016): 373-378.
8. Tunia María Sánchez Ramos., *et al.* "Siringoma Condroides. Presentación de Un Caso". *Revista Habanera de Ciencias Médicas* 15.5 (2016): 752-758.
9. Beals Timothy C., *et al.* "Chondroid Syringoma: Case Report of a Highly Unusual Foot Tumor". *Foot and Ankle International* 31.4 (2010): 333-335.
10. Iglesias F Dominguez., *et al.* "Chondroid Syringoma: A Histological and Immunohistochemical Study of 15 Cases". *Histopathology* 17.4 (1990): 311-317.
11. Yavuzer Reha., *et al.* "Chondroid Syringoma: A Diagnosis More Frequent than Expected". *Dermatologic Surgery* 29.2 (2003): 179-181.
12. Ryu Jung Kyu., *et al.* "Sonographic and Magnetic Resonance Imaging Findings of a Chondroid Syringoma of the Heel Case Report and Literature Review". *Journal of Ultrasound in Medicine* 26 (2007): 1435-1439.
13. Takahashi Hayato., *et al.* "Malignant Chondroid Syringoma with Bone Invasion: A Case Report and Review of the Literature". *American Journal of Dermatopathology* 26.5 (2004): 403-406.
14. Watson JAS., *et al.* "Malignant Chondroid Syringoma—a Rare Cause of Secondary Bone Tumour". *Clinical and Experimental Dermatology* 16.4 (1991): 306-307.
15. KHOO TK and KB TZE. "A Sweat Gland Tumour of the Mixed-Salivary Type of the Right Middle Toe". *The Medical Journal of Malaysia* 19 (1964): 128-133.

16. Lu Hui., *et al.* "A Rare Large Cutaneous Chondroid Syringoma Involving a Toe". *Medicine (United States)* 97.5 (2018): 1-5.
17. Toback TG and CJ Toback. "Chondroid Syringoma. A Review of the Literature and Case Report". *Journal of the American Podiatric Medical Association* 79.11 (1989): 563-565.
18. Potter G K., *et al.* "Chondroid Syringoma in a Toe". *Cutis* 30.3 (1982): 339-341.
19. Wagoner WL., *et al.* "Chondroid Syringoma. A Rare Occurrence in the Hallux". *Journal of the American Podiatric Medical Association* 83.7 (1993): 424-425.
20. Wernham Aaron., *et al.* "Chondroid Syringoma of the Heel Masquerading as a Malignant Tumour: A Potential Pitfall in Diagnosis". *Australasian Journal of Dermatology* 61.1 (2020): 60-61.