



## Diabetic Eye Disease

### Vertika Kulshrestha\*

Senior Consultant (Ophthal), Vindhya Hospital, NTPC Vindhyachal, Madhya Pradesh, India

\*Corresponding Author: Vertika Kulshrestha, Senior Consultant (Ophthal), Vindhya Hospital, NTPC Vindhyachal, Madhya Pradesh, India.

**Received:** September 27, 2023

**Published:** February 06, 2024

© All rights are reserved by **Vertika Kulshrestha**.

### Abstract

Diabetes is a well-known common chronic disease that affects the entire body. It deteriorates the entire body slowly thus reducing the ability to perform. A blood test determines the type of diabetes a person has. Mainly there are four types of diabetes Type 1, Type 2, Gestational diabetes and Prediabetes. According to World Health Organization, 1.5 million deaths had a direct cause of death as diabetes in 2019. Moreover, 8.5% of adults of 18 years and above had diabetes in 2014 [1]. There are two main reasons for diabetes to occur. Firstly, when the pancreas does not produce enough insulin. Secondly, it happens when the body does not accept sugar (glucose) into the cells which are used as fuel for the body to perform. As a result, extra sugar starts building in the bloodstream. Excessive sugar in the blood for a long time can cause damage to many parts of the body. It can have several serious consequences which can damage the body's organs and tissues. It can cause harm to the heart, kidneys, blood vessels. It damages the smaller nerves of the eye as well [1]. Whether the diabetes is poorly controlled or well-controlled it can affect the eye. 90% of the vision loss from diabetes can be prevented with early detection as per the Centers For Disease Control And Prevention. They also further reveal that about 60% of diabetes patients do not even go to the medical centers for annual or routine eye check-ups.

**Keywords:** Diabetes; Glucose; World Health Organization

### Introduction - Diabetic Eye

Diabetes also affects the eyes over time and can lead to vision loss or in extreme cases blindness. It hits your body when blood glucose also known as blood sugar is high. Blood glucose has an impact over a duration of time [1,5].

#### Longer time

When the blood glucose stays higher over time it causes damage to the minute tiny blood vessels located at the back of the eye. This starts when a person is in the prediabetic stage as sugar levels are slightly high than the normal range of 144-199mg/dl but, not enough to be diagnosed with diabetes. Blood vessels in the eye which are damaged and have leaking fluid cause swelling in such cases. Few new blood vessels also began to grow which can

also bleed into the middle part of the eye which leads to scars or high pressure inside the eye.

#### Shorter time

Fluid levels in the eye are fluctuated to a higher range when blood glucose levels are high. This leads to swelling of tissues of the eyes which blurs the vision. This blurred vision is temporary and goes away when the blood glucose level is close to the normal range. It is not likely to develop vision loss in this type.

People with diabetes can be affected by a group of eye diseases such as diabetic retinopathy, diabetic macular edema, glaucoma, and cataracts. These all diseases threat the eyesight. They can lead to vision loss or may get worse over time but, early detection and

appropriate treatment can protect the eyesight in the long run. Sometimes there are no warning signs of diabetic eye disease or any vision loss when it starts damaging the eye from inside. A full dilated eye exam is conducted to find the solution to the underlying problem early. Managing diabetes, getting periodical eye screenings can help prevent vision problems and may stop them from getting worse.

### Diabetic eye disease

There are namely four types of diabetic eye diseases that are a threat to the vision of the eye.

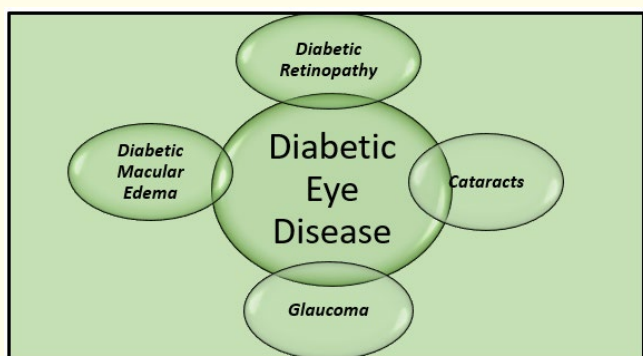


Figure 1: Types of Diabetic Eye Disease.

The radial diagram above shows the four types of diabetic eye disease.

### Diabetic retinopathy

It mainly occurs when the blood vessels in the retinal leak fluid, swell or close completely. Sometimes it just not only occurs at the back but also in the front. Individuals with poor control of blood sugar or with longer diabetes have a high risk of having Diabetic Retinopathy [7].



Figure 2: Photo courtesy of the National Eye Institute.

The photograph above depicts the vision as viewed by a person with Diabetic Retinopathy.

### Diabetic macular edema

It develops when fluids build upon the retina which causes blurry distorted vision and swelling. It can lead to permanent vision loss if goes untreated and undiagnosed [6].



Figure 3: Photo courtesy by www.eyehandglasses.net.

The picture above exposes the blurry and distorted vision of the person suffering from Diabetic Macular Edema.

### Glaucoma

It is a group of eye diseases that damages the optic nerve of the eye. The optic nerve connects the eye to the brain. A person suffering from diabetes has twice the chance of having Glaucoma which can lead to irreversible loss of vision [6].

The above picture displays the vision of a person with Glaucoma where one loses side vision slowly.




Figure 4: Photo courtesy of the National Eye Institute.

## Cataracts

They are caused due to excess sugar from diabetes. Normally, the lenses within our eyes help to provide sharp and clear vision but due to age, they become cloudy. People with diabetes are likely to develop cloudy lenses known as cataracts. Permanent clouding can be prevented by maintaining good sugar levels and in extreme cases, cataract surgery or the use of a lens is prescribed [6,8].



**Figure 5:** Photo courtesy of the National Eye Institute.

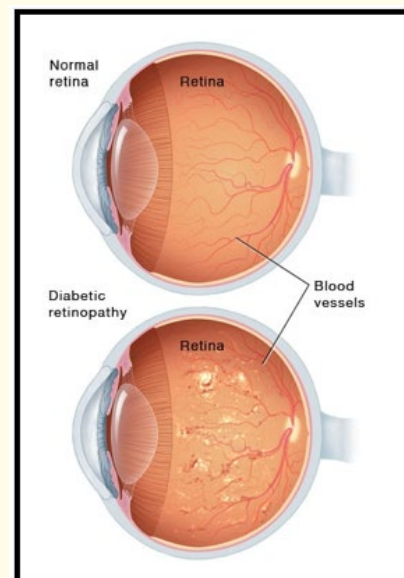
The photograph above shows the vision of a person with cloudy vision and faded colors which are symptoms of cataracts-diabetic eye disease. Other problems such as double vision, blurred vision also occur at a prediabetic stage which can be corrected through prescribed medicine, glasses, or lens. Glaucoma and cataract have twice the rate of occurrence with the people who have diabetes whereas Diabetic Retinopathy occurs almost to one in three people above forty years of age suffering from diabetes. This particular document will completely emphasize Diabetic Retinopathy highlighting its symptoms, types, risk factors, diagnosis, treatment, complications and prevention measures concluding with survival along with it.

## Retina

It is the tissue in the eye which sends signals to the brain to capture the vision, same as a camera. It converts the light rays into electrical impulses which are utilized to communicate with the brain. These impulses enable one's vision.

## Diabetic retinopathy - An eye disease

Diabetic Retinopathy is a by-product of diabetes that affects the eyes. Any individual with type 1 or type 2 can develop diabetic retinopathy. The longer a person is suffering from diabetes with uncontrolled blood glucose sugar it is likely to occur and develop complications to the eye. It damages the blood vessels of the most sensitive tissue of the eye called as retina which is highly sensitive towards light. Initially, it doesn't show its presence as it can show absolutely no symptoms or only mild problems related to it but it can lead to complete vision loss if it is undiagnosed and untreated [5].



**Figure 6:** Diabetic Retinopathy.

## Symptoms

The early stages of diabetic retinopathy might not show any symptoms in most people. Sometimes vision changes are noticed only when the condition gets intensified or worsens. In some cases, the symptoms come and go and get cured on their own. Following are the symptoms of diabetic retinopathy [1,4,5].

- Vision worsens overtime
- Distorted vision
- Blurred vision

- Seeing colors in a faded pattern
- Night Blindness or poor vision at night
- Eye floaters which are small dark spots in your vision
- Trouble seeing faraway objects or reading
- Having the patchy vision
- Redness in the eye
- Eye pain

Having symptoms of diabetic retinopathy doesn't mean that one might be suffering from the disease but it is necessary to get checked by an ophthalmologist. Don't wait to get things at their worst.

### Types

The retina needs a constant supply of blood to function properly which is received by the tiny network of the blood vessels. Over time too much blood glucose level in the bloodstream leads to blockage into these blood vessels. As a result of which new blood vessels began to sprout but those are underdeveloped and can cause leakage of blood.

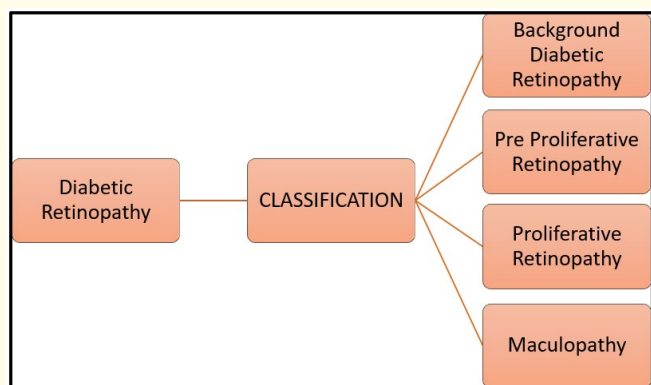


Figure 7: Types of Diabetic Retinopathy.

The above horizontal hierarchical progression shows the classification of Diabetic Retinopathy into Background Diabetic Retinopathy which is further classified into three namely Pre Proliferative Retinopathy, Proliferative Retinopathy, and Maculopathy or Macular Edema. It is not necessary for the individual suffering from all these types to have vision impairment

but if it's untreated even after diagnosis it may worsen the eyesight. In rare cases, if both the eyes are affected there may be vision loss. With early detection and proper treatment along with lifestyle changes, one can control the harm caused to the eyes by Diabetic Retinopathy.

### Background retinopathy

Background Retinopathy is shortly abbreviated as BDR. The name itself suggests that it is never in the front but it has its presence at the back marking the start of the damage to the blood vessels of the eyes. Tiny bulges known as microaneurysms appear in the blood vessels at the back of the eye that is retina starts leaking a small amount of blood in Background diabetic retinopathy. This condition is very common for people who are long sufferers of Diabetes. Almost one in five people suffer from Background Diabetic Retinopathy. At this stage, the sight might not be affected or one doesn't need the treatment but there is a chance of the situation getting worst if the developing vision problems are left untreated.

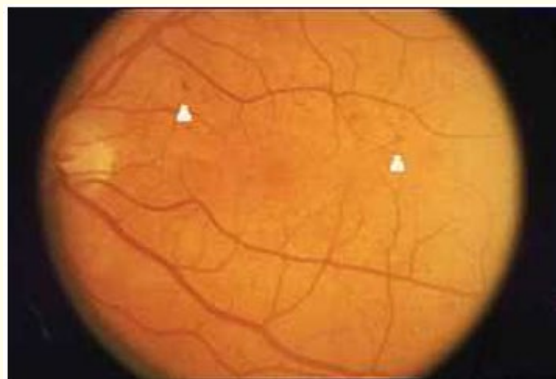


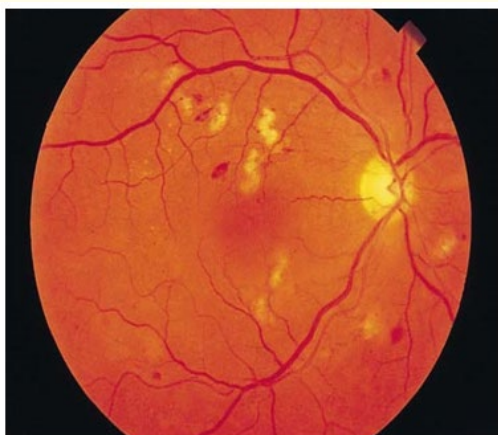Figure 8: Markings above the white triangles are the hemorrhages with tiny microaneurysm.

Background Diabetic Retinopathy consist of Hemorrhages, Microaneurisms, and Hard Exudates. Hemorrhages which is the bleeding occurring from the damaged blood vessel into the retinal layer of the eyes. This does not affect the vision unless it has occurred near the macula. Microaneurisms are the scattered red spots in the retina where the weakened blood vessels have ballooned out. They are normally visible in the examination of the

eye through an ophthalmoscope. Hard Exudates are caused due to the lipids and protein leaking into the retina through the damaged blood vessels. They are normally white or yellow with sometimes ring-like structures. This doesn't affect the vision unless they have occurred near the macula. If Background diabetic Retinopathy is not diagnosed and blood glucose levels are not controlled then later stages are likely to occur causing damage to the eye, These are namely pre proliferative retinopathy, proliferative retinopathy, and maculopathy [7].

**Pre proliferative retinopathy**

This is also known as Nonproliferative Diabetic Retinopathy (NPDR)- which is the early stage of the disease. High sugar levels lead to damage of the blood vessels of the retina weakening and creating vessels lumens as a result of outpouching known as microaneurysms. They eventually rupture to hemorrhages in the retina. They are dot-like in structure hence called dot-and-blot hemorrhages. Thus the weakened blood vessels likely cause leakage of the fluids to flow into the retina. As this condition progresses the vessels which are affected get obstructed. This obstruction causes the nerve fiber layer infraction resulting in fluffy and white patches famously known as Cotton Wool Spots (CWS) [11].

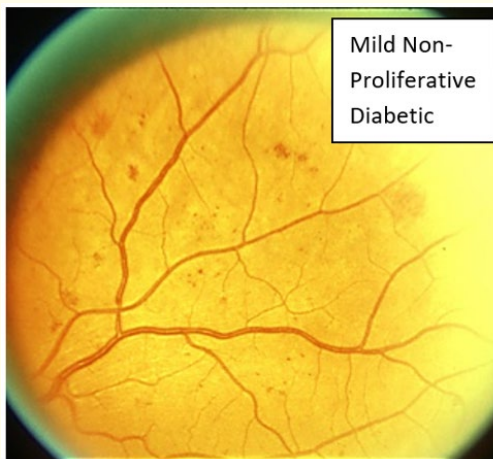


**Figure 9:** Cotton wool spots.

Pre proliferative/Non-Proliferative Diabetic Retinopathy is further divided into three categories based on the presence or absence of abnormal retinal bleeding of the venous wall or abnormal vascular findings are as follows [9-11].

**Mild**

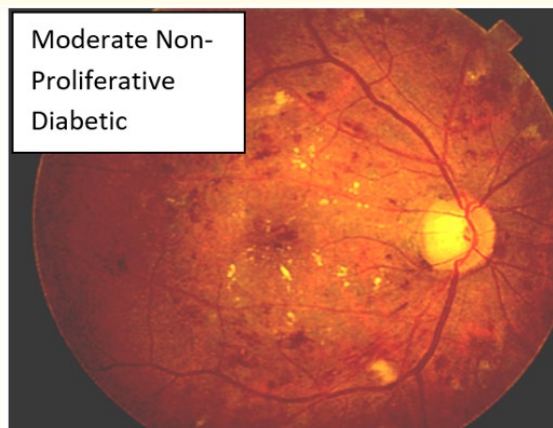
Non-Proliferative Diabetic Retinopathy- This is the early stage when on eye examination at least one microaneurysm is present.



**Figure 10**

**Moderate**

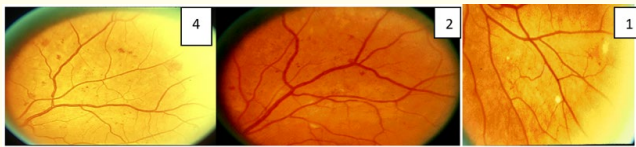Non-Proliferative Diabetic Retinopathy-In this type the number of microaneurysms are multiplied with dot-and-blot hemorrhages, cotton wool patches sometimes hard exudates are also present.



**Figure 11**

## Severe

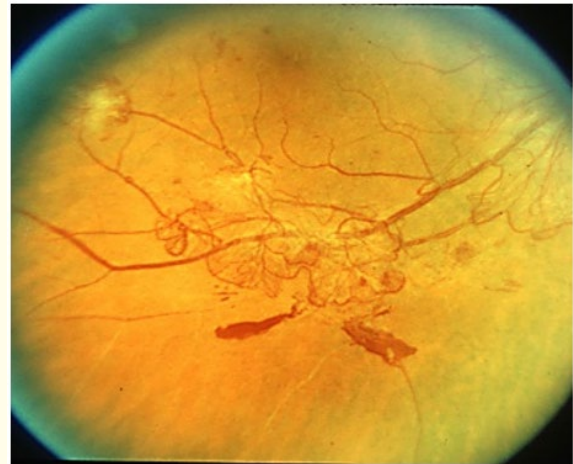
Non-Proliferative Diabetic Retinopathy-At this stage blood vessels get more blocked which means less blood supply to the retina as a result scar tissue formation begins. These situations signal the retina to create new blood vessels. If these blood vessels are completely closed then it's termed macular ischemia which leads to dark spots called floaters. At this stage, there is a high chance of losing the vision. According to international classification following are the signs of the condition firstly, twenty and above hemorrhages in each of the four quadrants. Secondly, definite venous beading which is dilatation and constriction of venules in the retina present in two or more quadrants. Lastly, IRMA (Intraretinal Microvascular Abnormalities) are abnormalities to the blood vessels supplying to the retina present in one or more quadrants. Moreover, it also has a 4-2-1 rule according to US standards which means 4 microaneurysms in every four quadrants, 2 venous beading in two quadrants, and 1 IRMA in one quadrant.



**Figure 12**

## Proliferative diabetic retinopathy

Retina has a high requirement of blood so, with the ischemia, the cells respond by releasing some angiogenic signals. These angiogenic factors stimulate the sprouting of new blood vessels and pass the damaged vessels of the retina which is known as neovascularization. In this retinopathy, proliferation extends beyond the internal limiting membrane but can be leaky, fragile, and misdirected. They can extend into the vitreous or retina. As the shrinkage of the vitreous occurs the fragile vessels are pulled causing it to tear which results in sudden vision loss or vitreous hemorrhage. These vessels can develop scars that can anchor between the vitreous and retina which can even cause traction in the retina leading to detachment. Thus the effect of Proliferative Diabetic Retinopathy can be devastating leading to permanent vision loss.



**Figure 13: Proliferative Retinopathy.**

They are further classified with high risk characterized out of the three firstly, disc area ranging from one third to one-fourth area is lesser than NVD. Secondly, NVD is associated with vitreous or pre-retinal hemorrhage. Thirdly, NVE along with vitreous or pre-retinal hemorrhage. Neovascularization at the disc is the most serious complication which leads to vitreous hemorrhage and tractional retinal detachment. Neovascularization elsewhere means occurring outside [5,9,10].

## Maculopathy

Macula is the central part of the retina which is utilized for straight vision. Patients whose blood sugar levels are not in control or at an optimal level can suffer from edema which is swelling of the macula. In some cases, it can be blocked or leaked. This condition leads to distorted or decreased vision in which the object looks crooked or wavy. This is non-curable but can be prevented with proper treatment for the condition to get worsen. Depending upon the severity level it has three classes according to the international standards. Firstly, mild in which the retinal thickening or the hard exudates are in the posterior part but distant from the center of the macula. Secondly, moderate in which retinal thickening and hard exudates are approaching the macula but not involved in the center. Lastly severe, in which the retinal thickening and hard exudates involve in the center. There are two, major intraretinal components of diabetic maculopathy namely retinal ischemia and edema.

Depending on which they are further classified into five types such as focal maculopathy, diffuse maculopathy, ischemia maculopathy, mixed maculopathy, and clinical significant maculopathy [5,9,10].

Focal leakage from the retinal microaneurysms and dilated capillary segments lead to focal maculopathy.

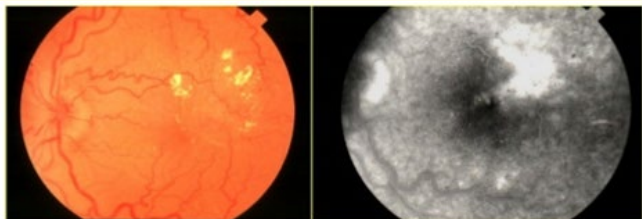


Figure 14: Focal Maculopathy.

Leakage from diffusely dilated retinal capillaries throughout the posterior pole causes diffuse edema. They are caused due to cardiac, renal failure, and hypertension.

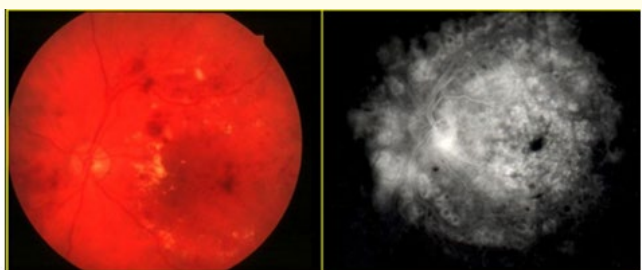


Figure 15: Diffuse maculopathy.

Ischemia maculopathy is one of the vision-threatening diseases with no established line of treatment.

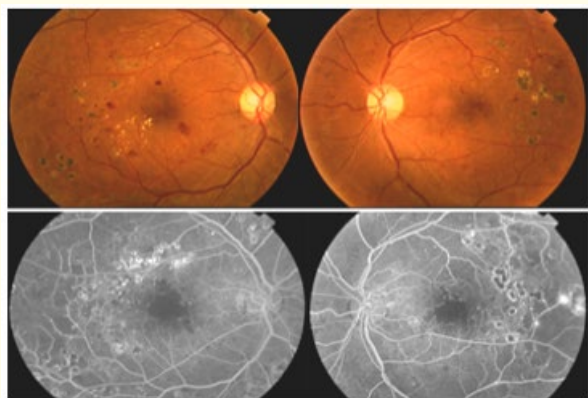


Figure 16: Ischemia Maculopathy.

Ischemia maculopathy is caused by induced microvascular blockage and enlargement with capillary loss and without edema, presence of foveal avascular zone abnormalities, capillary nonperfusion areas are in the macula and microaneurysms at the border. Mixed maculopathy is the combination of diffuse and ischemia maculopathy. In its early stages, it has lots of microaneurysms and retinal capillary nonperfusion. Later it has a diffuse leakage pattern [9,10]. Clinical significant macular edema is determined when one or more of the following occur - thickening of the retina at or within 500µm of the center of macula; hard exudates at or within 500µm of the center of macula if it is associated with adjacent retinal thickening; zone or zones of the retinal thickening one disc area in size at least part of which is within one disc diameter of the center of the macula.

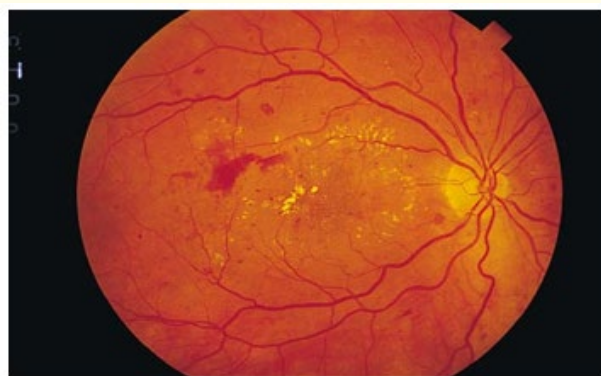

Figure 17: Clinical significant macular edema.

**Risk Factor**

Any individual who is suffering from pre-diabetes, Type 1, Type 2, and Gestational Diabetes can suffer from diabetic eye disease. The duration of diabetes retinopathy a person has is also at stake. The risk increases with a person whose high blood pressure is not treated and whose high blood sugar levels are uncontrolled. Smoking, high cholesterol levels also increase the risk of diabetic eye disease. A person belonging from an ethnic group of origins such as India, America, Hispanics, Latinos, and older individuals are at risk of vision loss from diabetes. Gestational Diabetes detected during pregnancy can also develop eye problems quickly. As the baby grows in the womb many changes are happening in the body, as a result, there is pressure in the blood vessel in the eye too. Hypertension also can put an individual at risk of diabetic eye disease [9,10].

## Diagnosis

An ophthalmologist diagnoses diabetic retinopathy with simple examination as follows [1,5,6],

- Visual Acuity- In this test acuity in the vision is checked means how an individual can see.
- The function of the eye muscle- In this examination movement of the eyes is checked.
- Intraocular pressure is the fluid pressure inside the eye that is checked to ensure there are no signs of glaucoma.
- Pupil response- In this, the pupil reaction to the light is assessed.
- Peripheral vision- In this, the periphery of the eyes is checked.
- Dilation of the eye- In this a thorough examination is conducted by putting the drop in the eye to dilate the pupil so that a wider area at the backside of the eye can be studied through a magnifying lens. In this test, one can examine the abnormalities in a blood vessel, any bleeding in the center of the eye, swelling of the retina, and proliferating blood vessels if any. After this test is conducted one may have blurry vision for a few hours.

Medics can suggest additional tests depending upon age, health history. It is mandatory to visit once a year or can have a different plan to visit the ophthalmologist yearly to examine the eye depending upon the level of diabetes and diagnosed retinopathy. People with Type 1 diabetes should start diagnosis within five years of diabetes, Type 2 personnel should do immediately after the diagnosis is done, and during pregnancy, whether the person is suffering from Type 1 or type 2 doctor may suggest test during the first three months and later until baby turns one year old.

## Treatment

When creating the treatment plan for the individual the doctor may consider the age, medical history, visual acuity, HbA1c, and extent of damage of the retina. Initially, they would wait to give an appropriate treatment to adjust the vision with regular frequent visits to the ophthalmologist. The most popular treatments are Medicines/Injections, Laser surgery, Vitrectomy, Cataract surgery [3,6].

- Medicines/Injection- Medications such as anti-vascular endothelial growth factor drugs or corticosteroids are prescribed. These drugs help to slow down the disease along with improvement in the vision of the eye.
- Laser surgery- It is also known as photocoagulation, in this, the laser creates tiny burns inside the eye which treats the leaking blood vessels, extra fluid by shrinking them. It considerably reduces the swelling of the eye and helps develop new blood vessels. However, it does not bring the vision loss back happened until the treatment starts but it prevents it from getting worse which is the most important. There are two types of laser surgery focal/grid laser and scatter laser surgery.
- Focal/Grid laser treatment- It focuses on the smaller area of the retina
- Scatter laser treatment- It is also called pan-retinal photocoagulation which covers a larger area.
- Vitrectomy- It is an outpatient surgery on the eye which heals the cloudy vision due to leaking of the blood vessel. A small incision is made and removal of scar tissue is done. It also removes the vitreous gel present in the eye.
- Cataract lens surgery- Cloudy lens in the eye is removed where the cataract is grown and replaced with an artificial lens in cataract lens surgery. Most people get better vision after cataract surgery.

The doctor can also recommend visits more often in a year along with the management of diabetes which includes control of sugar, blood pressure, and cholesterol which are the ABCs of diabetes. Doctors sometimes treat in combination with the above treatment to treat an individual.

## Complications

Complications caused due to diabetic retinopathy which involves abnormal growth of blood vessels can lead to serious vision threats to the eyes [4,9,10].

- Detachment of retina- Stimulation of the growth of the scar tissue is done by the abnormal blood vessels, which pulls the retina at the back. This can cause light flashes, floating spots, or severe vision loss



- Vitreous Hemorrhages- Newly formed blood vessels may bleed like a clear or jelly-like substance that fills the center portion of the eye. If the bleeding is small one can notice a floater in the vision whereas if it is large it may block the vision.
- Glaucoma- Sometimes the new blood vessels are grown in front of the iris which causes hindrances to the normal flow of fluid out of the eye which increases the pressure on the optic nerve which in turns damages it.
- Blindness- Combinations of several Diabetic Retinopathy can lead to permanent vision loss if they are poorly managed.
- Quit Smoking- Smoking increases the complications for a person suffering from diabetes and also for the person who has diabetic retinopathy. If a person is habitual to the consumption of tobacco by any means can seek advice from experts to quit them.
- Vision Changes- One needs to pay attention to the vision changes. Consult immediately with the ophthalmologist if there is a sudden change in the vision or vision has become blurry, hazy, or spotty.

It is not mandatory for a person with diabetes to suffer from vision problems. Active diabetic management with a noticeable change in lifestyle can prevent complications from diabetes-related to eyes in a long way.

### Prevention

One cannot prevent diabetic retinopathy. However, good control of blood glucose and blood sugar, early intervention for sight problems, regular eye check-ups can prevent severe vision loss. If a person is suffering from diabetes one can reduce the risk of getting diabetic retinopathy by taking the following preventive measures [1,3,5].

- Blood Sugar Management- A doctor can prescribe the need to monitor the sugar if a person is fallen ill or is under stress. Monitoring of blood sugar levels at regular intervals in a day is necessary
- Managing Diabetes- One needs to make healthy, active, nutritional choices to manage diabetes effectively. Performing work out daily of 30 minutes can also prevent the risk of diabetic retinopathy of a person suffering from diabetes. Prescribed medicines or insulin needs to be taken on time with proper diet alongside.
- Blood-Cholesterol- Pressure under control- Losing excess weight, eating healthy nutritious food and regular exercise minimum of 150 minutes weekly can help to control blood cholesterol and pressure level.
- Glycosylated hemoglobin test- One needs to ask or as prescribed by the doctor to perform glycosylated hemoglobin tests. This test reflects the average blood sugar for two to three months period before the test is performed. A person with good control of blood glucose level has an aim to maintain the value below 7% of the test.

### Conclusion - Surviving peacefully with Diabetic Retinopathy

The key is to undergo a yearly eye examination. During pregnancy tests needs to be carried out in the first trimester. One should not wait for the yearly appointments if noticed with black spots in the vision, sensitivity towards light or dark, holes in vision, and blurred vision. Visit and consult the ophthalmologists at the earliest. Once diabetic retinopathy is diagnosed one needs immediate treatment. Without a diagnosis, there is an increased chance of vision loss with blindness completely.

Treatment taken at the right time can stop the progression of the disease. The best way to keep oneself away from diabetic retinopathy is by maintaining blood glucose, blood cholesterol, and blood pressure levels at all times.

### Conflict of Interest

Nil.

### Source of Support

Nil.

### Bibliography

1. World Health Organization.
2. Centers for disease control (CDC)and prevention.
3. Eye and Glasses optometrist.
4. Mayo Foundation for medical education and research.

5. Wikipedia.
6. National Institute of Diabetes and Digestive and Kidney Diseases (NIDDK), part of the National Institutes of Health.
7. WebMD.
8. <https://www.aaopt.org/eye-health/diseases/diabetic-eye-disease>
9. Presentation of Dr. Tajinder Sehgal, CMO, NTPC Auraiya of Diabetic Retinopathy.
10. Slideshare-<https://pt.slideshare.net/sarosem/49-diabetic-retinopathy>
11. American Academy of Ophthalmology Retina-Vitreous Panel. Preferred Practice Pattern® Guidelines. Diabetic Retinopathy.