

## Sarcoidosis in Association with COVID-19

Attapon Cheepsattayakorn<sup>1-4\*</sup>, Ruangrong Cheepsattayakorn<sup>5</sup> and Porntep Siriwanarangsun<sup>1</sup>

<sup>1</sup>Faculty of Medicine, Western University, Pathumtani Province, Thailand

<sup>2</sup>Faculty of Medicine Vajira Hospital, Navamindradhiraj University, Bangkok, Thailand

<sup>3</sup>10th Zonal Tuberculosis and Chest Disease Center, Chiang Mai, Thailand

<sup>4</sup>Department of Disease Control, Ministry of Public Health, Thailand

<sup>5</sup>Department of Pathology, Faculty of Medicine, Chiang Mai University, Chiang Mai, Thailand

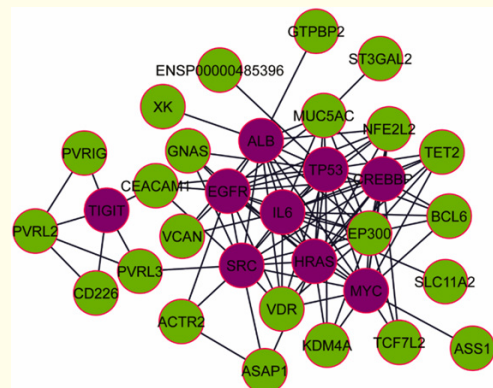
\*Corresponding Author: Attapon Cheepsattayakorn, 10th Zonal Tuberculosis and Chest Disease Center, Thailand.

Received: December 22, 2023

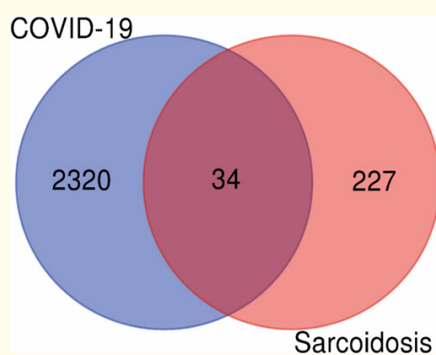
Published: January 01, 2024

© All rights are reserved by Attapon Cheepsattayakorn., et al.

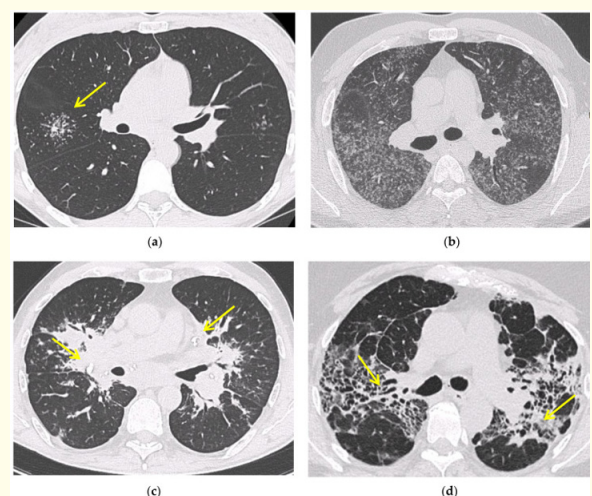
Several post-COVID-19 inflammatory disorders and autoimmune diseases have been discovered [1] since global COVID-19 pandemic started [2]. Association between these diseases is still to be investigated [2]. Common genes between COVID-19 and sarcoidosis are demonstrated in Figure 1, 2 [3]. Nevertheless, sarcoidosis organ involvement, demographics, and type of sarcoidosis treatment at the time of COVID-19 diagnosis are related to hospital admission, non-invasive ventilation or high flow oxygenation, intubation [4]. A retrospective hospital-based cohort study of 585 French sarcoidosis patients in 2017, demonstrated an estimate of a 5 % frequency of severe infections that resulting in hospital admission and death [5]. A typical HRCT feature in sarcoidosis is the presence of well-defined micronodules scattered along the broncho-vascular bundle, veins, fissures and pleura in a characteristic lymphatic distribution. Occasionally, “galaxy sign”, a highly suggestive of pulmonary sarcoidosis (predominance of a mid-to-upper lung zones) may demonstrates conglomerate masses that are surrounded by a multitude of micronodules (Figure 3) [6].



**Figure 2:** Demonstrating protein-protein interactions (PPIs) network for common upregulated genes from COVID-19 and sarcoidosis. The light green color nodes indicate common upregulated genes. Network consists of 32 nodes and 102 edges [3].



**Figure 1:** Demonstrating a Venn diagram of commonly differentially expressed upregulated genes. Common 34 upregulated genes were identified from 2320 upregulated genes of COVID-19 infection and 227 upregulated genes of sarcoidosis [3].



**Figure 3:** Demonstrating irregularly marginated nodule surrounded by multiple small nodules (“Galaxy sign”, yellow narrow), this is typical of sarcoidosis (a); ground-glass-like increased attenuation resulting from diffuse micronodules randomly distributed (“Miliary sarcoidosis”) (b); enlarged and partially calcified (yellow narrows) bilateral hilar lymph nodes (c); fibrotic sarcoidosis with cystic changes and traction bronchiectases (yellow narrows) predominantly in the perihilar region and upper lobes. Nodular abnormalities are minimal/absent, but the appearance and the location of the fibrosis are very suggestive of the diagnosis of sarcoidosis (d) [6].

Where VDR dominantly connected to 14 different kinds of drug, protein drug interaction network collected from DrugBank provides proper treatment. Vitamin D and some of its analogous compounds might play significant roles in modulating both COVID-19 and sarcoidosis conditions is indicated by this network (Figure 4) [3].

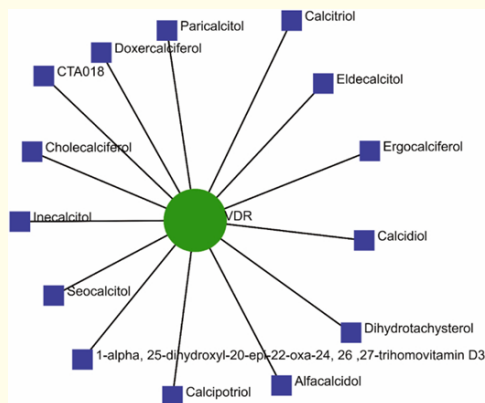


Figure 4: Demonstrating drugs protein interaction network [3].

Besides sarcoidosis of lungs, symptomatic and accidental extrapulmonary sarcoidosis is also found around the world (Figure 5, 6, 7) [7-9].

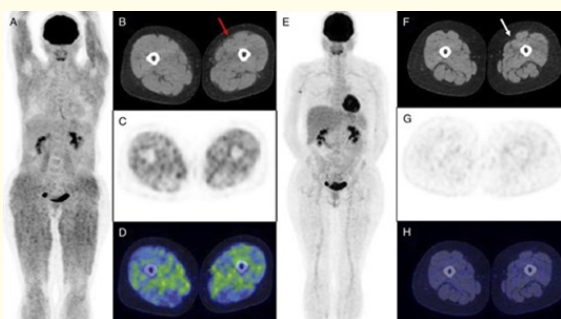


Figure 5: Demonstrating isolated muscular sarcoidosis, revealed by hypercalcemia and <sup>18</sup>F-FDG PET/CT [7].

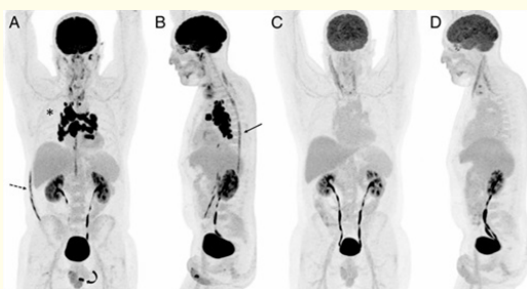


Figure 6: <sup>18</sup>F-FDG PET/MRI for Diagnosis and Treatment Efficacy Evaluation of Spinal Sarcoidosis [8].

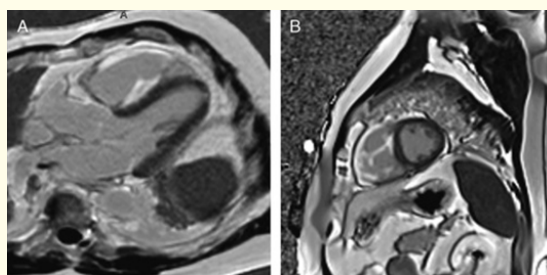


Figure 7: Demonstrating FDG PET of Isolated Right Ventricular Sarcoidosis [9].

In conclusion, hub gene identification might have significant roles in modulating sarcoidosis and COVID-19 infection. In the literature, cases with sarcoid-like granuloma have been reported very few. Sarcoid-like immune response to COVID-19 could be non-caseating granulomas due to short time from disease to develop granuloma.

### Bibliography

1. Galeotti C and Baryl J. "Autoimmune and inflammatory diseases following COVID-19". *Nature Reviews Rheumatology* 16.8 (2020): 413-414.
2. Racil H., et al. "Can coronavirus disease 2019 induce sarcoidosis : a case report". *Thoracic Research and Practice* 24.1 (2023): 45-48.
3. Mogal R., et al. "Common genetic aspects between COVID-19 and sarcoidosis : a network-based approach using expression data". *Biochemistry and Biophysics Reports* 29 (2022): 101219.
4. Nadeem O., et al. "Outcome in patients with sarcoidosis diagnosed with COVID-19". Presentation at Chest 2021 annual meeting (2021): 17-20.
5. Dureault A., et al. "Severe infections in sarcoidosis : incidence, predictors and long-term outcome in a cohort of 585 patients". *Medicine (Baltimore)* 96 (2017): e8846.
6. Bernardinello N., et al. "Pulmonary Sarcoidosis: Diagnosis and Differential Diagnosis". *Diagnostics (Basel)* 11.9 (2021): 1558.
7. Dhomps A., et al. "Isolated muscular sarcoidosis revealed by hypercalcemia". *Clinical Nuclear Medicine* 44.10 (2019): 824-825.
8. Ashjan K., et al. "<sup>18</sup>F-FDG PET/MRI for diagnosis and treatment efficacy evaluation of spinal sarcoidosis". *Clinical Nuclear Medicine* 49.1 (2024): e28-e30.
9. Alan S and Dagmar HS. "FDG PET of Isolated Right Ventricular Sarcoidosis". *Clinical Nuclear Medicine* 48.2 (2023): 184-185.