



Clinical Profile of A Plethora of Cases of Third Nerve Palsy

Reena Gupta*, Richa Sharma, Chekitaan Singh and Vandana

RIO, Post Graduate Institute of Medical Sciences, Rohtak, Haryana, India

*Corresponding Author: Reena Gupta, RIO, Post Graduate Institute of Medical Sciences, Rohtak, Haryana, India.

DOI: 10.31080/ASMI.2020.03.0470

Received: December 23, 2019

Published: December 30, 2019

© All rights are reserved by Reena Gupta, et al.

Abstract

Introduction: The primary nerve involved in the execution of ocular movements is the oculomotor nerve. The paralysis or paresis of extraocular muscles due to third nerve palsy, leads to ptosis, anisocoria and ocular motility defects. This paper aims to describe the cases of third nerve palsy presenting in our OPD with myriad of etiologies and a case-specific approach of management to achieve the best prognosis possible in each case.

Objective: To do descriptive analysis of cases of third nerve palsy on the basis of etiology, clinical presentation and management.

Materials and Methods: Descriptive analysis of twenty five cases of third nerve palsy presenting in OPD from January 2017 to August 2019 was done.

Conclusion: Amongst the twenty five cases, five were congenital, twenty were acquired. History taking and clinical examination with judicious use of neuroimaging was the mainstay for diagnosis. It was found that congenital and traumatic are the main causes in children, while traumatic and microvascular etiology is the main cause in adults. Surgery is needed in most cases except in the self resolving ones due to viral illness, vascular etiology and few cases of traumatic as well. Overall, there needs to be a customized approach for individual cases.

Keywords: Congenital; Acquired; Conservative; Diplopia; Ocular Alignment; Resection; Recession; Periosteal Fixation

Introduction

Third nerve palsy accounts for 1/3 of cranial nerve palsies [1]. Although it has similar causes in adults and children, but the frequency and occurrence is different in the two age groups. Intracranial aneurysms, atherosclerosis, hypertension, diabetes mellitus, dyslipidemia and inflammatory arteritis, constitute the most common causes in adults [2-7]. While, congenital factors, including instrumental delivery causing birth trauma, antenatal and intranatal factors causing neonatal hypoxia, are the leading causes of third nerve palsy in children [4,8,9,10]. Trauma is a fairly common cause of acquired third nerve palsy in both adults [11] and children [12,13]. Another age indiscriminatory cause of third nerve palsy in the two age groups is migraine. The headache along with transient third nerve palsy lasts for as long as 4 weeks. It presents usually with ptosis occurring before ophthalmoplegia. Migraine may involve other cranial nerves as well but it affects third cranial nerve alone in as many as 83% of cases [14]. The average age at onset is 15 years, but the palsy may occur in infancy, in which recurrent, painless ophthalmoplegia and/or ptosis may be the only manifestations of a migraine attack [15]. In older children ipsilateral oph-

thalmoplegia usually accompanies the headache. The rare causes of third nerve palsy in both the age groups include carotid cavernous fistula, frontal sinus mucocele and mesencephalic infarction. The mode of transmission of hereditary third nerve paresis may be either dominant or recessive. There is a spectrum of presentations with which third nerve palsy can present, that is, complete (presenting with complete ptosis covering a down and out deviated eye), incomplete (involves all of the muscles innervated by the third nerve but only to a slight extent or involves only some of the muscles innervated by the third nerve) [16], partially recovered third nerve palsy, multiple cranial nerve palsies associated with other cranial nerves such as fourth, fifth or sixth cranial nerves, combined third and sixth nerve palsy and finally, there can be third nerve palsy mimicking lesions for example, myasthenia gravis.

The management of third nerve palsy includes symptomatic treatment of diplopia and conservative/ surgical approach to achieve good ocular alignment with the target of maximum possible binocular vision for the patient. Relief from diplopia is achieved by occlusion of one eye with a patch, opaque contact lens or blurred

spectacle lens, although, ptosis itself acts as a natural patch in the cases manifesting it. Prisms can also be used to tackle diplopia. Prisms are primarily employed to improve alignment in primary gaze in cases where surgery is contraindicated. Also useful in cases with partial paralysis of the third nerve with the residual function of medial rectus. Drawback of prisms is that the multiplanar nature of diplopia in third nerve palsy is unlikely to be alleviated in eccentric gaze. Botulinum toxin is useful in cases of isolated involvement of medial rectus muscle because it paralyzes the antagonist lateral rectus temporarily and neutralizes horizontal deviation in the primary position. Remaining vertical deviation may need to be corrected by prisms or surgical therapy only.

Surgical management of third nerve palsy is very complex and challenging because of involvement of multiple muscles. Four out of the six extraocular muscles are involved and also the extent of involvement is variable. So a tailored base approach specific to each case has to be followed and the patient is to be counselled for staged surgeries in order to avoid risk of anterior segment ischemia and to achieve diplopia free binocular fields and optimal alignment in the primary position.

The following descriptive analysis of twenty five cases of third nerve palsy aims to describe the individualistic approach needed to manage each case, starting from history taking, examination, investigations till treatment, to achieve the best possible prognosis.

Material and Methods

Descriptive analysis of twenty five cases of third nerve palsy was done. Study period was from January 2017 to August 2019. Diagnosis of each case was made on documented history and examination. Examination of each patient was done based on visual acuity, refraction testing, pupillary reaction, anterior and posterior segment examination on slit lamp. Ocular motility testing was done including both versions and ductions followed by orthoptic evaluation for distance at 6 m and near at 33 cm using accommodative targets. Sensory evaluation was done using titmus fly test for near, distance randot stereotest for stereopsis at distance and worth 4 dot test for fusion. Diplopia charting was done at a distance of 1 m. Hess charting was done. Systemic and neurological examination was done. MRI brain and orbit were obtained only in indicated cases. Record was made of details of patient’s age, medical history, time from onset to presentation, trauma and documented pain. Cases were classified on basis of etiology – congenital, traumatic, idiopathic, microvascular, post viral illness, hyperlipidemia and leukemia. Subsequent recovery and length of follow up were noted. Follow up was done weekly for one month, once in two weeks till 3 months then monthly till six months. Then patients were subjected to management depending on the cause of palsy. Patients who did not improve even after six months were taken up for sur-

gery. Record was maintained of the conservative management or surgical treatment received by each patient.

Results and Observations

Twenty five cases of third nerve palsy were included in the study.

Age

Two cases were in the age group of 1 to 10 years. Six cases were in the age group of 11 to 20 years. Three were between 21 to 30 years of age, nine were between 31 to 40 years of age group and five were between 41 to 50 years of age (Table 1). Thus, the maximum number of cases lied in age-group of 31 to 40 years while the minimum number lied in the youngest age-group, that is, 1 to 10 years.

Age group	Number of cases (n=25)
1-10	2
11-20	6
21-30	3
31-40	9
41-50	5

Table 1: Distribution of cases according to age groups.

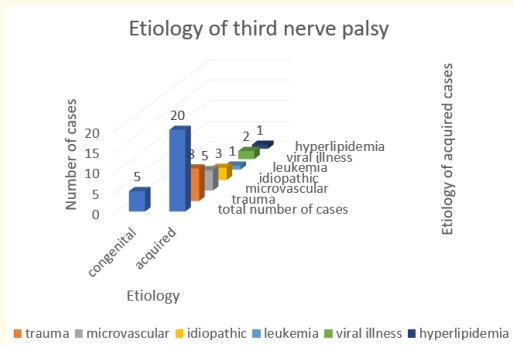
Gender

There were eight female patients and seventeen male patients (Table 2). Table 2 also shows the gender distribution throughout the spectrum of causes of third nerve palsy. The idiopathic category had two females and one male while there were one each in post viral illness category. In rest all categories, males were more than females.

Etiology	Male(n=17)	Female(n=8)
Congenital	5	0
Acquired		
Trauma	5	3
Microvascular	3	2
Idiopathic	1	2
Leukemia	1	0
Viral illness	1	1
Hyperlipidemia	1	0

Table 2: Distribution of cases according to gender.

On the basis of history, examination and investigations, as mentioned above, the cases were divided into congenital and acquired (Diagram 1). Five cases were congenital while twenty cases were acquired. Out of the acquired cases, eight were traumatic, five were having microvascular pathology, three were idiopathic, one had leukemia, two developed third nerve palsy after viral illness, while one had hyperlipidemia.



Bar diagram 1

Nine cases were managed conservatively, of which, two were post viral illness cases, one was post traumatic, one had acute lymphoblastic leukemia, one had hyperlipidemia, while four other had microvascular pathology. All of the conservatively managed cases achieved good ocular alignment between the duration of five to eight months post-presentation. The post viral illness cases started to show improvement after one month of presentation itself and were ocularly aligned at the end of 5 months. The post traumatic case showed drastic improvement by the end of seven months (Figure 1). Figure 1 shows the improvement that was evident in orthoptic evaluation by the end of seven months. The patient with hyperlipidemia recovered at the end of six months (Figure 2).

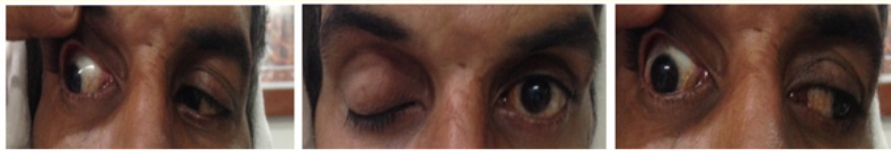

Figure 1A: a- 35 yrs male with right complete third nerve palsy after head on collision. CT scan showed subdural hemorrhage, subarachnoid hemorrhage and fracture of zygomatic arch with anterior wall of maxillary sinus. Reported 4 months after injury. Exotropia was of 35 BI 18 L/R. No diplopia with 25 BI 14 L/R.

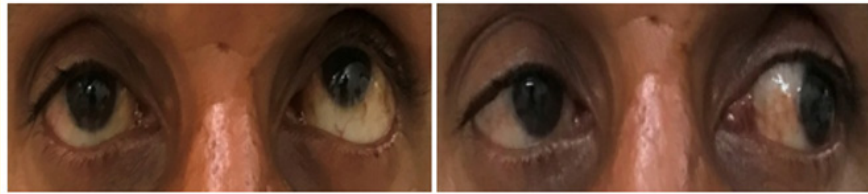


Figure 1B: 7 mths after trauma, ptosis and ocular motility improved Exotropia was 16 BI 8 L/R.

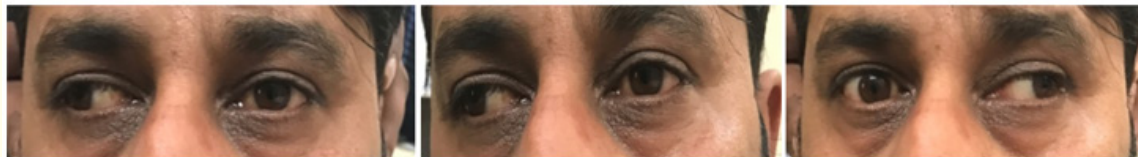

Figure 2A: 37 yrs male with sudden binocular diplopia. There was bilateral adduction limitation . It was a pupil involving isolated fascicular 3rd nerve palsy from an acute midbrain infarct due to hyperlipidemia(Total cholesterol- 400 mg/dL, HDL 30 mg/dL).

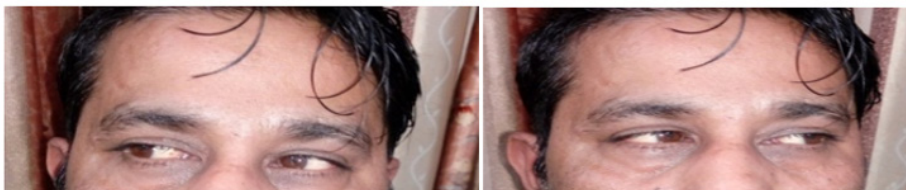


Figure 2B: Complete ocular motility was gained at the end of six months with control of lipid profile on medications and diet.

There was one male patient, 49 years old, who presented to us with right eye third nerve palsy that progressed from diplopia to moderate ptosis, over a period of one month as told by the patient. On routine blood investigations, the WBC count was found to be 20000/microlitre. Peripheral blood smear was sent to rule out any neoplastic etiology. The report confirmed the diagnosis of acute lymphoblastic leukemia. Patient was referred to the oncology department. Patient received induction and consolidation therapy constituting vincristine, dexamethasone and doxorubicin. There was evidential improvement observed in third nerve function on his monthly follow-up visits.

There were five cases categorised under microvascular pathology. All the four cases were diabetics and hypertensives. Three were on irregular medication since five years while two were on regular medications since three years. The blood profile and blood pressure measurement showed that uncontrolled status of blood glucose and blood pressure in all the five cases. They were referred to medicine department for further management. Four out of these patients achieved spontaneous recovery from third nerve palsy within 6 months, while one female had to undergo supramaximal resection and recession surgery done 8 months later post presentation.

Sixteen cases were managed surgically, amongst which five underwent supramaximal medial rectus resection and lateral rectus recession, four underwent KNAPPs procedure, one underwent lateral rectus fixation to periosteum, one had medial rectus fixation to periosteum, one got lateral rectus periosteal fixation followed by medial rectus periosteal fixation, three patients got superior oblique transposition done while one patient got nasal transposi-

tion of split lateral rectus done (Table 3). Table 3 shows the number of cases receiving each surgical procedure.

Procedure done	No. of cases
Knapp's procedure	4
Supramaximal recession + resection	5
Lateral rectus periosteal fixation	2
Medial fixation of globe	2
Superior oblique transpositioning	3
Nasal transpositioning of split lateral rectus	1

Table 3: Surgical procedures done in the cases.

Table 4 mentions the frequency of various surgical outcomes that were observed. Optimal ocular alignment was achieved in ten cases (Figure 3). Exotropic drift was observed in four cases, while improved ocular movements were achieved in four patients (Figure 4). Residual exotropia was there in five patients (Figure 5). Eight patients were relieved of diplopia after surgery while five patients required prism aid postoperatively for the same.

Outcome	No. of cases
Optimal ocular alignment	10
Residual exotropia	5
Exotropic drift	4
Improved ocular movements	4
Relief in diplopia	8
Prism requirement after surgery	5

Table 4: Outcomes of the surgical cases done in the cases.



Figure 3A: 17 yrs male with complete congenital third nerve palsy with no signs of aberrant regeneration with large angle exotropia with hypotropia with minimal tightness of LR muscle was taken for nasal transposition of split LR muscle.

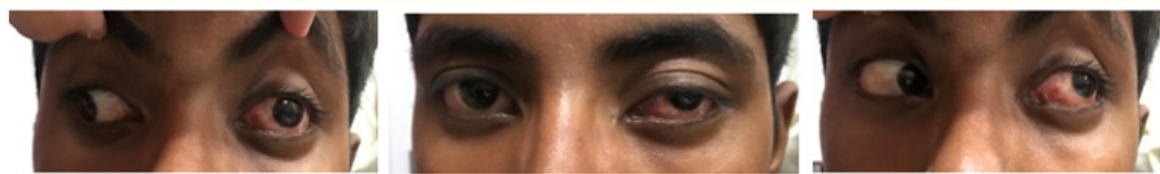


Figure 3B: Four weeks follow-up.




Figure 4A: 15 yrs girl with left eye ptosis and partial limitation in elevation, depression, adduction suggestive of partially recovered left third nerve palsy after head trauma. Exotropia of 55 BI 20 R/L in primary gaze increasing on dextroversion. Intraoperative Force duction test was negative. Modified Knapp LR Rc -8mm MR Rs 6mm was done on 14-8-17.




Figure 4B: 8 mths follow-up showing residual 12 BI 8R/L.

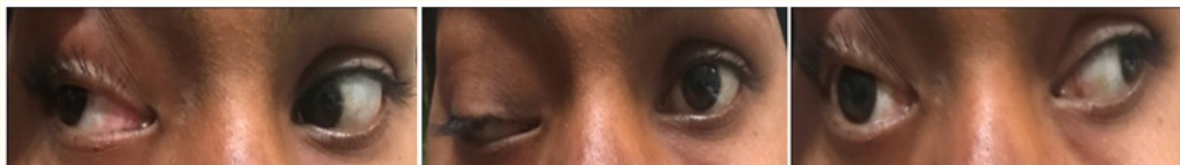


Figure 5A: 25 yrs old female presented with acquired longstanding isolated idiopathic complete right third nerve palsy from the last eight years. In primary position she had exotropia of 85 BI with 20R/L. We did LR periosteal fixation with MR resection 8mm done on 19-5-17.

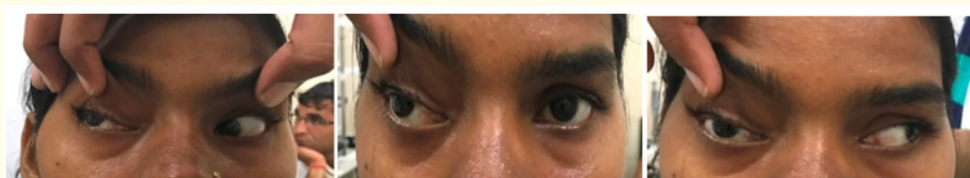

Figure 5B: On 2mths follow-up, residual exotropia was 45 BI 12R/L, -2 limitation of abduction and -1.5 improvement in adduction right eye.

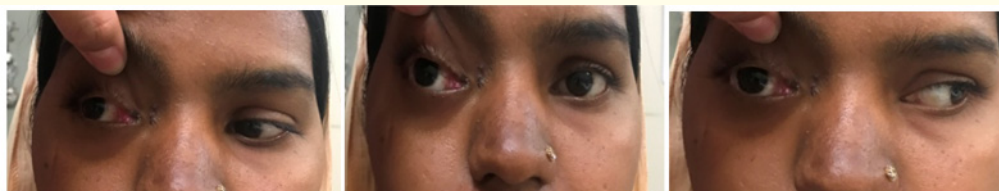

Figure 5C: Exploration of lateral rectus fixed to periosteum and removal of adhesions was done , intraoperative force duction test was free and then medial rectus periosteal fixation was done achieving good ocular alignment.

Discussion

Third nerve palsy can be congenital or acquired. Each case of congenital third nerve palsy needs to be evaluated for ptosis and extent of involvement, amblyopia, aberrant regeneration and Bell's phenomenon. The cause of complete third nerve palsy presenting in children is usually congenital. If the neuroimaging is normal and there is no neurologic deficit, the cause is usually antenatal or intranatal insult [8,9]. Aberrant regeneration is a common finding in congenital third nerve palsy. It may occur during the recovery phase after the insult. During assessment of versions and ductions, ipsilateral retraction of the upper lid may be observed on attempted adduction and/or attempted infraduction, as well as iris sphincter (pupillary) constriction. These abnormal movements are presumed to be caused by miswiring after a break in the axonal cylinders and subsequent misdirection of sprouting axons. Aberrant regeneration without an acute history of trauma may indicate an indolent space-occupying lesion, such as an aneurysm or tumor in the cavernous sinus. In such cases, neuroimaging holds a lot of importance for diagnosing as well as managing the case. Careful assessment and documentation of visual acuity is important in congenital third nerve palsy cases, to assess for amblyopia and if diagnosed, then amblyopia therapy should begin along with the treatment of third nerve palsy. Bell's phenomenon should be documented for its importance in ptosis correction.

Acquired third nerve palsy can have a spectrum of causes. The etiologies that we came across during our study period from January 2017 to August 2019, included trauma, microvascular pathology, hyperlipidemia, idiopathic, post-viral illness and leukemia. Nine of the twenty cases were managed conservatively. Since surgery is indicated in patients not recovering after 6 - 12 months and those having persistent stable-angle diplopia, therefore the rest of the acquired cases along with the congenital cases received surgical management. Aim of the surgical management was kept to be optimal alignment of two eyes in primary position and expansion of binocular visual field. The norm is to do resection and recession surgery in patients with partial third nerve palsy. Five of our patients, of which two were post traumatic, two were idiopathic, while had microvascular pathology, received supramaximal resection and recession resulting in acceptable ocular alignment.

Patients having total/complete third nerve palsy were subjected to more customized surgeries, other than resection and recession. Four post traumatic cases underwent modified KNAPP's procedure, with acceptable surgical outcome. Two patients received lateral rectus periosteal fixation, of which one had to undergo a revision surgery with addition of nasal periosteal fixation of medial rectus due alleviate residual exotropia. One of these two patients was a congenital complete third nerve palsy case while the other one who received two-staged surgery was an idiopathic case.

Both the cases had acceptable surgical outcomes. The idea behind lateral periosteal fixation is that the complete inactivation of lateral rectus muscle force by orbital wall fixation eliminates all residual lateral rectus function and prevents reattachment to the globe. As the muscle is still retrievable, the procedure is reversible. Morad, *et al.* reviewed the records of four patients with third cranial nerve paralysis and one with Duane syndrome with exotropia in which the lateral rectus muscle was removed from its scleral insertion and reattached to the orbital wall. All patients achieved satisfactory ocular alignment following surgery. These results were stable for 1.5 - 4 years of follow-up [17]. Velez, *et al.* in their study showed that in cases of third nerve palsy there was no improvement of adduction while there was residual abduction despite inactivation of the lateral rectus muscle and supramaximal resection of the medial rectus muscle, which suggest that the connective tissue also undergo secondary contracture in cases of longstanding deviation [18]. Medial rectus fixation to nasal periosteum is done in complete third nerve palsy cases usually with no residual function of medial rectus, that is, congenital and traumatic cases. Anchoring materials used are periosteal flaps, silicone bands, superior oblique tendon, 5 - 0 polyester sutures. This surgery aims for 10 - 15 degree of esotropia intraoperatively. Exotropic drift usually occurs but stabilizes after 4-6 weeks. In a recently published case series by Morad *et al.*, fixation of both the rectus muscles to the periosteum was done to achieve satisfactory alignment. However it should be noted that medial anchoring of the globe along with the lateral rectus muscle weakening in the form of supramaximal recession is an effective procedure. Precaruncular approach is preferred over transcaruncular / external skin incision because it is a direct route, path of dissection is avascular and there is optimal exposure.

Three patients got superior oblique transposition to medial rectus done, all were congenital complete nerve palsy cases, one of them had previously received lateral rectus tenotomy with medial rectus resection from elsewhere. The two methods mentioned in literature for superior oblique transposition, one is transposition of superior oblique after fracture of trochlea, and disinserting the muscle, while other is modified by transposing superior oblique without fracture of trochlea. Second method gives better horizontal and vertical alignment, and improves A-pattern and intorsion, thus leading to better binocular interaction. Limitation of both the methods is resultant paradoxical ocular movements and induced hypertropia [20].

One patient of complete congenital third nerve palsy was operated and surgery done was nasal transposition of split lateral rectus. Acceptable ocular alignment was achieved in this patient. Taylor, *et al.* had described complete transposition of the lateral rectus muscle to the medial globe to facilitate the medial rotation of the eye upto the primary gaze [21]. Y-splitting of the lateral rectus

and its transposition to retro equatorial points 20 mm posterior to the limbus near the nasal superior and the inferior vortex veins [22] or to points 1mm posterior to the superior and inferior borders of the MR insertion without [23] or with posterior fixation sutures [24] have been described. The latter procedure described by Saxena R., *et al.* modified the technique described by Gokyigit B., *et al.* by placing non-absorbable sutures to fix each split belly of the transposed lateral rectus muscle to the sclera at the equator adjacent to the medial rectus. They postulated that the posterior fixation sutures augment the force of the transposed muscles by redirecting the force vectors in the direction of action of the medial rectus resulting in minimum residual exotropia.

Therefore, a tailored base approach specific to each case has to be followed and the patient is to be counselled for staged surgeries in order to avoid risk of anterior segment ischemia and to achieve diplopia free binocular fields and optimal alignment in the primary position.

Conclusion

Third nerve palsy has a wide spectrum of presentation and other associated features. Common etiologies in adult population are trauma and microvascular causes while in children are congenital and trauma. Surgery remains the mainstay of treatment. In our scenario, recovery occurred in almost 60% of the cases. Complete remission was seen in vascular palsies with partial involvement or viral illness. Partial recovery was seen in traumatic cases and idiopathic cases. We conclude that a meticulous history and clinical examination with judicious use of neuroimaging remain the most discriminating tool in assessment and in localizing the causative lesion. Correction of strabismus due to third nerve palsy can be complex and needs tailored approach.

Bibliography

1. Shechtman DL, *et al.* "Pupil sparing incomplete third nerve palsy secondary to cavernous sinus meningioma: challenges in management". *Clinical and Experimental Optometry* 90.2 (2007): 132-138.
2. Burde R, *et al.* "Clinical Decisions in Neuro-Ophthalmology". p 178. St. Louis, CV Mosby (1985).
3. Goldstein JA and Cogan D. "Diabetic ophthalmoplegia with special reference to the pupil". *Archives of Ophthalmology* 64 (1960): 592.
4. Green W, *et al.* "Neuro-ophthalmologic evaluation of oculomotor nerve paralysis". *Archives of Ophthalmology* 72 (1964): 154.
5. Long SZ, *et al.* "Etiological analysis of 246 cases of oculomotor palsy". *Chung Hua Yen Ko Tsa C'hih* 30 (1994): 31.
6. Rucker C. "Paralysis of the third, fourth, and sixth cranial nerves". *American Journal of Ophthalmology* 46 (1958): 787.
7. Rush JA and Young BR. "Paralysis of cranial nerves III, IV and VI: Cause and prognosis in 1000 cases". *Archives of Ophthalmology* 99 (1981): 76.
8. Harley RD. "Paralytic strabismus in children: Etiologic incidence and management of the third, fourth, and sixth nerve palsies". *Ophthalmology* 87 (1980): 24.
9. Miller NR. "Solitary oculomotor nerve palsy in childhood". *American Journal of Ophthalmology* 83 (1977): 106.
10. Prats JM, *et al.* "Congenital nuclear syndrome of oculomotor nerve". *Pediatric Neurology* 9 (1993): 476.
11. Tokuno T, *et al.* "Primary oculomotor nerve palsy due to head injury: Analysis of 10 cases". *No Shinkei Geka* 23 (1995): 497.
12. Ing EB, *et al.* "Oculomotor nerve palsies in children". *Journal of Pediatric Ophthalmology and Strabismus* 29 (1992): 331.
13. Kodsi SR and Younge BR. "Acquired oculomotor, trochlear, and abducent cranial nerve palsies in pediatric patients". *American Journal of Ophthalmology* 114 (1992): 568.
14. Vijayan N. "Ophthalmoplegic migraine: Ischemic or compressive neuropathy?" *Headache* 20 (1980): 300.
15. Durkan GP, *et al.* "Recurrent painless oculomotor palsy in children. A variant of ophthalmoplegic migraine?" *Headache* 21 (1981): 58.
16. Shechtman DL, *et al.* "Pupil sparing incomplete third nerve palsy secondary to a cavernous sinus meningioma: challenges in management". *Clinical and Experimental Optometry* 90 (2007): 132-138.
17. Morad Y, *et al.* "Lateral rectus muscle disinsertion and reattachment to the lateral orbital wall". *British Journal of Ophthalmology* 89 (2005): 983-985.
18. Velez FG, *et al.* "Rectus muscle orbital wall fixation: A reversible profound weakening procedure". *Journal of AAPOS* 8 (2004): 473-480.
19. Saxena R, *et al.* "Precaruncular approach for medial orbital wall periosteal anchoring of the globe in oculomotor nerve palsy". *Journal of AAPOS* 13 (2009): 578-582.
20. Singh A, *et al.* "Impact of Superior Oblique Transposition on Primary Position Deviation, a Pattern and Intorsion in Third Nerve Palsy". *Strabismus* 24.4 (2016): 173-177.
21. Taylor JN. "Surgical management of oculomotor nerve palsy with lateral rectus transposition to the medial side of the globe". *Australia NZJ Ophthalmology* 17 (1989): 27-31.

22. Kaufmann H. "Lateralis splitting" in total oculomotor paralysis with trochlear nerve paralysis". *Fortschritte der Ophthalmologie* 88 (1991): 314-316.
23. Gokyigit B., *et al.* "Medial transposition of split lateral rectus muscle for complete oculomotor nerve palsy". *Journal of American Association for Pediatric Ophthalmology and Strabismus* 17 (2013): 402-410.
24. Saxena R., *et al.* "Medial transposition of split lateral rectus augmented with fixation sutures in cases of complete third nerve palsy". *British Journal of Ophthalmology* (2016): 1-3.

Assets from publication with us

- Prompt Acknowledgement after receiving the article
- Thorough Double blinded peer review
- Rapid Publication
- Issue of Publication Certificate
- High visibility of your Published work

Website: <https://www.actascientific.com/>

Submit Article: <https://www.actascientific.com/submission.php>

Email us: editor@actascientific.com

Contact us: +91 9182824667