



## Callow and Ambivalent - Sialoblastoma

**Anubha Bajaj\***

*Department of Histopathology, Panjab University/A.B. Diagnostics, India*

**\*Corresponding Author:** Anubha Bajaj, Department of Histopathology, Panjab University/A.B. Diagnostics, India.

**Received:** September 01, 2023

**Published:** November 07, 2023

© All rights are reserved by **Anubha Bajaj**.

### Abstract

Sialoblastoma is an exceptionally discerned, malignant neoplasm of salivary gland. Neoplasm is reminiscent of primitive epithelial anlage of salivary glands and is especially indicative of an arrested stage of differentiation. Previously designated as congenital basal cell adenoma, embryoma, or basaloid adenocarcinoma, the low-grade tumefaction may appear as a congenital lesion and is commonly discerned within the neonatal period.

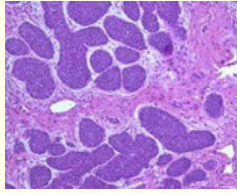
**Keywords:** Sialoblastoma; Ambivalent

### Introduction

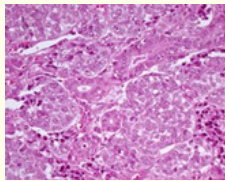
Sialoblastoma appears as an epithelial salivary gland tumour frequently incriminating paediatric subject. Generally, the rapidly progressive tumefaction represents as a perinatal neoplasm. Localized tumour reoccurrence may ensue. Additionally, tumour metastasis into regional lymph nodes or pulmonary parenchyma may occur. Notwithstanding, perineural tumour invasion is absent. Sialoblastoma is exemplified within submandibular salivary gland, parotid gland or minor salivary glands. Parotid gland is predominantly implicated. Besides, ectopic salivary gland tissue may demonstrate the neoplasm [1,2]. Majority of incriminated subjects are < 2 years. Tumefaction is commonly encountered within the neonatal period. A mild male predominance is observed with male to female proportion of ~1.2:1. Although non specific, cogent clinical symptoms frequently emerge as a rapidly progressing tumour mass. Superimposed cutaneous surface appears ulcerated. Concurrence with various neoplasms as nevus sebaceous or hepatoblastoma is exceptional and documented [1,2]. Upon cytological examination, smears display cohesive, solid cellular clusters. Tumour cell aggregates are constituted of atypical basaloid epithelial cells. Disseminated epithelial cells and myoepithelial cells appear commingled with metachromatic hyaline globular substance which stains magenta upon haematoxylin and eosin (H and E) stain

[2,3]. Grossly, tumefaction may manifest as a singular nodule or a multinodular neoplasm. The lobular tumefaction may depict focal necrosis or haemorrhage. Tumour magnitude varies from 2 centimetres to 7 centimetres. Upon microscopy, neoplasm manifests ductules or solid, organoid nests of basaloid tumour cells. Tumefaction is constituted of basaloid cells configuring solid nests, tumour nodules or trabecula with foci of peripheral nuclear palisading. Occasionally, ductules may be articulated. A component of cuboidal epithelial cells may be discerned [2,3]. Nuclei of neoplastic basaloid cells appear spherical to elliptical and are permeated with delicate, fine nuclear chromatin with singular, prominent nucleolus. Nuclear atypia is variable. Intervening stroma is loose, immature or may appear myxoid. Morphological features appear to recapitulate embryonic development of salivary glands encountered within third month of foetal gestation [2,3]. Sialoblastoma manifests with distinct histological patterns designated as ~partially encapsulated tumour with a component of benign, bland basaloid cells commingled with encompassing desmoplastic stroma. The pattern is associated with superior prognostic outcomes ~tumefaction composed of anaplastic basaloid epithelial cells. Tumour perimeter appears as broad and pushing or infiltrates into circumscribing soft tissue. Intervening stroma is minimal. Perineural or perivascular invasion may be exemplified. The pattern is associated with adverse prog-

nostic outcomes. Tumour necrosis and mitotic activity is variable [2,3].



**Figure 1:** Sialoblastoma delineating nests and clusters of bland basaloid cells configuring broad, pushing tumour perimeter. Intervening stroma is desmoplastic. Necrosis and mitosis are minimal [6].



**Figure 2:** Sialoblastoma depicting trabeculae and cell nests composed of basaloid and myoepithelial cells imbued with pleomorphic nuclei. Intervening stroma is minimal and desmoplastic [7].

TNM staging of major salivary gland neoplasms [2,3].

**Primary tumour**

•TX: Primary tumour cannot be assessed •T0: No evidence of primary tumour •Tis: Carcinoma in situ •T1: Tumour ≤2 centimetre in greatest dimension in the absence of extra-parenchymal extension •T2: Tumour >2 centimetre and ≤4 centimetre in greatest dimension with absence of extra-parenchymal extension •T3: Tumour >4 centimetre in greatest dimension OR tumour with extra-parenchymal extension •T4: is comprised of ~T4a: moderately advanced, localized disease wherein tumour invades cutaneous surface, mandible, external auditory canal and/or facial nerve ~T4b: very advanced, localized disease wherein tumour invades base of skull, pterygoid plates or encases carotid artery. Extra-parenchymal extension indicates clinical or macroscopic, pathological evidence of soft tissue tumour invasion in concurrence with microscopic evidence of disease dissemination.

**Regional lymph nodes (clinical staging)**

•NX: Regional lymph nodes cannot be assessed •N0:Regional lymph node metastasis absent •N1: Regional lymph node metastasis confined within singular, ipsilateral lymph node ≤3 centimetre magnitude with absent extra-nodal extension (ENE-) •N2: is categorized as ~N2a: Regional lymph node metastasis confined to singular, ipsilateral lymph node >3 centimetre and ≤6 centimetre magnitude with absent extra-nodal extension (ENE-) ~N2b: Regional lymph node metastasis confined to multiple, ipsilateral lymph nodes ≤6 centimetre magnitude with absent extra-nodal extension ENE(-) ~N2c: Regional lymph node metastasis confined to bilateral or contralateral lymph nodes ≤6 centimetre magnitude with absent extra-nodal extension (ENE-) •N3: is categorized into ~N3a: Regional lymph node metastasis into a node >6 centimetre magnitude with absent extra-nodal extension (ENE-) ~N3b: Regional lymph node metastasis into a node demonstrating clinically overt extra-nodal extension (ENE+ or ENE<sub>c</sub>) OR regional lymph node metastasis into singular, ipsilateral lymph node >3 centimetre in greatest dimension with tumour invasion beyond the lymph node OR regional lymph node metastasis into> singular, ipsilateral, contralateral or bilateral lymph nodes as the primary tumour ≤3 centimetre in greatest dimension with tumour invasion beyond the lymph node OR regional lymph node metastasis into singular, contralateral lymph node ≤3 centimetre magnitude with tumour extension beyond the lymph node.

**Regional lymph nodes (pathological staging)**

•NX: Regional lymph nodes cannot be assessed •N0: Regional lymph node metastasis absent •N1: Regional lymph node metastasis confined within singular, ipsilateral lymph node ≤3 centimetre magnitude with absent extra-nodal extension (ENE-) •N2: is categorized into ~N2a: Regional lymph node metastasis confined within singular, ipsilateral lymph node >3 centimetre and ≤6 centimetre magnitude with absent extra-nodal extension (ENE-) OR regional lymph node metastasis confined to singular, ipsilateral lymph node ≤3 centimetre magnitude with extra-nodal extension(ENE+) ~N2b: Regional lymph node metastasis confined to multiple, ipsilateral lymph nodes ≤6 centimetre magnitude and absent extra-nodal extension (ENE-) ~N2c: Regional lymph node metastasis confined to bilateral or contralateral lymph nodes ≤6 centimetre magnitude and absent extra-nodal extension (ENE-) •N3: is categorized as ~N3a: Regional lymph node metastasis confined to lymph node >6 centimetre magnitude with absent extra-nodal extension

(ENE-) ~N3b: Regional lymph node metastasis confined to singular, ipsilateral lymph node >3 centimetre magnitude with extra-nodal extension (ENE+) OR multiple, ipsilateral, contralateral or bilateral lymph nodes with extra-nodal extension (ENE+) within singular or multiple sites OR singular, contralateral lymph node of variable magnitude and extra-nodal extension (ENE+)

### Distant metastasis

•M0: Distant metastases absent •M1: Distant metastasis present into sites as pulmonary parenchyma •pM1: Distant metastasis present, confirmed with microscopic examination.

Ductal configurations of sialoblastoma appear immune reactive to cytokeratin, CK7 or CK19. Basaloid or myoepithelial tumour cells are immune reactive to S100 protein, smooth muscle actin(SMA), muscle specific actin (MSA), calponin or p63. Besides, immune reactivity to alfa fetoprotein (AFP), cytoplasmic HER2 or p53 is observed. Ki67 proliferative index is elevated within reoccurring lesions. Enhanced values are indicative of aggressive biological behaviour and unfavourable prognostic outcomes [4,5]. Sialoblastoma requires segregation from neoplasms such as adenoid cystic carcinoma, basal cell adenoma, pleomorphic adenoma or teratoma [4,5]. Ultrasonography can be appropriately adopted for prenatal screening of the neoplasm. Magnetic resonance imaging (MRI) exhibits non-specific features [4,5]. Cogent therapeutic strategy for managing sialoblastoma is comprehensive surgical extermination of the neoplasm.

### Conclusion

Adjuvant chemotherapy can be adopted for treating lesions which are unamenable to comprehensive surgical eradication. However, chemotherapy employed for alleviating paediatric lesions may be associated with extended adverse effects. Besides, brachytherapy can be optimally adopted as a singular, beneficial therapeutic option [4,5].

### Bibliography

1. Nishida H., *et al.* "Histopathological Aspects of the Prognostic Factors for Salivary Gland Cancers". *Cancers (Basel)* 15.4 (2023): 1236.
2. Cruz VMS., *et al.* "Clinicopathological study and survival outcomes of sialoblastoma: A systematic review". *Head Neck* (2023).
3. Opiła R., *et al.* "Infant with Parotid Sialoblastoma and Nevus Sebaceous, Treated with Surgery and Adjuvant Chemotherapy". *Children (Basel)* 10.4 (2023):628.
4. Manou M., *et al.* "Role of Histone Deacetylases in the Pathogenesis of Salivary Gland Tumors and Therapeutic Targeting Options". *International Journal of Molecular Sciences* 24.12 (2023):10038.
5. Yang R., *et al.* "The Cellular and Molecular Landscape of Synchronous Pediatric Sialoblastoma and Hepatoblastoma". *Frontiers in Oncology* 12 (2022): 893206.
6. Image 1 Courtesy: Science direct.
7. Image 2 Courtesy: Wikipedia.