



Preoperative Transarterial Chemoinfusion in the Treatment of Patients with Gastric Cancer

Arybzhhanov DT^{1,3*}, Gantsev ShKh² and Sburov AR^{1,2}

¹The Head of the Department of Chemotherapy and Endovascular Oncology of Shymkent City Cancer Center, Candidate of Medical Science, Professor of the Department of Surgical Disciplines No. 2 of South-Kazakhstan Medical Academy, Kazakhstan

²Professor, the Head of the Department of Oncology with the courses of Institute of Postgraduate Education in Oncology and Pathological Anatomy of Bashkir State Medical University, Ufa, Russia

³Oncologist, Postgraduate Student of the Department of Oncology with the courses of Institute of Postgraduate Education in Oncology and Pathological Anatomy of Bashkir State Medical University, Ufa, Russia

***Corresponding Author:** Arybzhhanov DT, The Head of the Department of Chemotherapy and Endovascular Oncology of Shymkent City Cancer Center, Candidate of Medical Science, Professor of the Department of Surgical Disciplines No. 2 of South-Kazakhstan Medical Academy, Kazakhstan.

Received: June 24, 2022

Published: July 29, 2022

© All rights are reserved by **Arybzhhanov DT, et al.**

Abstract

Nowadays, the technique of intra-arterial chemotherapy in primary patients with gastric cancer can be considered as an effective, low-toxic method of treatment. Preoperative intra-arterial chemotherapy may be the method of choice for improving the survival and quality of life of patients with gastric cancer.

Nowadays, results of the diagnosis and treatment of gastric cancer (GC) are still unsatisfactory. With the development of modern catheters and angiographic devices, regional chemotherapy in patients with gastric cancer has become more often used in clinical practice.

Goal of the research: Improving the response to treatment of patients with gastric cancer using regional intra-arterial chemotherapy (RIAC).

Materials and methods: There were analyzed short and long-term results of combination therapy of 110 patients with gastric cancer for the period of 2005-2020. The average age of patients was 59.2 ± 4.3 years old. The incidence of neoplastic process according to the TNM classification was as follows: T3N0M0 - 37 (33.63%) patients, T3N1M0 - 41 (37.27%) patients and T3N2M0 - 32 (29.1%) patients. Histologically, various forms of adenocarcinoma were diagnosed in all patients

All patients underwent the first stage of neoadjuvant intra-arterial chemotherapy (RIAC) according to the DPF scheme (Docetaxel 75mg/m² + Cisplatin 75mg/m² + Fluorouracil 1000mg/m² on the 1st day), it comprised 2 cycles with an interval of 28 days, and then, there was performed surgery.

Results and their discussion: Short-term results of RIAC showed the effectiveness of treatment after 2 cycles of neoadjuvant intra-arterial regional chemotherapy; 93 (84.5%) patients showed partial regression, 17 (15.5%) patients showed stabilization of the process. These patients underwent radical surgery with the second stage of combination therapy - extended gastrectomy with D2 lymphodissection.

The medicinal pathomorphosis of 1-2 grade was represented in 34 (30.9%) patients, pathomorphosis of the 3rd grade was represented in 38 (34.5%) patients, pathomorphosis of the 4th grade - 9 (8.1%) patients. The case follow-up showed the following results: 9 (8.1%) patients lived for 6 months, 63 (57.2%) patients lived for 12 months, 59 (53.3%) patients lived for 18 months, 57 (51.8%) patients lived for 24 months, 47 (42.7%) patients lived for 36 months, 41 (37.2%) patients lived for 48 months and 35 (31.8%) patients continue to live for 60 months or more. Median survival was 51.8 +1.5 months.

Conclusion: Neoadjuvant RIAC in the treatment of patients with gastric cancer was effective in 84.5% of patients. In 42.6% of patients, there was represented therapeutic pathomorphosis of 3-4 grade. The 3 and 5-year survival rates were 42.7% and 31.8%, respectively. Median survival was 51.8 +1.5 months

Keywords: Gastric Cancer; Intra-Arterial Chemotherapy; Surgical Treatment; Survival

Introduction

According to International Agency for Research on Cancer, gastric cancer (GC) rate around the world ranks the 5th place, and the mortality rate ranks the 3rd place; more than 1 million new cases of GC are diagnosed annually worldwide and more than 768 thousand patients die (GLOBOCAN, 2020). In the Republic of Kazakhstan, GC rate ranks the 4th place among all malignant neoplasms (19-20 per 100 000 population), mortality rate ranks the 2nd place (10.5%) [2]. In Russia, GC rate ranks the 3rd place (25.8 per 100 000 population), and mortality rate - the 2nd place (10, 3%) [1-3].

Despite the significant growth and development of modern medicine as well as measures taken for the early diagnosis of gastric cancer, III-IV disease stages (over 50%) and mortality rate during the year after the first diagnosis (up to 25-30%) are still high. In Asian countries, GC mortality rate reaches 75% [3,4].

Nowadays, results of the diagnosis and treatment of GC still do not satisfy clinicians, as the five-year survival rates remain low. Unresectable gastric cancer is treated with surgical interference, which should include D2 lymphadenectomy (including lymph nodes in the perigastric mesentery and along the branches of celiac artery).

Perioperative or adjuvant chemotherapy improves the survival of patients with 1B cancer stage or higher. Advanced gastric cancer

is treated with sequential lines of chemotherapy, starting with platinum and fluoropyrimidine doublet in the first line; median survival is less than 1 year [4]. The use of neoadjuvant chemotherapy for GC was one of the first to be engaged in by B.N. Zyryanov, *et al.* The authors injected 5-fluorouracil into the celiac trunk, and after 2 weeks there was performed surgery. According to the authors, partial regression of the tumor occurred in 38% of patients, the frequency of postoperative complications decreased by 3 times [6]. Barone C., Cassano A., Pozzo C., *et al.* use neoadjuvant chemotherapy in 56 patients with histologically verified GC, it was diagnosed II cancer stage or higher with metastatic lymph nodes and with or without distant metastases (T2-4, N1-3 and M0-1). Patients were treated with a combination of intravenous administration of 5-Fu (370 mg/m²) and leucovorin (200 mg/m²) on the 1st -5th days and intra-arterial etoposide (80 mg/m²) and cisplatin (80 mg/m²) on the 6th and 20th days. After two preoperative chemotherapy cycles, patients with resectable tumors underwent surgery. The overall response was 78.57% (44 cases), of which 7.14% (4 cases) was clinically complete. The resection was performed in 46 patients. The average survival rate for patients with initial surgery was 41 months and inoperable patients - 18 months [7].

With the development of modern catheters and angiographic devices, the use of regional chemotherapy in patients with gastric cancer opens up wider opportunities [8-12].

Goal of the Research

Improving the response to treatment of patients with gastric cancer using regional intra-arterial chemotherapy (RIAC).

Materials and Methods

We analyzed short and long-term results of combination therapy of 110 patients with gastric cancer treated at Shymkent City Cancer Center for the period of 2005-2020. All 110 patients were admitted to the clinic with a primary tumor.

By age, the patients were distributed as follows: 41-50 years old - 44% of patients, 51-60 years old - 26% of patients and over 60 years old - 30%. The average age of patients was 59.2 ± 4.3 years. The duration of anamnesis ranged from 1 to 12 months, averaging 6, 7 months.

The incidence of neoplastic process according to the TNM classification was as follows: $T_3N_0M_0$ - 37 (33.63%) patients, $T_3N_1M_0$ - 41 (37.27%) patients and $T_3N_2M_0$ - 32 (29.1%) patients. Histologically, various forms of adenocarcinoma were diagnosed in all patients.

All patients underwent the first stage of neoadjuvant intra-arterial chemotherapy according to the DPF scheme (Docetaxel 75mg/m² + Cisplatin 75mg/m² + Fluorouracil 1000mg/m² on the 1st day), it comprised 2 cycles with an interval of 28 days, and then, there was performed surgery. The essential of intraarterial infusion of cytostatics is as follows: one of the femoral arteries is punctured and catheterized according to the Seldinger technique, the technique is performed in X-ray operating room under regional anesthesia with a solution of 0.5% novocaine (30-40 ml). Under X-ray control, an intraarterial catheter was selectively installed in the left gastric artery, if it was not possible to selectively catheterize the left gastric artery, an angiographic catheter was installed in the abdominal trunk, thus covering blood supply to the organs of the upper portion of the abdominal cavity. After that, it is performed a control angiography to determine the correct catheter insertion (Figure 1).

Next, it was performed intra-arterial infusion of cytostatics at an infusion rate of 1000-1200ml/hour using the Infusomat device (Braun FM-5, Germany). The total infusion time did not exceed 3-4 hours. After the procedure, the catheter is removed, the femoral

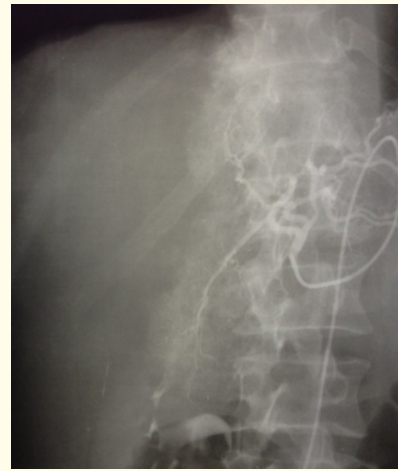

Figure 1: Dynamics of the content of dendritic cells of the central zone of the classical lobules.

artery puncture area was sutured with an ANGIO-SEAL device, and the patient was transferred to the ward. Subsequently, depending on the response of neoadjuvant chemotherapy, patients underwent the next stage of treatment.

Results and their Discussion

The effectiveness of neoadjuvant RIAC in gastric cancer was evaluated after each cycle using clinical, radiological and endoscopic research methods. Short-term results showed the effectiveness of treatment after 2 cycles of neoadjuvant intra-arterial regional chemotherapy, 93 (84.5%) patients showed partial regression, 17 (15.5%) patients showed stabilization of the process. These patients underwent radical surgery with the second stage of combination therapy - extended gastrectomy with D2 lymphodissection.

In 5 (4.5%) cases, surgical intervention resulted in palliative surgery of the tumor due to adjacent organ extension (liver, pancreas). Subsequently, in 3 (2.72%) cases, in the course of the treatment, there was represented progression and dissemination of the process in the peritoneal cavity with ascites, which led to a deterioration in the general state of patients, and they were discharged for symptomatic treatment in the home area. The study of the removed histological material of the stomach after surgery showed the presence of medicinal pathomorphosis of 1-2 grade in 34 (30.9%) patients, pathomorphosis of the 3rd grade was rep-

resented in 38 (34.5%) patients, pathomorphosis of the 4th grade - 9 (8.1%) patients. Taking into account the results of histological examination and presence of therapeutic pathomorphosis, 80 (72.7%) patients underwent adjuvant chemotherapy according to the same scheme during the 1st month after radical surgery. All patients underwent 4 cycles of adjuvant chemotherapy. The further condition of patients is observed according to the terms of preventive medical examination.

The case follow-up in 6, 12, 18, 24, 36, 48 and 60 months showed the following results: 9 (8.1%) patients lived for 6 months, 63 (57.2%) patients lived for 12 months, 59 (53.3%) patients lived for 18 months, 57 (51.8%) patients lived for 24 months, 47 (42.7%) patients lived for 36 months, 41 (37.2%) patients lived for 48 months and 35 (31.8%) patients continue to live for 60 months or more. Median survival was 51.8 ± 1.5 months (Figure 2).

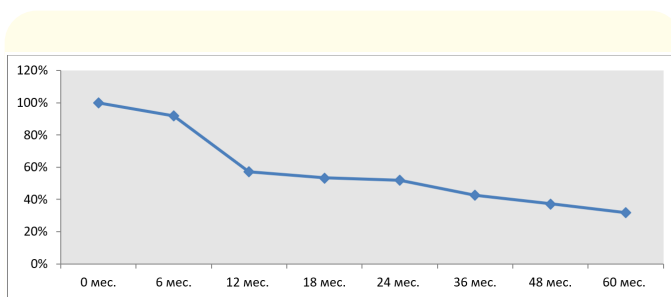


Figure 1: Survival dynamics of patients with GC after neoadjuvant RIAC.

Conclusion

Neoadjuvant RIAC in the treatment of patients with primary non-metastatic types of gastric cancer according to the DPF scheme (Docetaxel 75mg/m² + Cisplatin 75mg/m² + Fluorouracil 1000mg/m² on the 1st day) was effective in 84.5% of patients. At the same time, all patients underwent radical surgical intervention. In 42.6% of patients, there was represented therapeutic pathomorphosis of 3-4 grade. The 3 and 5-year survival rates were 42.7% and 31.8%, respectively. Median survival was 51.8 ± 1.5 months.

Bibliography

1. Kaprin AD. "Malignant neoplasms in Russia in 2016 (morbidity and mortality). Federal Government Budgetary Institution

"National Medical Research Center named after P.A. Herzen of the Ministry of Health of Russia 250 (2018).

2. Kaidarova DR. "Indicators of oncological service of the Republic of Kazakhstan for 2019 (statistical and analytical materials)". Almaty 137 (2020).
3. <https://gco.iarc.fr/today/data/factsheets/cancers/7-Stomach-fact-sheet.pdf>
4. Abdollah MH., et al. "Lack of Any Relationship of Stomach Cancer Incidence and Mortality with Development in Asia". *Asian Pacific Journal of Cancer Prevention* 17.8 (2016): 3775-3781.
5. Smyth EC., et al. "Gastric cancer". *Lancet* 396.10251 (2020): 635-648.
6. Zyryanov BN., et al. "Combined treatment with intra-arterial regional chemotherapy for locally advanced stomach cancer". *Russian Oncological Journal* 1 (1997): 17-20.
7. Barone C., et al. "Long-term follow-up of a pilot phase II study with neoadjuvant epirubicin, etoposide and cisplatin in gastric cancer". *Oncology* 67.1 (2004): 48-53.
8. Wang J., et al. "Combined intra-arterial and intravenous chemotherapy for unresectable, advanced gastric cancer has an improved curative effect compared with intravenous chemotherapy only". *Oncology Letters* 15.4 (2018).
9. Song Z., et al. "Progress in the treatment of advanced gastric cancer". *Tumor Biology* 39.7 (2017): 1010428317714626.
10. Choi AH., et al. "Perioperative chemotherapy for resectable gastric cancer: MAGIC and beyond". *World Journal of Gastroenterology* 21.24 (2015): 7343-7348.
11. Johnston FM and Beckman M. "Updates on Management of Gastric Cancer". *Current Oncology Reports* 21.8 (2019): 67.
12. Ikegame K and Terashima M. "Perioperative Chemotherapy for Gastric Cancer". *Gan To Kagaku Ryoho* 47.4 (2020): 569-573.