



## Some Aspects of Angiogenesis of the Main forms of Gastric Cancer

IS Grekov<sup>1\*</sup> and EA Seleznyov<sup>2</sup>

<sup>1</sup>State Educational Institution, Donetsk National Medical University M. Gorky, Donetsk, Ukraine

<sup>2</sup>State Budgetary Institution Amvrosievsky Central Hospital, Mordovia Republic, Russia

\*Corresponding Author: IS Grekov, State Educational Institution, Donetsk National Medical University M. Gorky, Donetsk, Ukraine.

Received: June 20, 2022

Published: July 29, 2022

© All rights are reserved by IS Grekov and EA Seleznyov.

### Abstract

At present, the study of the characteristics of tumor vessels is of great interest for understanding the patterns of tumor growth, and in practical terms, it makes it possible, taking into account the characteristics of the blood supply, to identify prognosis criteria and choose the optimal type of therapeutic measures, including the suppression of angiogenesis.

Tumor vessels differ from normal vessels in their distribution, structure, and function. Features of the morphology of blood and lymph vessels affect the invasiveness, metastasis of the tumor and the prognosis of the disease. Much attention is now paid to the differences between lymphatic vessels and blood capillaries under light microscopy. There is evidence that high lymphatic density is associated with lymph node metastases and worse patient survival, particularly in gastric cancer. Therefore, scientific developments are aimed at determining specific markers for both the endothelium of the lymphatic and blood vessels, which will further help in the timely diagnosis of the pathological process.

**Keywords:** Epithelial-Mesenchymal Transformation; Angiogenesis; Gastric Cancer; Diagnostics; Immunohistochemistry

### Introduction

Angiogenesis is considered as a process that largely affects the clinical course and prognosis of the disease, which requires the study of factors affecting it and vascular morphology. There is a complex, multi-component, multi-stage system involved in the neogenesis and death of various vascular wall structures, including endothelial cells, basement membrane, pericytes, smooth muscle cells, as well as a variety of factors that affect these structures.

Among the angiogenesis factors that are produced by the tumor, the most specific in relation to endothelial cells is vascular endothelial growth factor (VEGF), for which vascular endothelial cells

have receptors (VEGF R-1 and R-2). Receptors for VEGF are located on endothelial cells, vascular smooth myocytes, monocytes, and macrophages. VEGF increases the permeability of endothelial cells, due to increased transport of metabolites due to increased activity of vesicle-vacuolar organelles, accumulation of vesicles in endothelial cells, it is possible to increase permeability through rearrangement of the cadherin-catenin complex. This leads to extravasation of plasma proteins and the formation of an extracellular matrix (ECM), which is favorable for the migration of endothelial and stromal cells [2]. High expression of VEGF stimulates proliferation and inhibits apoptosis of endothelial cells, with the formation of thin-walled, large "mother" vessels, with their tortuosity, the formation

of “glomeruloid bodies” [3,4]. VEGF-A-164/5 induces fenestration of microvascular endothelium [4,5]. Microvessel density (MVD) in tumor tissue is considered as the best parameter reflecting the level of tumor neovascularization [6,7]. But according to other studies, the expression of VEGF and its specific receptors (VEGF R-1 and R-2) did not correlate with microvascular density [8]. Neuropilin 1, a neuronal VEGF receptor, which is also expressed on endothelial cells, increases the density of blood vessels [9]. Tie-1 and Tie-2 receptors mimicking receptors for vascular endothelial growth factor (VEGF) have been isolated. Tie-2 and Ang-1 do not induce endothelial cell proliferation, but in their absence, vascular remodeling is impaired and periendothelial cells are absent. With Ang-1 over-expression, blood vessels are more numerous, more branched, and have a larger diameter [10]. Platelet growth factor (PDGF), localized in platelets, fibroblasts, endothelial cells, macrophages, plays a role in attracting pericytes to preexisting capillaries and induces the proliferation of pericytes, smooth muscle cells. Transforming growth factor - beta (TGF- $\beta$ ) stimulates apoptosis, inhibits the proliferation of many types of cells, including endothelial cells, and inhibits the migration of endothelial cells. In its absence, ruptures of cell contacts of the vascular wall are pronounced. The CYR-61 gene, which is expressed in fibroblasts, leads to increased migration and adhesion of endothelial cells and stimulation of angiogenesis.

Thus, the formation of the normal tissue vasculature requires the cooperative activity of many different cytokines and inhibitors, each of which is expressed in the appropriate amount and temporal sequence. In contrast, angiogenesis in tumors is defective, imperfect, involves simpler processes, has fewer steps, and involves fewer cytokines [1-3].

The source of many cytokines involved in tumor angiogenesis can be both the parenchyma, i.e., the tumor cells themselves and the stroma, i.e., stromal cells including cells of the educational, immune infiltrate.

Tumor cells express VEGF, the main factor of neoangiogenesis, while this expression is more pronounced in the area of the invasive front, it is associated with the depth of tumor invasion and its metastasis to the lymph nodes. Tumors with a higher degree of malignancy and proliferative activity are characterized by a greater expression of the VEGF protein and show higher proliferation of the endothelium than tumors with a low degree of malignancy of

the parenchyma [7,9,10]. If tumor cells, along with the endothelium, produce angiopoietin-2, then the vessels in the tumor are characterized by a low degree of maturation [3,5,6].

Angiogenesis, in particular the rate of vessel formation, their density, depends on the nature of stromal cells and their interaction with endothelial cells. Stromal cells with a high proportion of myofibroblasts and increased synthesis of extracellular matrix proteins are promoters of angiogenesis [1,2]. Macrophage infiltration of the stroma and expression of IL-8 correlate with VEGF expression and the number of vessels in the tumor.

Expression of certain markers of tumor angiogenesis can serve as tumor prognostic factors and therapy targets. The use of vascular markers as prognostic factors is associated with their influence on the growth and spread of tumors.

VEGF expression positively correlates with microvascular raft density, depth of invasion, and metastasis to the lymph nodes. Although the density of blood vessels in healthy tissue is much higher than in tumor tissue, the diameter of blood vessels in the tumor increases significantly, possibly as a compensation for inadequate angiogenesis. The density of microvessels is the most important prognostic indicator; at low rates, patients had a better prognosis and a low metastatic potential [4,5,7].

Progressive angiogenesis is closely correlated with tumor invasion. Activation of the receptor (R - 2) to VEGF is a criterion for tumor malignancy and is accompanied by invasion [5,8].

High expression of angiopoietin-2 occurs in a more advanced stage of the tumor, the survival time of such patients was significantly shorter than with low expression of angiopoietin-2 [6,8].

Currently, antiangiogenic therapy has become possible in the treatment of tumors, for example, using monoclonal antibodies against VEGF (bevacizumab) [10]. However, after long-term antiangiogenic therapy, VEGF blockade of tumors may resume growth after initial inhibition (Huang). The authors conducted a thorough study of the mechanisms and morphology of vascular remodeling after long-term antiangiogenic therapy. In this case, an increase in vascular integration occurs through the involvement of stromal or so-called mural cells into the vessel wall, i.e., smooth muscle and pericytes. After long-term antiangiogenic therapy, platelet growth

factor and its receptor (PDGF-B and PDGF-Rb) and ephrin-2 are expressed in tumor vessels, which are responsible for the proliferation of mural cells in the vessels of recurrent tumors. Remodeled vessels become more resistant to anti-angiogenic therapy and provide nourishment and growth for preserved tumor tissue.

Given the above, we can confidently speak about the relevance and need for further research into the morphology of blood vessels in tumors, and the use of vascular markers as prognostic factors is a new tool in medical oncology. Immunohistochemical identification of these factors, in order to determine new prognostic criteria, requires further research to standardize the methods that will be used in the clinic. Angiogenesis markers can also become possible therapeutic targets.

### Materials and Methods

In this work, the surgical material of 72 patients of the Donetsk Regional Clinical Territorial Medical Association, who were diagnosed with stomach cancer, was studied. According to Lauren's morphological classification, the cases were divided into three groups: intestinal, diffuse and mixed types. The age of the patients ranged from 42 to 74 years. The material was examined histotopographically. Pieces of tissues were fixed in 10% formalin solution, Carnoy's fluid and subjected to standard histological examination with embedding the material in paraffin and staining the sections with hematoxylin and eosin. A histochemical study of sections made in a cryostat was used to determine the activity of alkaline phosphatase in the vessel walls, which indicates their functional state, participating in the transfer of metabolites through the membranes. In some cases, an immunohistochemical method was used with monoclonal antibodies to macrophages - CD68, vascular endothelium - CD31, to vimentin, desmin, alpha-smooth muscle actin. Immunohistochemical reaction with antibodies to CD31 and vimentin makes it possible to reliably identify the vascular wall in all cases and exclude overdiagnosis of the number of vessels, makes it possible to assess the presence of endothelium in the vessels, its proliferative activity (Ki-67), the usefulness of the structure of the walls, the presence of endothelial and muscle layers. The use of the CD68 monoclonal antibody made it possible to assess the severity of tumor stroma infiltration by macrophages and judge their effect on angiogenesis.

The study revealed the presence of tumor emboli in the lumen of blood and lymphatic vessels, invasion of their walls by tumor

cells. A morphological assessment was carried out with the division of vessels into three types: pre-existing vessels with fully built walls with the presence of pericytes and smooth muscle cells; newly formed tumor vessels of the "maternal" type, thin-walled with wide gaps; vessels of the capillary type, corresponding in structure to normal capillaries.

To study the degree of blood supply to the tumor, the method of counting and quantitative morphometric evaluation of the length of the vascular bed was used, which takes into account the density of the ends of the vessels that fell into the paraffin section.

Using immunohistochemical phenotyping with CD31 monoclonal antibodies and vimentin, a comparison was made of the number of vessels in the center of the tumor and at the border with healthy tissues, taking into account the density and uniformity of their distribution. And, finally, the severity of cellular infiltration in the tumor and outside it was assessed.

### Results and Discussion

In all cases, studies using immunohistochemical methods, except for two, tumor embolism of varying severity was detected, from single complexes in veins and lymphatic capillaries to a massive accumulation of emboli with the presence of tumor cells with signs of apoptosis.

The number of preexisting vessels in the tumor was estimated. It varied widely from 1-2 ends in the low magnification field of view to 12 ends. In one case, angiomatosis was detected (20 ends in the field of view of high magnification). The preexisting vessels were characterized by the presence of thick walls with uniform vimentin staining along the perimeter, often with endothelial proliferation, giving staining with CD 31 (Fig.1, 2). There were arteries with focal thickening of the intima due to fibrosis and a sharp narrowing of the lumen. There were more preexisting vessels on the periphery of the tumor compared to the center.

The number of "mother" vessels identified in gastric cancer was variable: from 3-4 to 78 ends in the high magnification field of view. Cases with a small, moderate and large number of vessels were divided almost equally. Vessels of the described type had a thin wall, sometimes there were gaps lined with endothelium, which stained unevenly with CD 31, or did not stain at all. Vessels of the sinusoidal type prevailed, however, there were also small vessels with practi-

cally no gaps. They also had great differences in shape: rounded, slit-like, angular, ugly, irregular in shape. There were angiomatic structures consisting of small sinusoidal vessels. In part of the vessels, focal endothelial proliferation was found with the expression of Ki-67 in it, and the absence of expression of CD 31. In comparison with the preexisting ones, the number of "maternal" tumor vessels was significantly larger and they differed in morphological features.

There were small vessels of the capillary type, round in shape, with thin walls, completely corresponding to the structure of normal ones, but their number was much smaller than that of the mother ones. This indicates a significant rate of angiogenesis in the tumor tissue, that the rate of formation of new vessels prevails over the rate of their differentiation.

In all the studied cases, the vessels were unevenly distributed: in the center of the tumor, in comparison with the peripheral sections and the border with healthy tissue, the number vessels were smaller.

The degree of cellular infiltration of the tumor was predominantly pronounced: up to 100 cells in the high magnification field of view, on average fluctuated within 45-80 cells. In two cases, cellular infiltration was weak (8-12 cells) and correlated with a small number of vessels (up to a maximum of 15 ends). The severity of cell infiltration was higher along the periphery of the tumor, which indicates its possible role in angiogenesis.

When counting vessels in diffuse, intestinal and mixed types of cancer, in which alkaline phosphatase was detected, as well as staining with vimentin and CD 31, it was noted that the largest number of vessels were stained with vimentin (from 78 to 8 ends in the field of view of high magnification, on average 28- 32), fewer vessels reacted with CD 31 (from 35 to 5 ends, on average 11-15), the smallest number was detected by staining for alkaline phosphatase (maximum 34, minimum 1, on average 3-8 ends). Based on this fact, it can be concluded that there are more morphologically immature vessels in the tumor that do not have or have intermittent expression of the endothelial marker (CD 31) and express only vimentin, fewer vessels with a clear expression of the endothelial marker, and mature vessels with normal functional activity, i.e., with high activity of alkaline phosphatase was very small.

The growth and metastasis of tumors is influenced by multiple signaling pathways associated with the regulation of both parenchyma cells and stromal cells, in particular, vessels. The molecular mechanisms of these processes are reflected in the features of tumor morphology. The neoplasm of thin-walled, wide-lumen vessels in the tumor is due to VEGF expression, while the appearance of platelet-derived growth factor (PDGF) expression ensures the attraction of smooth muscle and pericytes to endothelial cells, which makes the vascular wall more stable and resistant to anti-angiogenic therapy directed against VEGF.

Our study showed the fundamental possibility of a morphological assessment of the ratio of thin-walled vessels in a tumor with smooth muscle cells approaching in structure to normal vessels and functions with alkaline phosphatase activity. As shown in the study by Giatromanolaki A., *et al.* [10], in normal tissues, vessels with alkaline phosphatase activity were similar in distribution density and number to the total number of vessels with an endothelial marker (anti-CD31), while in tumors, the number of vessels with alkaline phosphatase activity was 6-17% from their total number.

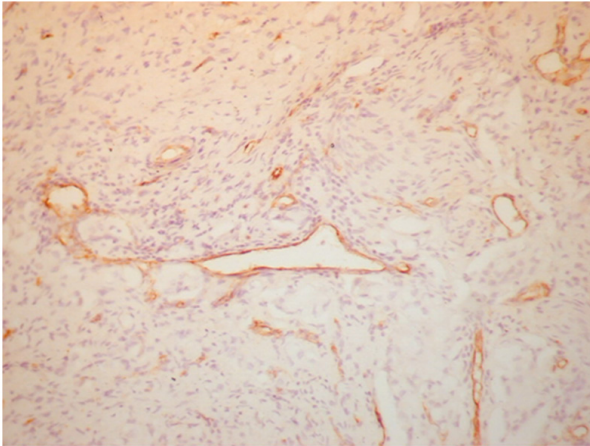
In our study, the number of tumor vessels with alkaline phosphatase activity in the endothelium showed wide fluctuations, dropping to minimal numbers.

Taking into account the participation in the regulation of angiogenesis in tumors of both the parenchyma and their stroma, inhibition of various signaling pathways in them has been proposed, for example, a combination of angiogenesis inhibition with anti-VEGF monoclonal antibodies (bevacizumab) and the use of antibodies against the epidermal growth factor receptor (cetuximab), which inhibits growth tumor parenchyma [7,10].

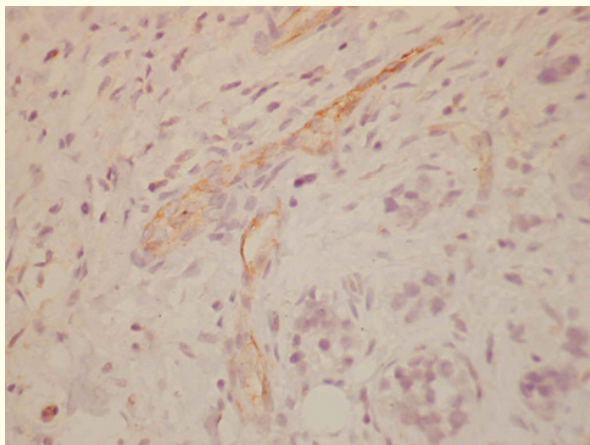
Studies aimed at revealing the mechanism of resistance to anti-angiogenic therapy have established the role of vascular remodeling in tumors due to the expression of platelet growth factor, its receptor, and ahrin B2 through the integration of endothelium with mesenchymal cells.

Morphological research methods, in particular immunohistochemical methods, make it possible to estimate the proportion of such vessels in tumors.

Molecules that are inhibitors of angiogenic receptors for platelet growth factor tyrosine kinase and others involved in vascular remodeling were tested in the experiment. Therefore, the features of the morphology of vessels in the tumor will be able to predict the possible effectiveness of therapy aimed at inhibiting various signaling pathways of tumor angiogenesis.



**Figure 1:** Pronounced expression of marker CD 31 in the endothelium of tumor vessels, x 200.



**Figure 2:** Slight expression of marker CD 31 in the endothelium of tumor vessels.

## Conclusion

- The severity of vascularization differs in different areas of the tumor: the number of vessels along the periphery was significantly greater than in the center of the tumor.
- In the tumor, there were significantly fewer pre-existing vessels with thick walls, uniform expression of vimentin and CD 31, as well as capillary-type vessels that completely corresponded to normal capillaries in structure than the so-called “mother” tumor vessels, which had signs of morphological atypism and various defects. expression of endothelial and connective tissue markers.
- A clear atypism in the morphology of the tumor vessels was revealed: shape atypism (round, slit-like, angular, ugly, irregular in shape), size atypism (from small, practically without a lumen, to sinusoid-type vessels), as well as the presence of proliferating endothelial cells.
- Tumor vessels had features identified by immunohistochemistry. Immature vessels predominated, expressing only vimentin in the walls, or with no or uneven expression of CD 31, in the presence of an endothelial layer, detected by staining with hematoxylin and eosin. Compared to the previous ones, there were a small number of vessels in the tumor that evenly expressed CD 31, and even fewer vessels had alkaline phosphatase activity, i.e., showed functional activity.

## Bibliography

1. Vasilenko IV., *et al.* “Epithelial-mesenchymal transition in main types of gastric carcinoma”. *American Journal of Translational Research* 10 (2 (2021): 13-20.
2. Nakamura Y., *et al.* “Importance of lymph vessel in gastric cancer: a prognostic indicator in general and a predictor for lymph node metastasis in early-stage cancer”. *Journal of Clinical Pathology* 59 (2006): 77-82.
3. Dimmeler S and Zeiher A. “Phosphorylation of the endothelial nitric oxide synthase at Ser-1177 is required for VEGF-induced endothelial cell migration”. *FEBS Letters* 477 (2000): 23-62.
4. McDonald D and Beluk P. “Significance of blood vessel leakage in cancer”. *Cancer Research* 62.15 (2002): 5381-5385.

5. Dvorak HF. "How tumors make bad blood vessels and stroma". *The American Journal of Pathology* 162.6 (2003): 1747-1757.
6. Roberts WG., *et al.* "Host microvasculature influence on tumor vascular morphology and endothelial gene expression". *The American Journal of Pathology* 153 (1998): 1239-1248.
7. Ye-Jiang Zhou., *et al.* "Inactivation of PTEN is associated with increased angiogenesis and VEGF overexpression in gastric cancer". *World Journal of Gastroenterology* 10.21 (2004): 3225-3229.
8. Lucchi J., *et al.* *European Journal of Cardio-Thoracic Surgery* 12.7 (1997): 535- 541.
9. Miao HQ., *et al.* "Neuropilin-1 expression by tumor cells promotes tumor angiogenesis and progression". *The EMBO Journal* 14 (2000): 2532-2539.
10. Yancopoulos G., *et al.* "Vascular-specific growth factors and blood vessel formation". *Nature* 407 (2000): 242-248.

#### Assets from publication with us

- Prompt Acknowledgement after receiving the article
- Thorough Double blinded peer review
- Rapid Publication
- Issue of Publication Certificate
- High visibility of your Published work

**Website:** [www.actascientific.com/](http://www.actascientific.com/)

**Submit Article:** [www.actascientific.com/submission.php](http://www.actascientific.com/submission.php)

**Email us:** [editor@actascientific.com](mailto:editor@actascientific.com)

**Contact us:** +91 9182824667