

Colonoscopic-Assisted Resection of a Giant Prolapsed Sigmoid Colon Lipoma

Okoli, Fidelis, M.D.¹; Golfeyz, Shmuel, M.D.²; Albert, Joel, M.D.²; Mayer, Ira, M.D., FACP, FACC, AGAF, NYSGEF.²

¹Division of Gastroenterology, Hepatology and Nutrition, Department of Internal Medicine, New York University Langone Hospital, Long Island, New York

²Division of Gastroenterology and Hepatology, Maimonides Medical Center, Brooklyn, New York

***Corresponding Author:** Okoli Fidelis, Division of Gastroenterology, Hepatology and Nutrition, Department of Internal Medicine, New York University Langone Hospital, Long Island, New York.

Received: January 12, 2022

Published: February 22, 2022

© All rights are reserved by Okoli, Fidelis, M.D., et al.

Abstract

Although colorectal lipomas are the second most common benign tumors in the colon, they are uncommonly seen in clinical practice. Lipomas are typically asymptomatic and incidentally found during colonoscopy or on radiological imaging. Symptomatic lipomas are usually larger than two centimeters and can present with abdominal pain, change in bowel habits, obstruction, bleeding, intussusception, or perforation. Different imaging modalities can be used to diagnose lipomas however definitive diagnosis is made histologically. Symptomatic lipomas require either endoscopic or surgical resection. We report a case of a colonoscopy-assisted resection of a large sigmoid colonic lipoma that prolapsed through the anal canal.

Keywords: Colorectal Lipomas; Colonoscopy Assisted Resection; Rectal Prolapse; Gastrointestinal Lipomas; Abdominal Pain

Introduction

Lipomas are benign intramucosal tumors which lack malignant potential. Gastrointestinal (GI) lipomas were first described by Bauer in 1757 and can occur anywhere from the hypopharynx to the rectum [1]. Approximately 65 - 75% are found in the colon, and 20 - 25% are in the small intestine [2]. Lipomas constitute about 5% of all GI tumors with incidence ranging from 0.035% to 4.4% [1,3]. The most frequent to least frequent site of colorectal lipomas is the ascending colon and rectum respectively 1. Over 90% of colonic lipomas are asymptomatic and incidentally detected during colonoscopy, imaging studies, surgery, or autopsy [4,5]. Large lipomas (i.e., > 2cm) are usually symptomatic and can cause complications such as obstruction, bleeding, intussusception, infarction, or perforation [1,6,7]. We report a case of a sigmoid lipoma prolapsing through the rectum, which was resected with the assistance of colonoscopy to help guide placement of endoloops.

Case Report

An 81-year-old man with history of coronary artery disease on Plavix presented with a large mass protruding from his anus. The patient was straining during defecation and felt severe abdominal and rectal pain. Vital signs and labs were normal. Physical examination revealed left lower quadrant tenderness, and a large mass protruding through his anus. Computed tomography (CT) scan of the abdomen and pelvis revealed a prolapsed 7 x 5cm sigmoid lipoma with coloanal intussusception, without evidence of obstruction, perforation, or peritonitis (Figure 1). Attempts to reduce the lipoma manually at bedside were unsuccessful, therefore the patient was taken for emergent resection. The gastrointestinal team was asked to assist so that direct visualization could be used to resect the lipoma stalk. A pediatric colonoscope was inserted alongside the

lipoma into the rectum revealing a large stalk of prolapsed colon extending to 20cm from the anal verge (Figure 2). The retroflexion view showed the stalk traversing the anus surrounded by large hemorrhoids (Figure 3). The colonoscope could not be advanced past the stalk due to intussusception from the lipoma stalk pulling the colon forwards. Endoloops and a LigaSure device were used to transect the lipoma since the patient was on Plavix and had a high bleeding risk. Using the colonoscope for constant visualization, two Endoloops were placed manually to 10cm from the anal verge using caution to avoid anchoring onto the colonic wall. A third Endoloop was placed at the junction of the lipoma and its stalk at the anal verge. The colonoscope was removed and an Impact LigaSure device was used to slowly transect across the apex of the lesion right at the anal verge with manual pressure to retract the skin, perianal region, rectal mucosa, and hemorrhoids from the LigaSure device (Figure 4). The colonoscope was then reinserted and the colon was easily traversed up to 40 cm from the anal verge. The stalk was noted to have the two Endoloops in place without bleeding. Pathology revealed a submucosal lipoma with acute inflammation and partial fat necrosis as well as overlying colonic mucosa with ulceration (Figure 5).

Discussion

Colonic lipomas typically affect people between 50 - 65 years of age and have a female predominance of 2:1 [4]. Lipomas arise from the connective tissues of the intestinal wall and about 90% are submucosal. Lipomas can also be subserosal, intramuscular, or mixed [7]. The exact etiology is unclear, but it is generally accepted that chronic inflammation, abnormal motility, and excessive adipose tissue deposition all play a role in lipoma formation [7,8]. Sizes range from a few millimeters to many centimeters [1,9]. Li-

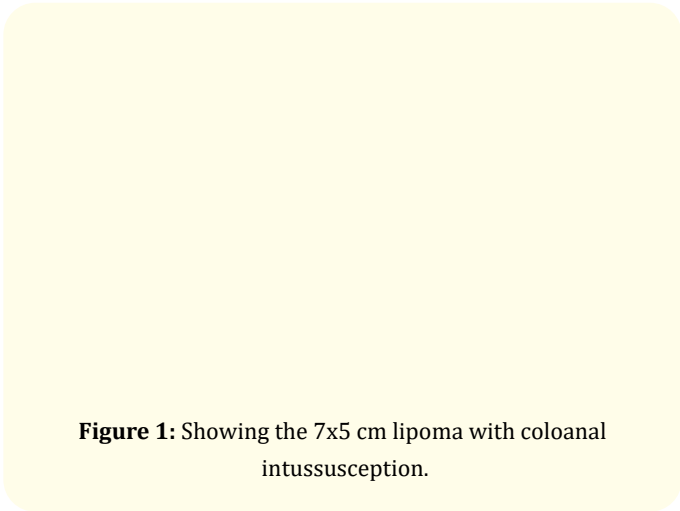


Figure 1: Showing the 7x5 cm lipoma with coloanal intussusception.

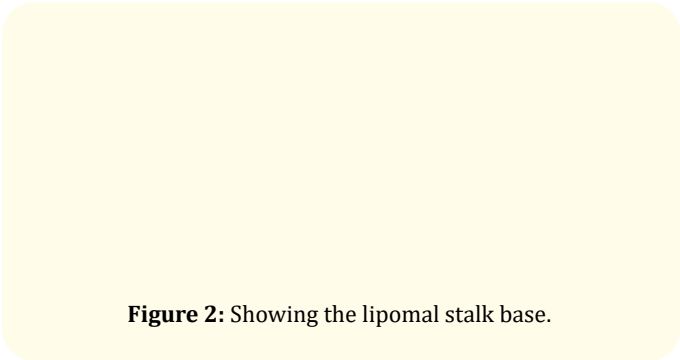


Figure 2: Showing the lipomal stalk base.

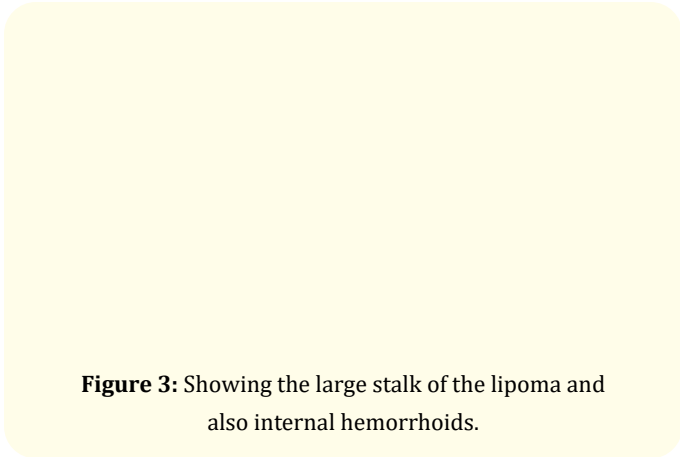


Figure 3: Showing the large stalk of the lipoma and also internal hemorrhoids.




Figure 4: Showing the resected lipoma.

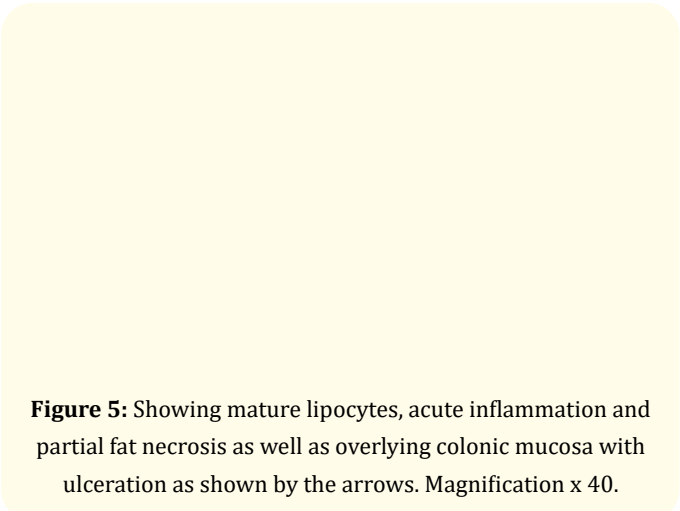


Figure 5: Showing mature lipocytes, acute inflammation and partial fat necrosis as well as overlying colonic mucosa with ulceration as shown by the arrows. Magnification x 40.

pomas are mostly found in the ascending colon (61%), followed by descending colon (20.1%), transverse colon (15.4%), and rectum (3.4%) [4,10].

Symptomatic lipomas can present with rectal bleeding (54.5%), abdominal pain (42.4%) and change in bowel habits (24.2%) [4,10]. Lipomas can also present with constipation, anemia, intussusception, obstruction or perforation [1,6,7,11-13]. Spontaneous expulsion of lipomas has been documented in the literature [11,14]. This is thought to be due to self-amputation of the lipoma at the stalk and typically seen with giant pedunculated lipomas [15,16].

Diagnosis can be made with colonoscopy, barium radiographs, endoscopic ultrasound (EUS), confocal laser microscopy (CLE), or CT scan. Colonic lipomas appear as yellowish smooth submucosal lesions on colonoscopy. Characteristic features include, “cushion or pillow sign” which is a flattening/indentation of the tissue when pushing the biopsy forceps against the lipoma and restoration of its regular shape once the forceps are removed; “naked fat sign” which is when fatty tissues extrudes through the biopsy site; and “tent-sign” which is when the mucosa is grasped with forceps and pulled upwards creating a tent shape [7]. Limitations of colonoscopy include reduced sensitivity for diagnosing atypical lipomas with necrosis or ulceration [7]. Additionally, biopsies obtained during colonoscopy may fail to obtain adequate adipose tissue needed to make the diagnosis [4]. CT scan is currently the imaging study of choice. Lipomas appear as well defined, ovoid, intramural lesions with a greasy density. CT is specifically useful when lipomas are > 2cm and in those with associated complications such as intussusception, necrosis or infarction [4,6,7,10,17]. Barium radiography is sensitive but not specific, and EUS is useful for diagnosing atypical appearing lipomas [7,10,17].

The gold standard for diagnosis is histopathology. Microscopically, lipomas appear as adipose tissue covered by a fibrous capsule, and the overlying mucosa may have ulceration, granulation, or fat necrosis [4,6,7]. In our case, the diagnosis was made with CT scan and confirmed by histology.

Asymptomatic colonic lipomas can be observed whereas symptomatic ones require treatment. Lipomas can be managed with ei-

ther endoscopic or surgical resection. Treatment options depend on size, location, and the presence or absence of complications. Endoscopic excision with snare electrocautery is considered the gold standard for lipomas < 2cm while segmental colectomy with lipectomy is considered the gold standard for uncomplicated lipomas > 2cm [4,5,7,17].

In general, surgical intervention is the more effective treatment option for large colonic lipomas and once removed, they generally do not recur. Endoscopic assistance may be helpful, as in our case, to allow safe resection of the tumor, while minimizing the effects of full surgical resection in patients who may not tolerate such procedures.

Disclosures
Conflict of Interest

The authors have no conflict of interest to report.

Declaration of Funding Source

There is no external funding for this article.

Human/Animal Rights

All procedures followed were in accordance with the ethical standards as contained in the Helsinki Declaration of 1975, as revised in 2008 (5).

Informed Consent

Informed consent was obtained from the patient in the case report.

Bibliography

1. Kouritas VK., et al. "Spontaneous expulsion from rectum: a rare presentation of intestinal lipomas". *World Journal of Emergency Surgery : WJES* 6 (2011): 19.

2. Aminian A., et al. "Ileal intussusception secondary to both lipoma and angiolipoma: a case report". *Cases Journal* 2 (2009): 7099.

3. Chehade HH., et al. "Large ileocecal submucosal lipoma presenting as hematochezia, a case report and review of literature". *International Journal of Surgery Case Reports* 10 (2015): 1-4.

4. Jiang L., et al. "Giant submucosal lipoma located in the descending colon: a case report and review of the literature". *World Journal of Gastroenterology* 13.42 (2007): 5664-5667.

5. Ghidirim G., et al. "Giant submucosal lipoma of the cecum: report of a case and review of literature". *Romanian Journal of Gastroenterology* 14.4 (2005): 393-396.

6. Mouaqit O., et al. "Pedunculated lipoma causing colo-colonic intussusception: a rare case report". *BMC Surgery* 13 (2013): 51.

7. Andrei LS., et al. "Rare cause of intestinal obstruction - submucous lipoma of the sigmoid colon". *Chirurgia (Bucharest, Romania : 1990)* 109.1 (2014): 142-147.

8. Biswas S., et al. "Large Cecal Lipoma With Overlying Ulceration Simulating Malignancy: A Case Report and Review of Relevant Literature". *Journal of Current Surgery* (2013).

9. Michowitz M., et al. "Lipoma of the colon. A report of 22 cases". *The American Surgeon* 51.8 (1985): 449-454.

10. Kose E., et al. "Giant colonic lipoma with prolapse through the rectum treated by external local excision: A case report". *Oncology Letters* 8.3 (2014): 1377-1379.

11. Kang B., et al. "Resolution of intussusception after spontaneous expulsion of an ileal lipoma per rectum: a case report and literature review". *World Journal of Surgical Oncology* 12 (2014): 143.

12. Cirino E., et al. "[Intestinal invagination caused by colonic lipoma]". *Minerva Chirurgica* 51.9 (1996): 717-723.

13. Annibale B., et al. "Gastrointestinal causes of refractory iron deficiency anemia in patients without gastrointestinal symptoms". *The American Journal of Medicine* 111.6 (2001): 439-445.

14. Zamboni WA., et al. "Spontaneous expulsion of lipoma per rectum occurring with colonic intussusception". *Surgery* 101.1 (1987): 104-107.

15. Gupta AK and Mujoo V. "Spontaneous autoamputation and expulsion of intestinal lipoma". *The Journal of the Association of Physicians of India* 51 (2003): 833.

16. Radhi JM. "Lipoma of the colon: self amputation". *The American Journal of Gastroenterology* 88.11 (1993): 1981-1982.

17. Nebbia JF., et al. "Lipomas of the right colon: report on six cases". *Clinical Imaging* 31.6 (2007): 390-393.

Assets from publication with us

- Prompt Acknowledgement after receiving the article
- Thorough Double blinded peer review
- Rapid Publication
- Issue of Publication Certificate
- High visibility of your Published work

Website: www.actascientific.com/
Submit Article: www.actascientific.com/submission.php
Email us: editor@actascientific.com
Contact us: +91 9182824667