



Morphological Features of Liver Reactivity After Intranatal Antigen Influence

Hryhorieva OA¹, Pivtorak VI^{2*}, Bohdanov PV¹, Matvieishyna TM¹,
Guminskiy YY², Chugin SV¹ and Zynych OL¹

¹Zaporizhzhia State Medical University, Zaporizhzhia, Ukraine

²National Pirogov Memorial Medical University, Vinnitsa, Ukraine

***Corresponding Author:** Pivtorak VI, National Pirogov Memorial Medical
University, Vinnitsa, Ukraine.

Received: October 06, 2021

Published: October 29 2021

© All rights are reserved by **Pivtorak VI,
et al.**

Abstract

Morphological peculiarities of liver after antigen influence on the mother-placenta-fetus system is not well studied.

Materials and methods: The study included the livers of 144 white laboratory rats from 1 to 90 days of life. All animals were conditionally divided into 3 groups: Group I - intact animals, which were born from healthy rats without any antigen administration during pregnancy; group II - control animals, which were exposed to antenatal intrafetal administration of 0.05 ml saline solution on the 18th day of prenatal development; group III - experimental animals, which were exposed to antenatal antigen administration at 18th day of prenatal development. The absolute and relative mass of the liver was calculated. For light microscopy, sections were stained with hematoxylin and eosin. Detection of β -D-galactose carbohydrate residues was performed using a Lectin from *Ricinus communis* Agglutinin (RCA) by standard methods, using standard set of reagents "LectinTest" (Lviv). Quantitative and qualitative morphological characteristics of the liver were studied. Analysis of the obtained results was conducted by means of statistical methods with the use of computer license program "Statistica for Windows 13" (StatSoft Inc., № JPZ804I382130ARCN10-J).

Results: In experimental animals after antenatal administration of staphylococcal toxoid, the relative area occupied by hepatic plates (as in the control) tends to increase gradually during the first two weeks of life. In animals, which were exposed to antenatal Staphylococcal purified liquid toxoid administration, the number of lymphocytes in the central zone of the liver lobule is lower than in the intact and control groups on the first day is 1.04 ± 0.35 cells on unit area. (2.26 ± 0.52 cells on unit area in control). The maximum decrease in the number of lymphocytes in the central zone in experimental rats in contrast to the control occurs on the 30th day of life together with a simultaneous decrease in the number of Kupffer macrophages and is 0.70 ± 0.35 cells on unit area - in the experiment (2.61 ± 0.69 cells on unit area in the control group). A decrease in the number of lymphocytes is observed also in the peripheral zone of the lobule compared with the control from the third to the 30th day of life, but such changes have no statistical significance. It was found that RCA+ receptors are expressed on dendritic cells in the liver; the number of RCA+ dendritic cells changes in waves during the first three months after birth.

Conclusions: The relative mass of the liver in experimental group rats significantly exceeds the control at the seventh day of life ($3.06 \pm 0.05\%$ in the experimental and $2.91 \pm 0.02\%$ in the control group). In experimental rats the number of dendritic cells decreases during the first two weeks of life, the minimum number is observed on the 3rd day. In the peripheral zone of the lobule, a decrease in the number of dendritic cells is observed on the 1st and the 21st day of postnatal life in comparison with control.

Keywords: Liver; Intranatal Antigen Influence; Dendritic Cells

Introduction

One of the relevant and very important issues in the field of the Maternity and Child Welfare Services is the impact on the body of a pregnant woman of various nature factors, which can not only accompany but also complicate the course of a normal pregnancy. Such factors include not only environmental and social factors, but the influence of various infectious pathogen [13]. Basically most infectious agents or products of their activity are able to penetrate the blood-placental barrier or enter the fetus by ascending.

Among the causes of diseases of the digestive system in young children are congenital pathologies that can be formed during fetal development. It is generally accepted that a child's health is formed before birth, during birth and throughout the first years of life, and then only maintained and strengthened. Therefore, the study of the consequences of factors that may affect the formation of organs and systems is quite relevant. Thus, the problem of preserving and strengthening the health of children is very important and should be strategic because healthy children today are the future of social and economic development of any country tomorrow [13].

It is well known that physiological pregnancy occurs under conditions of suppression of the immune response, therefore, violations of the hemoplacental barrier can promote the penetration of antigens of various natures into the fetus. Earlier it was given a morphological characteristics of knee joint, heart, pancreas, gastro-intestinal tract reactive changes after intranatal antigen action [2,4-6,12].

Depending on the gestational age, the antigenic load on the fetus can affect the rate of normal morphogenesis of organs and tissues, in particular connective tissue, and lead to development of undifferentiated connective tissue dysplasia [4,7,11,12]. In recent years, most experimental studies have focused on the development of liver [8], the description of pathological changes in the body, the study of hepatocytes and nonparenchymal cells that are part of the liver at the ultramicroscopic level [1], but morphological changes occurring in fetal liver after changes in the mother-placenta-fetus system, insufficiently studied.

The Aim

To study morphological features of liver reactivity after intranatal antigen influence.

Materials and Methods

The study included the livers of 144 white laboratory rats from 1 to 90 days of life. The animals were obtained from the vivarium of

PE "Biomodelservice" Kyiv, veterinary certificates KI - 33 №042560 dated 17.09.2014, KI - 33 №049566 dated 23.05.2016, KI - 33 №054439 dated 15.09.2016. Rats were kept in vivarium. Animals were contained in standard conditions of vivarium in acrylic cages with a volume of 300 cm³ for 4-5 animals each and free access to water according to "European Convention for the protection of vertebrate animals used for experimental and other scientific purposes" (Strasbourg, 18.03.86 G.) and the Law of Ukraine № 1759-VI (15.12.2009).

All animals were conditionally divided into 3 groups: Group I - 48 intact animals, which were born from healthy rats without any antigen administration during pregnancy; Group II - 48 control animals, which were exposed to antenatal intrafetal administration of 0.05 ml saline solution on the 18th day of prenatal development (Figure 1). Group III - 48 experimental animals, which were exposed to antenatal antigen administration at 18th day of prenatal development by analogy with the control group (Figure 1). Staphylococcal purified liquid toxoid (10-14 units in 1 mL, diluted 10 times) in volume of 0.05 mL was chosen as the antigen. The dose of toxoid was determined by using the formula for recalculating the therapeutic dose for human per rat. Optimal dose of the toxoid was experimentally derived with consideration to the weight of the animal. So toxoid administration did not lead to the death of the animal during the experiment. The principle of choosing staphylococcal toxoid (ST) as an antigen is due to two main criteria: the tropism of this pathogen to liver tissues and the prevalence of staphylococcal carriers among pregnant women.

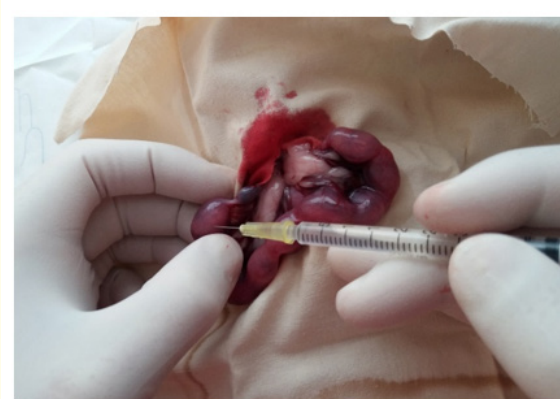

Figure 1: The method of antenatal antigen administration.

In the postoperative period, the animals were kept in separate cages before parturition and for up to 30 days after it, after which

the female was separated from the offspring. The analysis of liver structure was conducted at 1-st, 3-rd, 7-th, 14-th, 21-st, 30-th, 60-th and 90-th day after birth (6 rats of each group per each term).

Animals were weighed on pharmacy scales. Removed livers up to 1 gram were weighted using Torsion Scales, and exceeded 1 gram were weighted using Pharmacy Scales. The absolute and relative mass of the organ was calculated. Samples of the liver up to 2 mm thick were fixed in 10% neutral formalin solution for 48 to 72 hours. Histological specimens were made using standard methods. For light microscopy, sections were stained with hematoxylin and eosin. Detection of β -D-galactose carbohydrate residues was performed using a Lectin from *Ricinus communis* Agglutinin (RCA) by standard methods, using standard set of reagents "LectinTest" (Lviv).

According to the modern international histological terminology, the classical lobule (polygonal lobules of the liver) consist of hepatocytes that form hepatic plates. There are three zones in each classical lobule: central, intermediate and peripheral. Sinusoids are located between the liver transplants. In the center of each classical lobule is the central vein. At the periphery of the lobules are the interlobular artery, interlobular vein and interlobular bile duct, which altogether form portal triads. Between sinusoidal endothelial cells and hepatocytes is located perisinusoidal space. Non-parenchymal elements of the liver includes perisinusoidal cells (fat storing cells), hepatic Pit cells (hepatic natural killer cells), stellate macrophages.

Quantitative and qualitative morphological characteristics of the liver were studied making analysis of cell composition and content of extracellular matrix substances in central and peripheral areas of the classical lobule, according to the International Anatomical Nomenclature (2005).

The relative area of the liver structures was calculated on a unit area of $10,000 \mu\text{m}^2$. The relative area occupied by liver structures: hepatic plates, sinusoidal capillaries, central veins, interparticle veins, arteries and bile ducts, connective tissue and foci of hematopoiesis was researched using. The liver cell composition was calculated into two areas of the liver zones: central and peripheral. The number of mononuclear and multinucleated hepatocytes, the number of hepatocytes with signs of mitosis, endothelial cells of sinusoidal capillaries, Kupffer cells, lymphocytes, hematopoietic cells were calculated with oil immersion technique.

Analysis of the obtained results was conducted by means of statistical methods with the use of computer license program "Statistica for Windows 13" (StatSoft Inc., № JPZ804I382130ARCN10-J). The significance of the differences between the experimental groups was assessed using the Student's criterion t , considering the differences to be reliable at $p < 0.05$, that is generally accepted for biological and medical researches. The numerical data of the obtained results are presented as $M \pm m$ (arithmetic mean \pm standard error of the mean).

Ethical Approval

Supporting and withdrawal of animals from experiment was carried out in accordance with the requirements of the European Commission Directive (86/609/EEC), Law of Ukraine № 1759-VI (15.12.2009) On the Protection of Animals from Cruelty.

Results and Discussion

Analysis of the obtained data showed that the absolute mass of the liver of intact and control groups on average is 213.67 ± 12.52 mg. A more integrative indicator that reflects the parameters of organ development is the relative mass index, which at birth in the control group on average is $4.43 \pm 0.09\%$. The dynamics of the absolute mass of the liver in the intact and control groups has a gradual tendency to increase from the first to the ninety day of life. Indicators of growth rates of absolute mass of a liver have wavy character with peaks of growth on the 21st day in 2.08 times in comparison with the 14th day of life, on the 30th day in 3,16 times in comparison with 21st day. The dynamics of the relative mass of the liver in the intact and control groups of animals also has a wavy character, gradually decreasing by the end of the first week and gradually increasing from the 21st to the 60th day of life. The dynamics of absolute weight gain and relative liver mass in control and intact animals are probably related to critical stages of animal development, namely hemocirculatory changes in the liver after birth and changes in animal diet - the transition to a mixed diet (14-21 day of life) and complete transition to solid food (on the 30th day).

In the group of experimental animals, which were exposed to antenatal Staphylococcal purified liquid toxoid administration at 18th day of prenatal development at the first day of observation, the absolute mass of the liver is probably no different from the control and states at 205.67 ± 7.43 mg. The dynamics of the absolute mass of the liver tends to increase gradually to 90 day of life with a peak of growth on the 14th day (493.5 ± 30.96 mg). The dynamics of the

Day of life	Absolute liver mass (mg)		
	1	2	3
1	212 ± 9,88	213,67 ± 12,52	205,67 ± 7,43
3	237,17 ± 16,59	235,17 ± 6,08	246,83 ± 10,25
7	285 ± 21,24	318,17 ± 24,64	354,83 ± 14,45
14	350,83 ± 40,74	373,67 ± 32,77	493,5 ± 30,96*
21	826,67 ± 38,62	776,67 ± 24,59	900,67 ± 153,12
30	2598 ± 191,57	2455,67 ± 170,22	2513,33 ± 123,87
60	2800 ± 234,88	3035 ± 88,08	3214,17 ± 60,2
90	3788,33 ± 255,28	3716,67 ± 264,79	3741,67 ± 35,16

Table 1: Absolute liver mass (mg) of intact and experimental groups.

Notes: 1 - Intact Group; 2 - control Group; 3 - The Experimental Group (animals, which were exposed to antenatal Staphylococcal purified liquid toxoid administration at 18th day of prenatal development); * indicator shows statistically significance in comparison with the control group $p < 0,05$.

Day of life	Relative liver mass (%)		
	1	2	3
1	4,36 ± 0,10	4,43 ± 0,09	4,23 ± 0,13
3	4,96 ± 0,16	4,83 ± 0,04	4,47 ± 0,04
7	2,79 ± 0,13	2,91 ± 0,02	3,06 ± 0,05*
14	2,72 ± 0,06	2,76 ± 0,53	2,74 ± 0,10
21	3,68 ± 0,11	3,45 ± 0,11	3,74 ± 0,13
30	5,34 ± 0,23	5,1 ± 0,26	5,31 ± 0,22
60	5,35 ± 0,37	5,23 ± 0,21	4,56 ± 0,04*
90	4,53 ± 0,09	4,41 ± 0,12	4,58 ± 0,17

Table 2: Relative liver mass (%) of intact and experimental groups.

Notes: 1 - Intact Group; 2 - Control Group; 3 - The Experimental Group (animals, which were exposed to antenatal Staphylococcal purified liquid toxoid administration at 18th day of prenatal development); * indicator shows statistically significance in comparison with the control group $p < 0,05$.

increase in the absolute mass of the liver as well as in the control has a wavy character with an increase from the 21st to the 30th day.

It should be noted that the rate of increase in the absolute mass of the liver during the first two weeks exceeds the intact and control groups almost twice with subsequent attenuation by the 30th day. The dynamics of the relative mass of the liver waving; draws attention to the increase in the relative mass of the liver on the 7th day compared with the control group ($3.06 \pm 0.05\%$ - in the experimental group and $2.91 \pm 0.02\%$ - in the control group). At the 60th day there is a decrease in the relative mass of the liver in experimental animals ($4.56 \pm 0.04\%$) compared with the control group ($5.23 \pm 0.21\%$). The obtained results coincide with the results of research of internal organs of newborns after antenatal administration of gamma globulin manifest in the symptom complex of visceromegaly and syndrome of undifferentiated dysplasia of connective tissue on antenatal antigen administration [4,6,7,10-12].

The largest part of the parenchymal elements of the liver is taken by hepatocytes, which by contacting with each other form liver plates. In newborns, the relative area occupied by liver plates in the intact and control groups averages $56.0 \pm 2.34\%$. Gradually, with the development of the body and the final formation of liver lobes, this index increases. Thus, from the first to the 14th day of life, the relative area occupied by hepatic plates increases by 25.03% (from $56.0 \pm 2.34\%$ to $81.03 \pm 1.99\%$).

Subsequently, there is a slight decrease (by 5.44%) in the relative area occupied by hepatic plates changes from $80.25 \pm 1.99\%$ on the 21st day of life to $74.81 \pm 1.87\%$ on 90 day of life.

The dynamics of the absolute number of hepatocytes in the central zone of the classical lobule of intact and control rats is wavy in nature with a gradual increase in the number of mononuclear hepatocytes from birth to 21 days of life from 51.83 ± 1.22 cells on unit area up to 62.09 ± 1.57 cells on unit area. Under the subsequent supervision is noted gradual decrease in absolute number of mononuclear hepatocytes during the next two months of supervision. The dynamics of the number of multinucleated hepatocytes has the character of a gradual increase from 2.26 ± 0.52 cells on unit area on the 1st day to 7.65 ± 1.22 cells on unit area on the 90th day of life. The dynamics of the cells with signs of mitosis number in the central zone of the classical lobule is regressive during the 1st to 90th day of observation (1.91 ± 0.52 cells on unit area on the 1st day and 0.87 ± 0.35 cells on unit area on the 90th day of life). Similar dynamics of the number of mononuclear and multinucleated hepatocytes is observed in the peripheral zone of the liver lobes.

The relative area occupied by sinusoids on the first day of life in the control group is $16.67 \pm 1.76\%$ and tends to decrease gradu-

Group of animals		Day of life			
		1	3	7	14
Intact group	HP	58,13 ± 2,25	56,22 ± 2,34	76,39 ± 2,24	81,94 ± 2,03
	S	14,17 ± 1,59	14,89 ± 1,68	9,17 ± 1,52	8,61 ± 1,48
	CV	3,33 ± 0,82	2,89 ± 0,79	2,22 ± 0,78	2,50 ± 0,82
	IBD	1,25 ± 0,51	1,78 ± 0,62	1,94 ± 0,73	1,67 ± 0,67
	IA	1,25 ± 0,51	1,56 ± 0,58	1,39 ± 0,62	1,39 ± 0,62
	IV	3,13 ± 0,79	2,67 ± 0,76	1,94 ± 0,73	1,94 ± 0,73
	CT	1,04 ± 0,46	1,11 ± 0,49	1,11 ± 0,55	1,11 ± 0,55
	FH	17,71 ± 1,74	18,89 ± 1,85	5,83 ± 1,24	0,83 ± 0,48
Control group	HP	56,0 ± 2,34	58,15 ± 3,0	77,22 ± 2,21	81,03 ± 1,99
	S	16,67 ± 1,76	14,07 ± 2,12	8,33 ± 1,46	9,23 ± 1,47
	CV	3,11 ± 0,82	2,96 ± 1,03	2,50 ± 0,82	2,31 ± 0,76
	IBD	1,33 ± 0,54	1,85 ± 0,82	2,22 ± 0,78	1,79 ± 0,67
	IA	1,11 ± 0,49	1,48 ± 0,74	1,39 ± 0,62	1,28 ± 0,57
	IV	3,33 ± 0,85	2,96 ± 1,03	2,22 ± 0,78	2,05 ± 0,72
	CT	1,11 ± 0,49	1,48 ± 0,74	1,11 ± 0,55	1,28 ± 0,57
	FH	17,33 ± 1,78	17,04 ± 2,29	5,0 ± 1,15	1,03 ± 0,51
Animals, which were exposed to antenatal Staphylococcal purified liquid toxoid administration	HP	58,33 ± 2,41	66,67 ± 2,48*	79,78 ± 1,89	80,00 ± 2,11
	S	19,52 ± 1,93	10,83 ± 1,64	7,33 ± 1,23	9,72 ± 1,56
	CV	3,33 ± 0,88	3,33 ± 0,95	2,00 ± 0,66	2,22 ± 0,78
	IBD	1,19 ± 0,53	1,94 ± 0,73	3,33 ± 0,85	1,94 ± 0,73
	IA	1,19 ± 0,53	1,39 ± 0,62	1,78 ± 0,62	1,39 ± 0,62
	IV	2,86 ± 0,81	3,06 ± 0,91	2,00 ± 0,66	2,22 ± 0,78
	CT	1,19 ± 0,53	1,39 ± 0,62	1,11 ± 0,49	2,50 ± 0,82
	FH	12,38 ± 1,61*	11,39 ± 1,67*	2,67 ± 0,76	-

Table 3: Dynamics of the relative area quantity ($M \pm m$, %) of the hepatic plates, blood vessels, connective tissue and hematopoietic foci in the liver from the first to the fourteenth day of life.

Notes: HP - Hepatic Plate; S - Sinusoid; CV - Central Vein; IBD - Interlobular Bile Duct; IA - Interlobular Artery; IV - Interlobular Vein; CT - Connective Tissue; FH - Foci of Hematopoiesis; * indicator shows statistically significance in comparison with the control group $p < 0,05$.

ally during the first three months of life, occupying on the 90th day $7.78 \pm 1.15\%$, which 8.89% less than in newborns. The fraction of central veins on the first day of life is $3.11 \pm 0.82\%$ of the total area of the lobes. This indicator decreases from birth to the 21st day to $2.00 \pm 0.70\%$, which is 1.11% lower than on the first day of life. But from the 21st to the 90th day it gradually increases by 2.07%, making $4.07 \pm 0.85\%$ by the 90th day of life. The process of formation of interlobular bile ducts is accompanied by a gradual increase in the relative area interlobular ducts occupies during the first week of postnatal life by 0.89% from $1.33 \pm 0.54\%$ on the first day to $2.22 \pm 0.78\%$, on the 7th day of life. On the 14th day, there is a de-

crease in the relative area occupied by the interlobular bile ducts by 0.43% compared with the previous observation period, and a further gradual increase to the 60th day to $3.33 \pm 0.77\%$. On the 90th day, the indicator of the relative area of the interlobular bile ducts does not differ from the indicators of the 60th day of observation, which indicates the end of the formation of intrahepatic bile ducts.

The absolute number of endothelial sinusoids of the central zone of the hepatic lobes in the intact and control groups has slight deviations throughout the observation period with a maximum increase in the seventh (8.17 ± 1.04 cells on unit area) and a minimum value at 90 days life (5.39 ± 1.04 cells on unit area).

In the peripheral zone of the lobes, the minimum number of sinusoidal endothelial cells occurs on the 1st day of observation and is 4.35 ± 0.69 cells on unit area, and then the number of endothelial cells gradually increases, reaching a maximum at 7th day (8.70 ± 1.04 cells on unit area). Upon further observation, the content of endothelial cells from the 14th to the 60th day of life ranges from 6.09 ± 0.87 to 6.78 ± 1.04 cells on unit area. On the 90th day of life, this number is 7.13 ± 1.04 cells on unit area, which exceeds that in the central zone of the lobes.

The dynamics of change in the relative area occupied by the interlobular arteries has a wavy character, gradually increasing by 2.04% throughout the observation period (from $1.11 \pm 0.49\%$ on the first day to $3.15 \pm 0.75\%$ on the 90th day of life). The peak of growth occurs on the 30th day of life, reaching $3.85 \pm 0.97\%$. The dynamics of the relative area occupied by the interlobular veins is also uneven in nature with minimal values at the end of the second week of life ($2.05 \pm 0.72\%$), with a subsequent gradual increase to $4.07 \pm 0.85\%$ by 60 -in the days of life. The connective tissue of the liver is mainly represented by collagen fibers, which are located around the interlobular vessels, form a framework of sinusoids and are placed in the capsule of the liver. The dynamics of the relative area occupied by connective tissue in the group of intact and control animals, has the character of a gradual increase from the first to the 60th day of life, increasing by 2.22%. The indicator of the relative area are taken by connective tissue on the 90th day does not differ from the indicator of the 60th day and is $3.33 \pm 0.77\%$, which also indicates the completion of the formation processes of the liver stroma.

In experimental animals after antenatal administration of staphylococcal toxoid, the relative area occupied by hepatic plates (as in the control) tends to increase gradually during the first two weeks of life. However, similar values exceed in the intact and control groups, reach a statistically significant difference at 3rd day of life, exceed this figure in the control group by 8.52% ($66.67 \pm 2.48\%$ in the experimental group and $58.15 \pm 3.00\%$ - in the control group). In animals of this group in the central zone of the lobes, there is an increase in the number of multinucleated hepatocytes during the first three weeks of postnatal life with a maximum content on the first day of life, which is 2.85 times more than in the control (6.61 ± 0.70 cells on unit area).

The dynamics of changes in the relative area occupied by sinusoids in experimental animals is also wavy in nature, gradually decreasing from the first to the 90th day of life by 11.37%. However,

there is an increase in the relative area of sinusoids on the 21st day of life, which exceeds the number in the control group by 5.72%. The absolute number of endothelial cells in the central zone on the 1st day is significantly lower than in the intact and control group (7.48 ± 0.87 cells on unit area - in the control group and 4.35 ± 0.70 cells on unit area - in the experiment). That is most likely due to a compensatory increase in the number of hepatocytes, their size on the background of intrauterine antigenic load, which is confirmed by a decrease in the relative area occupied by sinusoids of the liver in this group of animals. Upon further observation, the number of endothelial cells increases and slightly exceeds similar indicators of the intact and control groups. The dynamics of the relative area occupied by sinusoids exceeds the control group on the 21st day of observation ($13.72 \pm 1.66\%$ in the experimental group and $8.00 \pm 1.36\%$ in the control group). The relative area occupied by connective tissue in the experimental group of animals is higher than in the control group from the 14th to the 30th day of life, but such an increase does not become statistically significant. The relative area occupied by the interlobular arteries has a wavy nature of changes throughout the observation period with a tendency to gradually increase slightly exceeding the intact and control groups during the first two weeks of life. However, during further observation, there is a slight decrease in the relative area occupied by the interlobular arteries compared to control, but such changes have no statistical significance. The relative area occupied by the interlobular veins also has a wavy dynamics during the observation with a slight decrease compared to the control on the 1st, 7th and 60th day of the study, and slightly exceeds the control group on the 3rd, 14th, 21st, 30th and 90th day. However, such changes do not become statistically significant and are probably due to changes in the relative area of other studied structures of the classical lobule (sinusoids, liver plates and foci of hematopoiesis).

The number of stellate macrophages of the central zone of the classical lobule in the dynamics of observation in intact and control animals increases unevenly during the 1st to 90th day of life from 8.52 ± 1.04 cells on unit area up to 10.43 ± 1.39 cells on unit area with short-term depression of the indicator on the 3rd and 7th day (6.78 ± 1.04 and 7.83 ± 0.86 cells on unit area, respectively). Similar dynamics of the number of stellate macrophages is observed in the peripheral zone of the liver lobes. The number of stellate macrophages after staphylococcal toxoid administration is uneven with a peak of growth in the peripheral zone of the lobes on the 14th day of observation and a maximum decrease in the central zone on the 30th day of observation. Intra-tissue lymphocytes are

Group of animals	Day of life				
		1	3	7	14
Intact group	MoH	49,74 ± 1,22	49,57 ± 1,57	54,09 ± 1,57	66,61 ± 1,39
	MH	3,13 ± 0,52	4,17 ± 0,86	5,22 ± 0,86	1,91 ± 0,52
	M	1,91 ± 0,52	1,74 ± 0,52	1,74 ± 0,52	0,87 ± 0,35
	EC	6,78 ± 0,87	6,96 ± 1,22	8,17 ± 1,04	5,91 ± 1,04
	SM	9,22 ± 1,04	8,00 ± 1,04	8,17 ± 0,86	11,30 ± 1,57
	L	1,91 ± 0,52	1,57 ± 0,52	1,22 ± 0,52	1,39 ± 0,52
	Oth	5,57 ± 1,04	2,78 ± 0,86	2,43 ± 0,69	1,04 ± 0,35
	HC	15,30 ± 1,74	15,30 ± 2,61	7,65 ± 1,73	1,39 ± 0,69
Control group	MoH	51,83 ± 1,22	48,35 ± 1,57	54,96 ± 1,57	66,61 ± 1,39
	MH	2,26 ± 0,52	3,65 ± 0,86	4,87 ± 0,86	1,57 ± 0,52
	M	1,91 ± 0,52	1,91 ± 0,69	1,57 ± 0,52	0,87 ± 0,35
	EC	7,48 ± 0,87	7,83 ± 1,22	8,17 ± 1,04	7,30 ± 1,22
	SM	8,52 ± 1,04	6,78 ± 1,04	7,83 ± 0,86	10,61 ± 1,39
	L	2,26 ± 0,52	1,74 ± 0,52	1,04 ± 0,34	1,57 ± 0,52
	Oth	5,57 ± 1,04	4,00 ± 0,86	2,96 ± 0,86	1,74 ± 0,52
	HC	16,17 ± 2,09	13,91 ± 2,43	7,48 ± 1,56	1,04 ± 0,35
Animals, which were exposed to antenatal Staphylococcal purified liquid toxoid administration	MoH	48,87 ± 2,26	49,91 ± 1,22	55,48 ± 1,57	65,39 ± 1,04
	MH	6,61 ± 0,70*	4,35 ± 0,86	4,87 ± 0,86	2,09 ± 0,52
	M	2,43 ± 0,70	2,61 ± 0,69	1,57 ± 0,52	1,22 ± 0,35
	EC	4,35 ± 0,70*	9,04 ± 1,04	10,09 ± 1,04	7,48 ± 1,04
	SM	7,30 ± 0,87	6,26 ± 0,86	7,83 ± 0,86	11,48 ± 1,39
	L	1,04 ± 0,35	1,74 ± 0,52	1,04 ± 0,34	1,39 ± 0,52
	Oth	8,35 ± 1,57	3,83 ± 0,86	3,83 ± 0,86	2,78 ± 0,69
	HC	9,91 ± 2,26*	9,91 ± 1,91	5,04 ± 1,39	-

Table 4: Dynamics of the cell composition of the central zone of the classical lobule from 1 to 14 days of life on unit area of 10,000 μm^2

Notes: MoH - Mononuclear Hepatocyte; MH - Multinucleated Hepatocyte; M - Hepatocyte with Signs of Mitosis; EC - Sinusoidal Endothelial Cell; SM - Stellate Macrophage; L - Lymphocyte; Oth - Other - other cells; HC - Hematopoietic Cell; * Indicator shows statistically significance in comparison with the control group $p < 0,05$.

Group of animals	Day of life				
		1	3	7	14
Intact group	MoH	52,35 ± 1,22	51,30 ± 1,57	52,35 ± 1,39	68,35 ± 1,57
	MH	2,26 ± 0,52	4,87 ± 0,86	4,52 ± 0,69	1,91 ± 0,52
	M	2,96 ± 0,69	2,26 ± 0,69	2,26 ± 0,52	0,87 ± 0,34
	EC	4,87 ± 0,86	7,83 ± 1,21	9,04 ± 1,04	6,96 ± 1,39
	SM	7,65 ± 1,04	7,48 ± 1,04	8,17 ± 0,86	11,65 ± 1,39
	L	4,00 ± 0,69	2,43 ± 0,69	1,57 ± 0,52	1,91 ± 0,52
	Oth	9,22 ± 1,21	3,65 ± 1,04	3,48 ± 0,86	2,09 ± 0,86
	MoH	11,48 ± 1,56	12,70 ± 2,26	6,26 ± 1,39	1,39 ± 0,69
Control group	MoH	50,96 ± 1,04	50,43 ± 1,57	53,04 ± 1,22	67,30 ± 1,22
	MH	2,43 ± 0,52	5,04 ± 0,86	4,87 ± 0,86	1,57 ± 0,52
	M	2,43 ± 0,52	2,61 ± 0,69	2,78 ± 0,69	0,70 ± 0,34
	EC	4,35 ± 0,69	7,65 ± 1,22	8,70 ± 1,04	6,78 ± 1,04
	SM	9,57 ± 1,21	8,35 ± 1,22	8,52 ± 0,86	9,56 ± 1,22
	L	3,13 ± 0,52	2,43 ± 0,69	2,43 ± 0,52	1,74 ± 0,52
	Oth	6,78 ± 1,04	4,35 ± 0,86	5,04 ± 1,04	2,26 ± 0,69
	MoH	11,83 ± 1,73	11,83 ± 2,26	7,30 ± 1,56	1,39 ± 0,69
Animals, which were exposed to antenatal Staphylococcal purified liquid toxoid administration	MoH	52,70 ± 2,26	50,61 ± 1,39	53,74 ± 1,57	65,04 ± 1,22
	MH	2,61 ± 0,69	4,35 ± 0,86	4,70 ± 0,69	2,43 ± 0,52
	M	2,61 ± 0,86	2,61 ± 0,69	2,26 ± 0,52	1,39 ± 0,34
	EC	2,61 ± 0,69	8,87 ± 1,22	10,26 ± 1,04	9,04 ± 1,22
	SM	6,61 ± 1,21	6,78 ± 1,04	6,61 ± 0,86	13,74 ± 1,56*
	L	3,13 ± 0,69	1,74 ± 0,52	1,57 ± 0,52	1,57 ± 0,52
	Oth	6,61 ± 1,56	4,00 ± 0,86	4,87 ± 1,04	3,30 ± 0,86
	MoH	10,09 ± 2,26	7,65 ± 1,91	4,17 ± 1,21	-

Table 5: Dynamics of the cell composition of the peripheral zone of the classical lobule from 1 to 14 days of life on unit area of 10,000 μm^2 .

Notes: MoH - Mononuclear Hepatocyte; MH - Multinucleated Hepatocyte; M - Hepatocyte with Signs of Mitosis; EC - Sinusoidal Endothelial Cell; SM - Stellate Macrophage; L - Lymphocyte; Oth - Other - other cells; HC - Hematopoietic Cell; * indicator shows statistically significance in comparison with the control group $p < 0,05$.

Group of animals	Day of life				
		21	30	60	90
Intact group	MoH	61,57 ± 1,22	56,17 ± 1,91	50,96 ± 1,57	45,39 ± 1,57
	MH	3,65 ± 0,70	6,78 ± 1,22	7,65 ± 1,22	7,83 ± 1,22
	M	0,70 ± 0,35	1,04 ± 0,35	0,70 ± 0,35	0,70 ± 0,35
	EC	5,91 ± 1,04	6,09 ± 1,04	5,22 ± 1,04	4,52 ± 1,04
	SM	10,61 ± 1,39	10,09 ± 1,56	10,43 ± 1,39	10,09 ± 1,39
	L	1,91 ± 0,52	1,39 ± 0,52	1,04 ± 0,35	1,04 ± 0,35
	Oth	1,22 ± 0,35	0,70 ± 0,35	1,22 ± 0,35	2,09 ± 0,52
Control group	MoH	62,09 ± 1,57	58,96 ± 1,74	53,74 ± 1,57	46,26 ± 1,57
	MH	3,13 ± 0,70	7,65 ± 1,22	7,48 ± 1,22	7,65 ± 1,22
	M	0,87 ± 0,35	1,57 ± 0,52	0,87 ± 0,35	0,87 ± 0,35
	EC	6,96 ± 1,04	7,83 ± 1,39	6,43 ± 1,04	5,39 ± 1,04
	SM	10,61 ± 1,39	11,48 ± 1,57	10,78 ± 1,39	10,43 ± 1,39
	L	1,39 ± 0,52	2,61 ± 0,69	1,39 ± 0,52	1,39 ± 0,52
	Oth	1,91 ± 0,52	1,04 ± 0,35	1,39 ± 0,52	1,74 ± 0,52

Animals, which were exposed to antenatal Staphylococcal purified liquid toxoid administration	MoH	60,00 ± 1,22	54,43 ± 1,74	54,09 ± 1,57	44,35 ± 1,57
	MH	3,65 ± 0,70	5,57 ± 0,87	5,74 ± 1,04	5,91 ± 1,04
	M	0,70 ± 0,35	0,52 ± 0,35	0,70 ± 0,35	0,70 ± 0,35
	EC	7,65 ± 1,04	9,39 ± 1,22	7,65 ± 1,22	6,96 ± 1,22
	SM	10,78 ± 1,04	6,09 ± 1,04*	10,09 ± 1,22	13,74 ± 1,22
	L	1,22 ± 0,52	0,70 ± 0,35*	1,22 ± 0,52	1,04 ± 0,52
	Oth	1,74 ± 0,52	1,04 ± 0,35	1,39 ± 0,52	1,04 ± 0,52

Table 6: Dynamics of the cell composition of the central zone of the classical lobules from 21 to 90 days of life on unit area of 10,000 μm^2 .

Notes: MoH - Mononuclear Hepatocyte; MH - Multinucleated Hepatocyte; M - Hepatocyte with Signs of Mitosis; EC - Sinusoidal Endothelial Cell; SM - Stellate Macrophage; L - Lymphocyte; Oth - Other - other cells; HC - Hematopoietic Cell; * indicator shows statistically significance in comparison with the control group $p < 0,05$.

Group of animal	Day of life				
		21	30	60	90
Intact group	MoH	64,70 ± 1,91	63,13 ± 1,74	56,00 ± 1,22	50,26 ± 1,57
	MH	2,78 ± 0,70	3,83 ± 0,70	5,57 ± 1,04	7,30 ± 1,22
	M	1,04 ± 0,35	1,04 ± 0,35	0,70 ± 0,35	0,52 ± 0,17
	EC	6,09 ± 1,04	5,04 ± 0,87	6,09 ± 1,04	6,96 ± 1,22
	SM	10,09 ± 1,22	8,17 ± 1,04	8,00 ± 1,04	9,04 ± 1,04
	L	2,09 ± 0,52	1,39 ± 0,52	1,22 ± 0,52	1,39 ± 0,52
	Oth	1,57 ± 0,52	1,57 ± 0,52	1,04 ± 0,35	0,87 ± 0,35
Control group	MoH	64,00 ± 1,57	61,74 ± 1,39	54,43 ± 1,22	49,22 ± 1,39
	MH	3,30 ± 0,70	4,70 ± 0,87	6,09 ± 1,04	6,96 ± 1,04
	M	1,22 ± 0,52	0,87 ± 0,35	0,70 ± 0,35	0,87 ± 0,35
	EC	6,78 ± 1,04	6,09 ± 0,87	6,61 ± 1,04	7,13 ± 1,04
	SM	8,35 ± 1,04	6,61 ± 1,22	7,30 ± 0,87	8,52 ± 1,04
	L	1,74 ± 0,52	1,22 ± 0,35	0,87 ± 0,35	1,04 ± 0,35
	Oth	1,91 ± 0,52	2,26 ± 0,70	0,87 ± 0,35	0,70 ± 0,35
Animals, which were exposed to antenatal Staphylococcal purified liquid toxoid administration	MoH	61,04 ± 1,39	56,70 ± 1,22*	51,65 ± 1,22	46,26 ± 1,91
	MH	2,43 ± 0,52	3,13 ± 0,70	5,04 ± 0,87	7,48 ± 1,39
	M	0,70 ± 0,35	0,52 ± 0,17	0,70 ± 0,35	0,87 ± 0,35
	EC	6,43 ± 1,04	6,09 ± 0,87	6,78 ± 1,04	6,96 ± 1,22
	SM	6,43 ± 1,04	4,87 ± 0,87	7,83 ± 1,04	11,30 ± 1,22
	L	1,57 ± 0,52	0,87 ± 0,35	1,04 ± 0,35	1,39 ± 0,52
	Oth	1,57 ± 0,52	2,61 ± 0,87	1,04 ± 0,35	1,04 ± 0,52

Table 7: Dynamics of the cell composition of the peripheral zone of the classical lobules from 21 to 90 days of life on unit area of 10,000 μm^2 .

Notes: MoH - Mononuclear Hepatocyte; MH - Multinucleated Hepatocyte; M - Hepatocyte with Signs of Mitosis; EC - Sinusoidal Endothelial Cell; SM - Stellate Macrophage; L - Lymphocyte; Oth - Other - other cells; HC - Hematopoietic Cell; * Indicator shows statistically significance in comparison with the control group $p < 0,05$.

constantly present in the liver; which are located in all areas of the lobules. The number of lymphocytes in the central zone of the liver lobule of intact and control animals in the dynamics of observation is wavy in nature with a maximum number of cells per 1 (2.26 ± 0.52 cells on unit area) and 30- in (2.61 ± 0.69 cells on unit area) day of observation. On the 60th and 90th day of life, the number of lymphocytes in the central zone of the lobules decreases and is 1.39 ± 0.52 cells on unit area.

In animals, which were exposed to antenatal Staphylococcal purified liquid toxoid administration, the number of lymphocytes in the central zone of the liver lobule is lower than in the intact and control groups on the first day is 1.04 ± 0.35 cells on unit area. (2.26 ± 0.52 cells on unit area in control). The maximum decrease in the number of lymphocytes in the central zone in experimental rats in contrast to the control occurs on the 30th day of life together with a simultaneous decrease in the number of Kupffer macrophages and is 0.70 ± 0.35 cells on unit area - in the experiment (2.61 ± 0.69 cells on unit area in the control group). A decrease in the number of lymphocytes is observed also in the peripheral zone of the lobule compared with the control from the third to the 30th day of life, but such changes have no statistical significance. Thus, on the 3rd day of life, the absolute number of lymphocytes in the experimental group of animals is 1.74 ± 0.52 (2.43 ± 0.69 - in the control); on the 7th day - 1.57 ± 0.52 (2.43 ± 0.52 - in control); on the 14th and 21st day - 1.57 ± 0.52 (1.74 ± 0.52 - in the control) and on the 30th day 0.87 ± 0.35 in the experimental group (0.35 - in the control group).

Dendritic cells represent a pool of antigen-presenting cells in the liver. Their cytoplasmic membrane, cytoplasmic inclusions and nuclear membrane contain receptors for β -D-Gal carbohydrate residues. The affinity of Lectin from *Ricinus communis* Agglutinin (RCA) and its ability to bind specifically to β -D-galactose receptors have been used to detect RCA⁺ dendritic cells in the liver. The dynamics of the content of RCA⁺ dendritic cells in the central and peripheral zone of the classical lobule in the intact and control groups tends to gradually decrease during the first two weeks of postnatal life.

In the peripheral zone of the lobes during the first week, the absolute number of RCA⁺ dendritic cells exceeds the Central zone, with subsequent observation, the number of RCA⁺ dendritic cells in the peripheral zone is less than in the Central zone (Figure 2, 3). In animals that were exposed to antenatal Staphylococcal purified liquid toxoid administration the number of dendritic cells

decreases from the 3rd to the 14th day, with minimal values on the 3rd day. In the peripheral zone of the lobule, the minimum number of dendritic cells is observed on the 1st (3.18 ± 0.30 cells on unit area in the experimental and 4.32 ± 0.36 cells on unit area in the control group) and the 21st day (0.72 ± 0.18 cells on unit area in the experimental and 1.68 ± 0.30 cells on unit area in the control). In the group of animals that were exposed to antenatal Staphylococcal purified liquid toxoid administration a decrease in the absolute number of RCA⁺ dendritic cells in both areas of observation during the first three weeks of life with subsequent leveling of changes.

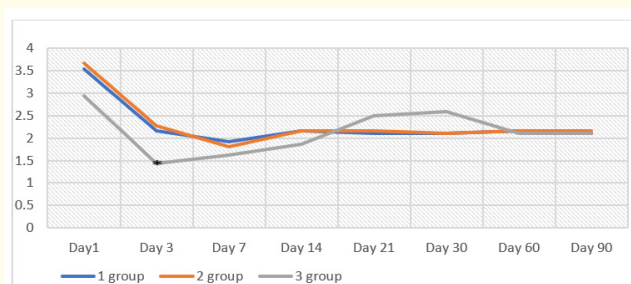


Figure 2: Dynamics of the content of dendritic cells of the central zone of the classical lobules.

Notes: 1 - intact group; 2 - control group; 3 - animals that were exposed to antenatal Staphylococcal purified liquid toxoid administration; * indicator shows statistically significance in comparison with the control group $p < 0,05$.

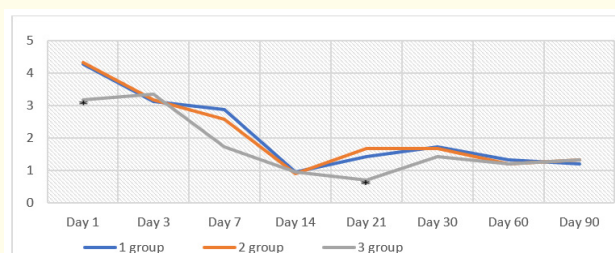


Figure 3: Dynamics of the dendritic cells content in the peripheral zone of the classical lobules.

Notes: 1 - intact group; 2 - control group; 3 - animals that were exposed to antenatal Staphylococcal purified liquid toxoid administration; * indicator shows statistically significance in comparison with the control group $p < 0,05$.

Conclusion

In rats that were exposed to antenatal Staphylococcal purified liquid toxoid administration the absolute mass of the liver exceeds the intact and control groups, reaching statistically significant values on the 14th day after birth. The relative mass of the liver in experimental group rats significantly exceeds the control at the seventh day of life. That is, exceeded indexes of absolute and relative mass of the liver throughout two weeks of postnatal life in rats after antenatal Staphylococcal purified liquid toxoid administration reflects the items of conception of inner organs visceromegalia, which develops on the background of intranatal antigen influence, elaborated by professor M. Voloshyn (2004, 2006) [3,9,10]. The main idea of this concept lays in earlier emerging of different types of lymphocytes (including $\gamma\delta$ -lymphocytes, PNA+ lymphocytes, partly immunologically immature lymphocytes etc.) from thymus to peripheral lymphoid and nonlymphoid organs [10-12]. These lymphocytes influence on cells of microenvironment that results in changes of lymphocyte/fibroblast, fibroblast/fibrocyte, mitotic and other indexes of organs. It was also established, that on the background of intranatal antigen influence, distribution, quality of connective tissue fibers, components of extracellular matrix. This model of intranatal antigen injection turned to be an experimental model of undifferentiated dysplasia of connective tissue [11,12]. It is settled to be of great practical importance, as soon as these changes are transitory ones, not a pathology, they show, that organs of a child after intranatal antigen influence are not functionally mature and any influence of harmful factors in early childhood most likely may lead to disease development in comparison with a child whose fetal period was "cloudless".

In rats that were exposed to antenatal Staphylococcal purified liquid toxoid administration the number of dendritic cells decreases during the first two weeks of life. Transitory decrease in number of dendritic cells after antenatal Staphylococcal purified liquid toxoid administration is a sign of impaired immune function of the liver including immature immune response to antigens. The obtained result can be taken into consideration for adjusting of child's menu, preferring of natural feeding avoiding of allergic products or administration of sorbents especially given the fact of pancreatic functional insufficiency [2], developed on the background of antenatal antigen influence.

Research Funding

This work is a part of a project «Reactivity of newborn organs after influence of antigens and different nature factors in the pre-

natal period» (2013-2019, state registration 0115U003875) funded by Zaporizhzhia State Medical University.

Conflicts of Interest

Authors have no conflict of interest to declare.

Bibliography

1. Dovgal GV. "Morphological changes in the development of rat liver after the lead acetate treatment and under the correction in the prenatal period". Український морфологічний альманах 12.1 (2014): 42-44.
2. Grynivetska NV and Hryhorieva OA. "Dynamics of distribution WGA+ receptors in pancreas in norm and after intranatal action of antigens". Reports of Vinnytsia National Medical University 23.31 (2019): 94-97.
3. Grynivetska NV. "Dynamics of pancreas mass indexes in early postnatal period after intranatal antigen injection [in Ukraine]". Actual questions of pharmacy and medical science and practice 14 (2011): 14.
4. Hryhorieva O., et al. "Intranatal antigen injection as an experimental model of undifferentiated connective tissue syndrome". Abstracts of V International Scientific and practical Conference "Study of modern problems of civilization", Oslo, Norway 19-23 October, (2020): 206-208.
5. Hryhorieva OA and Grynivetska NV. "Morphological features of alteration of pancreatic stroma in rats with experimental undifferentiated dysplasia of connective tissue [in Ukraine]". *Clinical Anatomy and Operative Surgery* 18.31 (2019): 46-51.
6. Hryhorieva OA., et al. "Peculiarities of synoviocytes and chondrocytes proliferative activity in rats with experimental model of undifferentiated dysplasia of connective tissue". *World of Medicine and Biology* 2.76 (2021): 198-202.
7. Hryhorieva O A., et al. "Intrafetal injection of antigens as an experimental model of undifferentiated dysplasia of connective tissue". Medico-biological aspects and multidisciplinary integration in the concept of human health : proceedings of Ukr. Conf. with int. Participation (Ternopil, 9-11 April 2020.) in III parts/Ternopil. Nat.Med.Univ named after I Horbachevsky MPH of Ukraine. - Ternopil : TNMU, 2020. -Part I (2020): 37-40.

8. Slobodyan OM., *et al.* "Prenatal development of hepatic veins". *Clinical Anatomy and Operative Surgery* 14.2 (2015): 38-41.
9. Voloshyn MA., *et al.* "Visceromegalia of newborns: morphological aspects". Kharkiv: Kharkiv State Medical University (2004): 123.
10. Voloshyn MA., *et al.* "Intranatal antigen injection as a model of visceromegalia sympomocomplex". *Tavria Medico-Biological Reports* 9.3/4 (2006): 41-44.
11. Voloshin NA and Hrihorieva OA. "Experimental model of undifferentiated connective tissue dysplasia syndrome". *Pathologia* 6.1 (2009): 39-42.
12. Voloshyn MA and Hryhorieva OA. "Experimental model of undifferentiated dysplasia of connective tissue by impaired antigen homeostasis in the system of mother-placenta-foetus". *Pathologia* 8.2 (2011): 39-42.
13. Znamenska T K., *et al.* "Strategichni napryamki rekonstrukcii systemi ohoroni zdorovya novonarodjenich ta ditey Ukraini [Strategic directions of reconstruction of the system of health guard of new-born and children of Ukraine]". *Social'na Pediatriya Ta Reabilitologiya -Social Paediatrics and Rehabilitology* 1-2.13-14 (2018): 7-14.

Volume 4 Issue 11 November 2021

© All rights are reserved by Pivtorak VI., *et al.*