

Asymptomatic Primary Biliary Cirrhosis Revealed by Non Convulsive Status Epilepticus

Oumerzouk Jawad^{1*}, Louhab Nissrine², Chraa Mohamed² and Kissani Najib²

¹Neurology Department, Military Hospital of Marrakech, Avicenne, Morocco

²Neurology Department, Mohamed VI Hospital, Marrakech, Morocco

*Corresponding Author: Oumerzouk Jawad, Neurology Department, Military Hospital of Marrakech, Avicenne, Morocco.

Received: May 03, 2021

Published: May 11, 2021

© All rights are reserved by Oumerzouk Jawad., et al.

Abstract

We report the case report of a 71-year-old patient admitted for confusional syndrome. The electroencephalogram showed electrical signs in favor of a status epilepticus with a slowing of the background activity and recording of numerous epileptic spike-wave discharges, quasi-continuous and rhythmic. The ionogram showed hepatic cholestasis with hepatocellular insufficiency: GGT = 71 ui/l (7 - 50), PAL = 196 ui/l (32 - 91), ASAT = 61 ui/l (15 - 41), ALAT = 38 ui/l (14 - 54), total bilirubin = 35 mg /l (3 - 12), direct bilirubin = 8 mg/l (1 - 5), hyperammonemia = 126.2 mol/l (11 - 51) with TP = 66%, TCA = 42/33 and hypoalbuminemia = 23 g/l (35 - 50). The immunological assessment showed the positivity of the antinuclear antibodies (titer > 320) and of the anti-mitochondria antibodies (IFI), with negative anti-LKM1 and anti-smooth muscle antibodies. The patient received symptomatic treatment of hepatic encephalopathy, combined with an antiepileptic treatment based on levetiracetam 500 mg, twice a day, and treatment with azathioprine 50 mg, twice a day, combined with ursodeoxycholic acid. Regular monitoring did not record a relapse. In conclusion, a non-convulsive status epilepticus in an elderly patient with biological cholestasis should suggest the diagnosis of PBC.

Keywords: Epilepticus; Status; Cholestasis

Introduction

Primary biliary cirrhosis (PBC) is a granulomatous disease of the bile ducts, responsible for a chronic cholestatic disorder. It is a slowly progressing autoimmune disease with a poor prognosis, sometimes with a fatal outcome and is commonly associated with other autoimmune diseases. We report the clinical case of a 71-year-old patient with non-convulsive status epilepticus associated with asymptomatic PBC.

Case Report

A 71-year-old patient, followed for 20 years for chronic obstructive pulmonary disease under seretide (fluticasone), and iron deficiency anemia for 8 months under iron treatment, admitted for non-convulsive status epilepticus. The onset of symptoms 3 months before his hospitalization was characterized by mood and behav-

ioral disorders, comprising irritability with psychomotor slowing and memory problems. The evolution was marked by the rapidly progressive worsening of neurological symptoms, with the onset of delirium, which prompted his hospitalization in the medical intensive care unit. The general examination found a patient who was afebrile, eupneic, subicteric, Blood pressure = 140/80 mmHg, capillary glucose = 1.21 g/l, SaO₂ = 100%. Neurological examination found a patient with GCS = 13, obnubilated, flexible neck, absence of sensory-motor deficit with increased deep tendon reflexes in the right lower limb, present in the left lower limb and upper limbs with a Babinski on the right side. Tone examination also noted plastic hypertonia in the right half of the body. The examination of sensitivity, coordination, and cranial nerves was unremarkable. Abdominal examination revealed a liver of irregular hard surface with a sharp anterior edge, skin and mucous membrane pallor

with digital hippocratism and a slight conjunctival jaundice, without ascites, nor edema of the lower limbs or collateral venous circulation, and with no evidence of stellate angioma. The remainder of the somatic examination was unremarkable.

The electroencephalogram showed electrical signs supporting non convulsive status epilepticus; background electrical activity slowing, with numerous epileptic abnormalities such as quasi-continuous rhythmic spike-waves (Figure). The lumbar puncture collected a clear fluid, with 0 WBC, CSF proteins = 0.37g/l, CSF glucose = 0.55g/l, absence of pathogens on direct examination and after culture. The brain MRI was normal. The complete blood count revealed normochromic macrocytic anemia at 11.8 g/dL, thrombocytopenia at 123,000/mm³, without leukopenia. The biochemistry panel revealed hepatic cholestasis with hepatocellular insufficiency: GGT = 71 iu/l (7 - 50), ALP = 196 iu/l (32 - 91), AST = 61 iu/l (15 - 41), ALT = 38 iu/l (14 - 54), total bilirubin = 35 mg/l (3 - 12), direct bilirubin = 8 mg/l (1 - 5), hyperammonemia at 126.2 mol/L (11 - 51) with TP = 66%, TCA = 42/33 and hypoalbuminemia at 23 g/l (35 - 50), CRP = 16.6 mg/l (1 - 7,5), serum ferritin = 67.78 (70 - 435). Electrophoresis of plasma proteins demonstrated a moderate polyclonal increase in gammaglobulins with significant hypoalbuminemia. Immunological studies showed positivity of antinuclear antibodies (titer > 320; speckled nuclear fluorescence) and anti-mitochondrial antibodies (IFI), with negative anti-LKM1 and anti-smooth muscle antibodies, which made it possible to retain the diagnosis of PBC without associated autoimmune hepatitis.

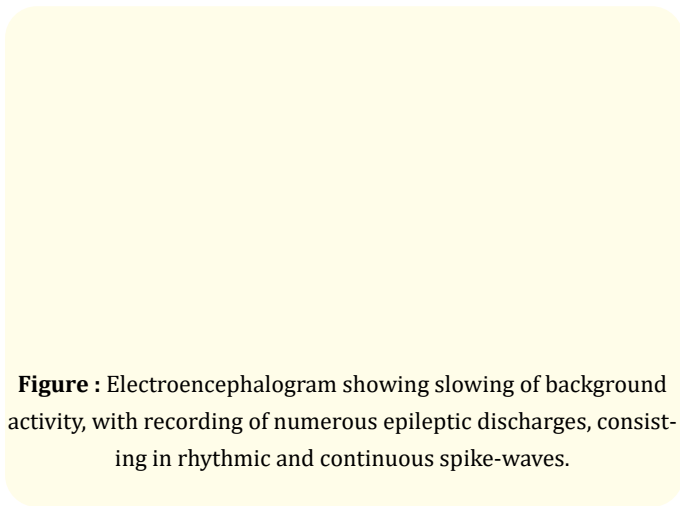


Figure : Electroencephalogram showing slowing of background activity, with recording of numerous epileptic discharges, consisting in rhythmic and continuous spike-waves.

Abdominal ultrasound and abdominal CT showed chronic disease of the liver which was of normal size and irregular contours, homogeneous without focal lesions, or dilation of the bile ducts or portal trunk. Oeso-gastro-duodenal fibroscopy revealed erythematous antritis without esophageal varices. Liver biopsy was not performed and the rest of the assessment (electrocardiogram, thyroid assessment, phosphocalcic and lipid assessment, dosage of vitamins B1, B12, folate, hormonal assessment, 24 hour proteinuria, copper assessment, dosage of alpha foetoprotein, HVB, HVC, HIV and VDRL/TPHA serologies) was unremarkable.

The diagnosis of hepatic encephalopathy complicating primary biliary cirrhosis was retained based on clinical, biological, and immunological criteria, and the patient received symptomatic treatment of hepatic encephalopathy comprising: duphalac 10g/15 ml, 3 times/d; fluoroquinolone 500 mg twice daily, flumazenil 0.3 mg intravenously twice daily; aldactone 75 mg once/day in combination with antiepileptic therapy, levetiracetam 500 mg twice daily. The evolution was marked by an outright improvement in his state of consciousness, with the disappearance of mood and behavioral disorders. Control electroencephalogram showed no evidence of epileptic abnormalities. A disease-modifying treatment was prescribed: 50 mg azathioprine twice daily in combination with ursodeoxycholic acid. Regular monitoring did not record a relapse after a 3-year follow-up.

Discussion and Conclusion

Primary biliary cirrhosis (PBC) is a rare chronic cholestatic cholangitis of unknown etiology, which mainly affects women (1/10), with a median age of onset between 50 and 55 years and a clear genetic predisposition. It is a granulomatous involvement of the bile ducts, which causes progressive hepatic fibrosis and destruction of the small bile ducts, responsible for a chronic cholestatic disorder. Much later, this process leads to cirrhosis and hepatocellular failure. It is now assumed that the onset of PBC results, like other autoimmune diseases, from a combination of multiple genetic and environmental factors [1-4].

The disease is revealed by a cholestatic syndrome which for a long time is without jaundice. Certain asymptomatic forms are revealed only by a purely biological cholestasis. It is currently rare that the disease be revealed by digestive hemorrhage or ascites

due to portal hypertension and/or hepatic encephalopathy indicative of hepatocellular insufficiency. It is morphologically characterized by portal inflammation and infiltration by lymphocytes and plasma cells of the walls of small and medium-sized bile ducts leading to progressive destruction of these structures (chronic destructive non-suppurative cholangitis) [4-6].

It is a predominantly cell-mediated disease by the action of autoreactive T cells, but autoantibodies associated with the disease are particularly useful in diagnosis. In 90 - 95% of cases, high titers of anti-mitochondrial antibodies are found in the serum. The anti-mitochondrial autoantibodies (AMA2), sought by indirect immunofluorescence (IFI), ELISA, or western blot, are considered as a sensitive and specific marker of PBC, which allows the differential diagnosis between PBC and other intrahepatic cholestasis and can be detected early on in asymptomatic forms of the disease [6-8].

Although their etiopathogenic role has not yet been elucidated, their antigenic targets are, on the other hand, clearly identified. These antibodies essentially react with the multi-enzyme complex of pyruvate dehydrogenase (PDH). Many arguments suggest that AMAs are not cytotoxic and that the destruction of biliary epithelial cells is linked to the activation of CD4 lymphocytes and the cytotoxicity of CD8, or secondary to the cytokines produced by these 2 types of lymphocytes. However, we cannot systematically exclude the pathology in a patient who is seronegative for AMA2. The anti-glycoprotein-210 autoantibodies of nuclear pores represent the second immunological marker of PBC [4,8].

The detection of one of these very specific autoantibodies makes it possible to manage patients with PBC before irreversible cirrhotic damage to the liver. Many other autoantibodies are detected during PBC: antinudates (70% of patients), antithyroid, antiplatelets, acetylcholine receptor, anti-B-lamin receptor, anti-Sp100 autoantibodies, anti-PML, anti-lipid A autoantibody. Other non-specific immunological abnormalities can also be found during the disease, such as hypergammaglobulinemia predominantly on IgM, a decrease in the activity of suppressive T lymphocytes, a decrease in the macrophage function [4,9,10].

PBC is commonly associated with other autoimmune diseases in about half of cases, which should be screened routinely because of their frequency and the importance of proper management. The autoimmune diseases most frequently associated with PBC are

autoimmune hepatitis thus defining overlap syndromes, dysthyroidism associated with antithyroid antibodies, sicca syndrome, Gougerot-Sjögren syndrome, celiac disease, lupus Systemic erythematosus, scleroderma, sarcoidosis, rheumatoid arthritis, CREST syndrome, insulin-dependent diabetes, vitiligo, Biermer's anemia, and hemolytic anemia [5,7,9].

Systematic screening for PBC in the presence of these diseases is necessary in order to initiate early treatment in order to improve the prognosis of this disease. All these associations are not fortuitous, they reflect, on the clinical level, the close relationship of the immunological anomalies encountered during autoimmune affections. This relationship is observed both in terms of humoral-mediated immunological reactions and cell-mediated reactions. The appearance of multiple and varied autoantibodies represents one of the aspects of humoral immunological disorders. Many, sometimes conflicting, abnormalities of cell-mediated immunity are also common to PBC and other autoimmune disorders [7,8,11-13].

Neurological disorders unrelated to the severity of the liver damage may occur at early stages of the pathology. The neuropathies associated with PBC are very rare, and mainly take the form of painful neuropathy, dysautonomic neuropathy, axonal sensory neuropathy due to the "dying-back" phenomenon, and ataxic sensory neuropathy. Nerve biopsies often reveal axonal damage, affecting large myelinated fibers. Inflammatory myopathies are rare and have some characteristics; a muscular atrophy, a chronic evolution, an involvement especially of the axial musculature, a more severe cardiac and respiratory involvement, with a good response to prednisolone. Muscle biopsy often shows signs of granulomatous myopathy or signs of necrotizing myopathy [11-13].

The other rarer neurological disorders reported in the literature in association with PBC are recurrent aseptic meningitis (Mollaret meningitis), multiple sclerosis, mitochondrial myopathy, myasthenia gravis, chronic inflammatory demyelinating polyradiculoneuritis, Guillain - Barré syndrome, HTLV myelopathy and progressive multifocal leukoencephalopathy [11,14].

PBC is an autoimmune disease with a poor prognosis, of slow, often fatal, progression. In the absence of effective treatment, the median survival time is 5 to 8 years after onset of symptoms. Histologically, it takes about 2 years to develop extensive fibrosis. After 4 years of disease progression, 50% of patients have cirrhosis.

The etiological treatment is essentially based on anti-inflammatory or immunosuppressive drugs (Azathioprine, D penicillamine and chlorambucil). The main goal of symptomatic treatment is to fight against cholestasis and its consequences. Administration of ursodeoxycholic acid improves liver biology, pruritus, and histologically slows the progression of inflammatory biliary lesions, fibrosis and decreases the need for transplantation. The treatment initiated comprised ursodeoxycholic acid, combined with azathioprine, results in good progress in 60% of cases, with an average follow-up of 49 months [11-13].

Plasmapheresis, regardless of the technique used, can be offered in the event of failure of other treatments. They lead after each session to an improvement, even a cessation of pruritus. Liver transplantation should only be offered for advanced forms [6,9,14,15].

A non-convulsive status epilepticus indicative of asymptomatic PBC has not, to our knowledge, been described to date. In conclusion, non-convulsive status epilepticus in an elderly patient with biological cholestasis should suggest the diagnosis of PBC. Only early diagnosis and adequate management could improve the prognosis of this pathology fraught with heavy mortality.

Conflict of Interest

The authors declare that they have no conflict of interest.

Bibliography

- Grippon P, et al. "Primary biliary cirrhosis". *Revue de Médecine Interne* 9.5 (1988): 501-506.
- Bensa C., et al. "Recurrent aseptic meningitis associated with primary biliary cirrhosis". *Revue Neurologique* 161.1 (2005): 87-91.
- Corrieri-Baizeau C., et al. "Autoimmune hepatitis associated with multiple sclerosis". *Gastroentérologie Clinique et Biologique* 28.11 (2004): 1186-1187.
- Malyavantham K., et al. "Humoral Responses to Diverse Auto-immune Disease-Associated Antigens in Multiple Sclerosis". *PLoS One* 10.6 (2015): e0129503.
- Marrone A., et al. "Epstein Barr virus infection reactivation as a possible trigger of primary biliary cirrhosis-like syndrome in a patient with multiple sclerosis in the course of fingolimod treatment". *Le Infezioni in Medicina* 22.4 (2014): 331-336.
- Debray J., et al. "[Primary biliary cirrhosis and associated autoimmune diseases]". *Revue de Médecine Interne* 1.1 (1980): 81-86.
- Gautier M and Desplat-Jégo S. "Dépistage au laboratoire d'immunologie d'une forme sévère de cirrhose biliaire primitive". *Revue Francophone Des Laboratoires* 444 (2012): 91-93.
- Herrmann DN., et al. "Granulomatous myositis, primary biliary cirrhosis, pancytopenia, and thymoma". *Muscle Nerve* 23.7 (2000): 1133-1136.
- Shimizu J. "Clinical and histopathological features of myositis associated with anti-mitochondrial antibodies". *Rinsho Shinkeigaku* 53.11 (2013): 1114-1146.
- Toyooka K., et al. "A case of sensory ataxic neuropathy associated with asymptomatic primary biliary cirrhosis". *Rinsho Shinkeigaku* 50.1 (2010): 12-16.
- Maeda MH., et al. "Inflammatory myopathies associated with anti-mitochondrial antibodies". *Brain* 135.6 (2012): 1767-1777.
- Murata KY., et al. "Chronic inflammatory demyelinating polyneuropathy associated with primary biliary cirrhosis". *Journal of Clinical Neuroscience* 20.12 (2013): 1799-1801.
- Albayda J., et al. "Inflammatory myopathy associated with anti-mitochondrial antibodies: A distinct phenotype with cardiac involvement". *Seminars in Arthritis and Rheumatism* 47.4 (2018): 552-556.
- Munday WR., et al. "Guillain-Barré syndrome mimics primary biliary cirrhosis-related myopathy". *Oxford Medical Case Reports* 2015.4 (2015): 272-275.
- Toyooka K., et al. "A case of sensory ataxic neuropathy associated with asymptomatic primary biliary cirrhosis". *Rinsho Shinkeigaku* 50.1 (2010): 12-16.

Volume 4 Issue 6 June 2021

© All rights are reserved by Oumerzouk Jawad., et al.