



Three Rooted Primary Mandibular First Molar-A Rare Case Report

KM Rowank Jahan¹, Tazdik G Chowdhury^{2*}, Tasnim-A-Jannat³, Ashik Abdullah Imon⁴, Puja Shrestha⁵, Nimesh Shrestha⁵ and Mahmuda Akhter⁶

¹Lecturer, Department of Paediatric Dentistry, Update Dental College and Hospital, Dhaka, Bangladesh

²Associate Professor and Head, Department of Paediatric Dentistry, Update Dental College and Hospital, Dhaka, Bangladesh

³Lecturer, Department of Conservative Dentistry and Endodontics, Update Dental College and Hospital, Dhaka, Bangladesh

⁴Assistant Professor and Head, Department of Oral and Maxillofacial Surgery, Update Dental College and Hospital, Dhaka, Bangladesh

⁵Internee Doctor, Update Dental College and Hospital, Dhaka, Bangladesh

⁶Associate Professor, Department of Oral and Maxillofacial Surgery, Bangabandhu Sheikh Mujib Medical University, Dhaka, Bangladesh

***Corresponding Author:** Tazdik G Chowdhury, Associate Professor and Head, Department of Paediatric Dentistry, Update Dental College and Hospital, Dhaka, Bangladesh

Received: December 09, 2019

Published: January 07, 2020

© All rights are reserved by **Tazdik G Chowdhury, et al.**

Abstract

Introduction: Anatomical variation in primary molars are rare with prevalence of <0.1% but negligence of such variation will lead to consequence of dental problems in pedodontic clinical practice. The purpose of this article is to discuss about Radix Entomolaris (RE) in primary first mandibular molar and to describe its clinical significance; a very rare anomalies that are difficult to identify and remain undiagnosed.

Case Presentation: A 7 year old boy with pain on lower right side of jaw originated from mandibular left 1st and 2nd molar for last 2 days on Department of Paediatric Dentistry, Update Dental College and Hospital, Dhaka, Bangladesh. The case was diagnosed as acute closed irreversible pulpitis of three rooted mandibular right first molar and second molar and pulpectomy was scheduled for 84 abd 85.

Conclusion: Due to unusual morphology, the chance of mishaps during endodontic treatment is extremely high in the search of additional canal, which can be overcome by proper knowledge of root morphology and radiographic interpretation.

Keywords: Mandibular First Molar; Primary; Distolingual Root; Endodontic Treatment; Extra Third Root; Periapical Radiographs; Radix Entomolaris; Radix Paramolaris

Introduction

There exists anatomical differences in primary teeth from permanent teeth in relation of size, shape, and structure. Usually primary mandibular first molars have two roots with three root

canals [MB,ML and D] [2]. But presence of accessory root with extra canal is rare finding [3]. when extra root is located distolingually to the main distal root, refers "Radix Entomolaris"(RE) and when located mesiobuccally to the mesial root, is known as "Radix

Paramolaris”(RP) [4]. The objective of pediatric endodontic therapy is the extirpation of pulp tissue from the root canals, thorough chemo-mechanical cleaning followed by filling with a suitable biocompatible material [4]. It is necessary to anticipate and find all roots and canals during endodontic treatment. Despite of knowledge of all the procedures, if practitioner's miss supernumerary root or canals in primary molars, it creates a great challenge and leads to endodontic treatment failure and even tooth loss at an early age which may influence functionally, esthetically and psychologically [4]. So, practitioner must be aware regarding the chances of presence of supernumerary root and canal to perform successful endodontic treatment.

Three rooted primary mandibular first molars are rarer than permanent whereas unilateral occurrence of three rooted primary mandibular first molars is greater than bilateral occurrence [4-7]. Some studies found male predominance [7-10]. Carabelli for the first time mentioned radix entomolaris as an additional third root in permanent tooth in 1844 [11] and also described by others terms, such as 'extra third root' or 'distolingual root' or "extra distolingual root." [12]. Radix paramolaris (RP) described as the "mesiobuccal root" [13] was first described by Bolk [14] in 1915. Tratman mentioned that frequency of three rooted mandibular molars is < 1% in primary dentition and comparatively more common in the permanent dentition (9% among Malay individuals and 11% among Javanese individuals [15]. Gender predilection for an additional root in the first permanent molar has been reported by several investigators. Tratman [4] mentioned that it is more common on the right for the male and bilateral for the female.

Also prevalence of accessory root in primary mandibular second molar is 27.8%, higher than primary mandibular first molar [4]. Badger reported a case of unilateral three rooted first primary mandibular molars in a 5 year old Caucasian boy whereas Falk and Bowers reported a case of bilateral 3-rooted first primary mandibular molars in a 10 year old Western European male [16,17]. Although extra root is present in both first and second molars of the primary dentition, it is not proven about the presence of extra root in primary molars as well, though the commonly hypothesized field of development influence suggests that this is the case. The exact etiology behind the development of RE/RP is still unknown. The literature suggests that, in dysmorphic, extra roots, its formation could be related to external factors during odontogenesis, or to penetrance of an atavistic gene or polygenetic system whereas

in eumorphic roots, racial genetic factors cause more profound expression of a particular gene that results in the more pronounced phenotypic manifestation [18]. The high degree of RE in Mongoloid populations has provoked more specific analyses of the heritable basis of this supernumerary radicular structure by various authors [6,8,9]. More specifically, only Curzon [19] suggested that certain traits such as the "three-rooted molar" had a high degree of genetic penetrance as its dominance was reflected in the fact that pure Eskimo and Eskimo/Caucasian mixes had similar prevalence of the trait.

Case report and results

A 7 year old boy came with chief complaints of pain on lower right side of jaw for last 2 days on Department of Paediatric Dentistry, Update Dental College and Hospital, Dhaka, Bangladesh. Pain was continuous in nature which was aggravated during taking food. We also get slight mobility of the teeth was within normal limits and depression of the tooth with digital pressure results in pain. There was no history of systemic conditions. Height and weight of patients was 108 cm and 29 kg respectively. The mental age of the patient was found to be normal. The patient was rated as No.4 on Frankl's Behavior Rating Scale (1962). A preoperative periapical intraoral radiographic was taken. Radiographical examination revealed proximal caries on 84 and 85 and additional root was present on 84. So, we moved to the intraoral periapical radiographical examination of lower left side and 74 was two rooted with normal anatomy but proximal caries was present on 74. The third additional root was also revealed on the distal side on 84. The extra root was nearly straight and originated from distolingual aspect of the tooth. So, On the basis of pain history and clinical examination, case was diagnosed as acute irreversible pulpitis of three rooted mandibular right first molar and mandibular second molar tooth. Pulpectomy was scheduled for 84 and 85. Tell-show-do technique of behavior management was done before starting the treatment.

On the 1st appointment, following local anaesthesia with proper isolation, access opening was done. The conventional access was modified to a trapezoidal shape to improve access to additional canal. After removing the coronal pulp, and probing with DG 16 four canals were found. Working length was determined and biomechanical preparation done by H-file by standardized technique with continuous copious irrigation with normal saline. The canal was dressed with intra canal medicament, calcium

hydroxide and access cavity was sealed with fast setting Zinc Oxide Eugenol cement.

Clinical and radiographic presentation

On 2nd appointment, after 3 days, biomechanical preparation was done. The canals were dried with absorbent paper points

followed by obturation with Metaplex (Calcium hydroxide iodoform paste) and cavity was sealed with fast setting Zinc Oxide Eugenol paste. Two days later, permanent restoration was done with Auto Cure GIC followed by SS crown was done. The tooth was clinically alright after six month of follow up.

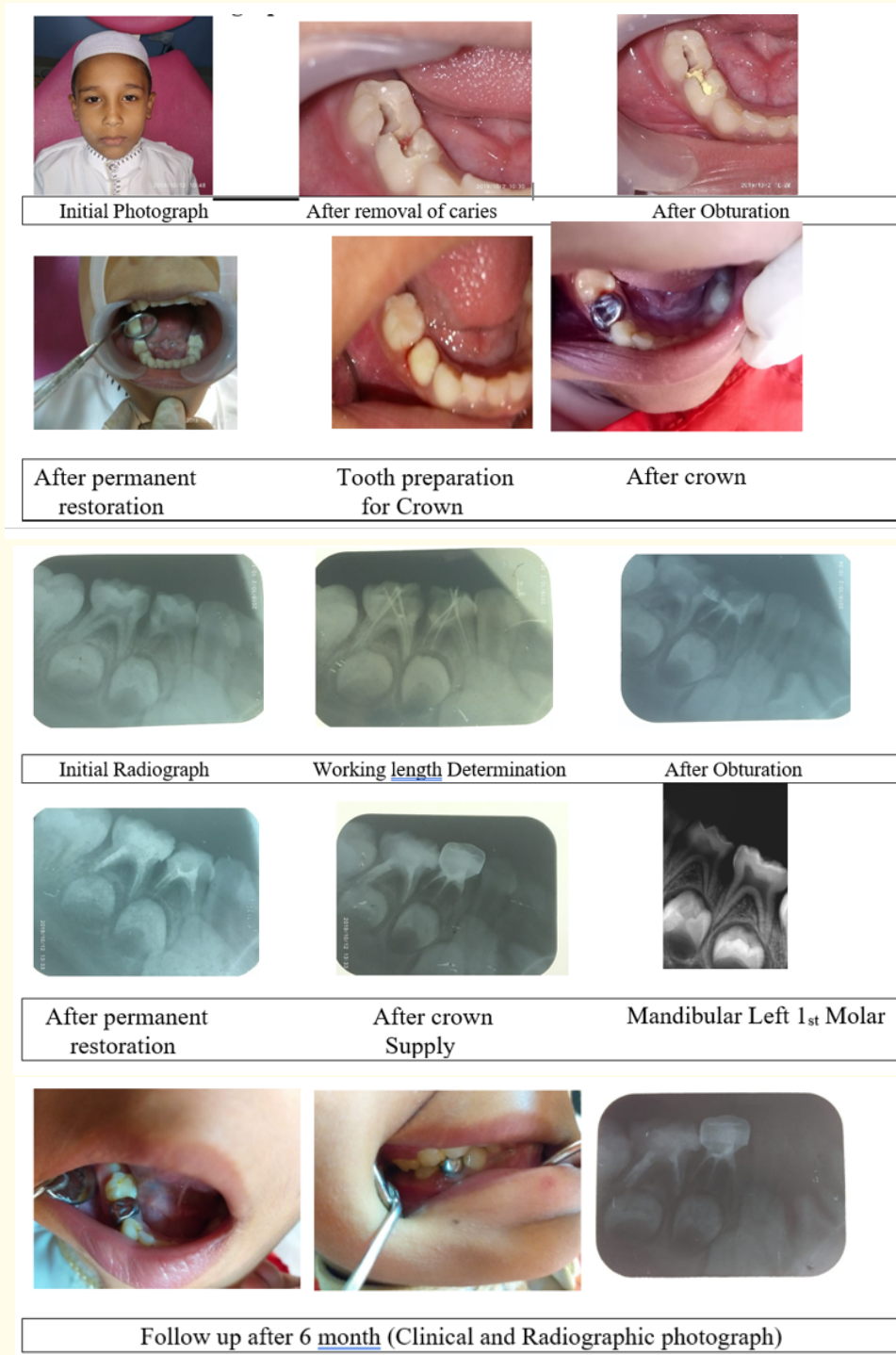


Figure 1

Discussion

Early loss of primary teeth may result in alteration in the sequence of eruption of permanent teeth; thus saving primary teeth with endodontic treatment is the best way. Endodontic treatment itself is challenge to perform in children. And anatomical variations will further increase difficulty for pediatric dentist. Many studies have discussed the endodontic, periodontal and exodontic implications of extra distal roots in permanent mandibular first molars [20,21]. As permanent mandibular molars same caution should be applied to the treatment of primary mandibular molars with extra roots. Goerig and Camp described the prominently bifurcated roots of the primary molars that allow succedaneous teeth to erupt and grow [22]. Various prevalence studies have been done using periapical radiographs [5,23-26], extracted teeth [6,27-30] recently by microcomputed tomography (micro-CT) [31-33] and cone-beam computed tomographic images (CBCT) (Table 1) [34-37]. Additional roots can be unilaterally or bilaterally present with greater prevalence unilaterally [38,39]. In these report, unilateral three rooted mandibular first primary molar is presented.

During root formation, any disturbance in the Hertwig’s epithelial root sheath[HERS] can result in splitting to form two similar roots or may fold to form an independent root with different anatomical variations [40,41]. Also some research suggested that some external factors such as local traumatic injuries, different ethnic groups, genetic factors, external pressure, some diseases and metabolic dysfunction during root formation can influence to the formation of accessory roots [42,43]. Although the exact etiology of accessory roots formation is still unknown.

Accurate clinical knowledge of the general morphology of the specific variation of a tooth is essential before contemplating pulpectomy and extraction. Appropriate straight-line access preparation and location of the orifice of the extradistal root canal typically warrants modification of the classical triangular opening technique to a trapezoidal form, to improve the localization and access to the root canals in primary mandibular first molars [2].

Author/Year	Population group	Incidence (%)
Taylor (1899) [46]	United Kingdom	3.4
Bolk (1915) [15]	Netherlands	1
Campbell (1925) [47]	Australian	0
Drennan (1929) [48]	Aborigine	0
	South African	
Shaw (1931) [49]	Bushman	0
	African Bantu	
Tratman (1938) [6]	Chinese	5.8
	Malay	8.6
	Javanese	10.9
	Indians	0.2
	Eurasians	4.2
	Japanese	1.2
Laband (1941) [31]	Malay	8.2
Pedersen (1949) [50]	Greenland Eskimo	12.5
Jorgensen (1956) [51]	Danish	0.67
Somogyi-Csizmazia and Simons (1971) [10]	Canadian Indians	16
de Souza-Freitas, et al. (1971) [9]	European	3.2
	Japanese	
Skidmore and Bjorndahl (1971) [52]	Caucasian	2.2
Turner (1971) [53]	Aleut Eskimo	32
	American Indian	
Curzon and Curzon (1971) [54]	Keewatin Eskimo	27
Curzon (1973) [55]	United Kingdom	3.4
Curzon (1974) [19]	Baffin Eskimo	21.7
Hochtstetter (1975) [29]	Guam	13
Sugiyama, et al. (1976) [56]	Japanese	5.6
Jones (1980) [28]	Chinese	13.4
	Malaysian	16

Reichart and Metah (1981) [18]	Thai	19
Walker and Quackenbush (1985) [57]	Hong Kong Chinese	14.6
Walker (1988) [58]	Hong Kong Chinese	15
Harada., et al. (1989) [59]	Japanese	18.8
Loh (1990) [27]	Chinese	7.9
Younes., et al. (1990) [60]	(Singapore) Saudi	2.92
	Egyptian	0.01
Ferraz and Pecora (1992) [26]	Japanese	11.4
	Negroid	2.8
	Caucasian	4.2
Yew and Chan (1993) [25]	Chinese	21.5
Sperber and Moreau (1998) [61]	Senegalese	3
Steelman (1998) [24]	Hispanic children	3.2
Gulabivala., et al. (2001) [24]	Burmese	10.1
Gulabivala., et al. (2002) [23]	Thai	13
Tu., et al. (2007) [5]	Taiwanese Korean	21.09
Song., et al. (2009) [62]	Primary molars (first and second)	9.7, 27.8
	Permanent first molars	33.1
Schafer., et al. (2009) [63]	Germanese	1.35
Tu., et al. (2010) [64]	Taiwanese	5
Liu., et al. (2010) [8]	Chinese	9
Garg., et al. (2010) [65]	Indian	5.97
Song., et al. (2010) [37]	Korean	24.5
Yang., et al. (2010) [66]	Shanghai Chinese	32.35
Peiris., et al. (2007) [67]	Sri Lankan	3
Huang., et al. (2010) [68]	Taiwanese	22

Table 1: Survey of available studies showing prevalence of 3-rooted mandibular first molar.

Conclusion

Preservation of primary tooth is one of the important goal of paediatric dentistry. An awareness and knowledge regarding root canal variations in primary tooth is essence in endodontic

treatment. Thus, before proceeding, clinician should assess two periapical radiographs taken in 30 degree mesial and distal angulation to confirm the presence of an extra root to reach the success of treatment [4]. Also advanced radiography such as radiovisiography and computed tomography may be helpful in diagnosing such variations [44]. Moreover, clinically presence of extra cusp or bulge on crown may raise a doubt for presence of an accessory root [45].

Bibliography

1. Shilpa G., et al. "Prevalence of dental anomalies in deciduous dentition and its association with succedaneous dentition: A cross-sectional study of 4180 South Indian children". *Journal of Indian Society of Pedodontics and Preventive Dentistry* 35 (2017): 56-62.
2. Ming-Gen Tu., et al. "Prevalence of Three-rooted Primary-Mandibular First Molars in Taiwan". *Journal of the Formosan Medical Association* 109.1 (2010).
3. Falk WV and Bowers DF. "Bilateral three rooted mandibular first primary molars: Report of case". *Journal of Dentistry for Children* 50 (1983): 136-137.
4. Nagaven NB and Umashankara KV. "Radix entomolaris and paramolaris in children: A review of the literature". *Journal of Indian Society of Pedodontics and Preventive Dentistry* 30 (2012): 94-102.
5. Tu MG., et al. "Prevalence of three-rooted mandibular first molars among Taiwanese individuals". *Journal of Endodontics* 33 (2007): 1163-1166.
6. Tratman EK. "Three-rooted lower molars in man and their racial distribution". *British Dental Journal* 64 (1938): 264-274.
7. Steelman R. "Incidence of an accessory distal root on mandibular first permanent molars in Hispanic children". *ASDC Journal of Dentistry for Children* 53 (1986): 122-123.
8. Liu JF, et al. "Prevalence of 3-rooted primary mandibular second molars among Chinese patients". *Pediatric Dentistry* 32 (2010): 123-126.
9. De Souza-Freitas JA., et al. "Anatomic variations of lower first permanent molar roots in two ethnic groups". *Oral Surgery, Oral Medicine, Oral Pathology* 31 (1971): 278-278.
10. Somogyi-Csizmazia W and Simons AJ. "Three-rooted mandibular first permanent molars in Alberta Indian children". *Journal of the Canadian Dental Association* 37 (1971): 105-106.

11. Carabelli G. "Systematisches Handbuch der Zahnheilkunde". 2nded. Vol. 114. Vienna: Braumuller and Seidel (1844).
12. De Moor RJ, et al. "The radix entomolaris in mandibular first molars: An endodontic challenge". *International Endodontic Journal* 37 (2004): 789-799.
13. Carlsen O and Alexandersen V. "Radix paramolaris in permanent mandibular molars: Identification and morphology". *Scandinavian Journal of Dental Research* 99 (1991): 189-195.
14. Bolk L. "Bemerkungen u ber Wurzelvariationen am menschlichen unteren Molaren". *Zeitung fur Morphologie Anthropologie* 17 (1915): 605-610.
15. Mokhtari S and Mokhtari S. "Primary mandibular first molar with three reports". *Journal of Pakistan Oral Dental* 33 (2013): 74-75.
16. Badger GR. "Three rooted mandibular first primary molar". *Oral Surgery, Oral Medicine, Oral Pathology, and Oral Radiology* 53 (1982): 547.
17. Falk WV and Bowers DF. "Bilateral three rooted mandibular first primary molars: Report of case". *Journal of Dentistry for Children* 50 (1983): 136-137.
18. Reichart PA and Metah D. "Three-rooted permanent mandibular first molars in the Thai". *Community Dent Oral Epidemiol* 9 (1981): 191-192.
19. Curzon ME. "Miscegenation and the prevalence of three-rooted mandibular first molars in Baffin Eskimo". *Community Dent Oral Epidemiol* 2 (1974): 130-131.
20. Huang RY, et al. "Mandibular disto-lingual root: a consideration in periodontal therapy". *Journal of Periodontology* 78 (2007): 1485-1490.
21. Calberson FL, et al. "The radix entomolaris and paramolaris: clinical approach in endodontics". *Journal of Endodontics* 33 (2007): 58-63.
22. Goerig AC and Camp JH. "Root canal treatment in primary teeth: a review". *Pediatric Dentistry* 5 (1983): 33-37.
23. Gulabivala K, et al. "Root and canal morphology of Thai mandibular molars". *International Endodontic Journal* 35 (2002): 56-62.
24. Gulabivala K, et al. "Root and canal morphology of Burmese mandibular molars". *International Endodontic Journal* 34 (2001): 359-370.
25. Yew SC and Chan K. "A retrospective study of endodontically treated mandibular first molars in a Chinese population". *Journal of Endodontics* 19 (1993): 471-473.
26. Ferraz JA and Pecora JD. "Three rooted mandibular molars in patients of Mongolian, Caucasian and Negro origin". *Brazilian Dental Journal* 3 (1992): 113-117.
27. Loh HS. "Incidence and features of three-rooted permanent mandibular molars". *Australian Dental Journal* 35 (1990): 437-437.
28. Jones AW. "The incidence of the three-rooted lower first permanent molar in Malay people". *Singapore Dental Journal* 5 (1980): 15-17.
29. Hochstetter RL. "Incidence of trifurcated mandibular first permanent molars in the population of Guam". *Journal of Dental Research* 54 (1975): 1097.
30. Laband F. "Two years dental school work in British North Borneo: Relation of diet to dental caries among natives". *Journal of the American Dental Association* 28 (1941): 992-998.
31. Iwaka Y. "Three-dimensional observation of the pulp cavity of mandibular first molars by micro-CT". *Journal of Oral Biosciences* 48 (2006): 94-102.
32. Jung M, et al. "The imaging of root canal obturation using micro-CT". *International Endodontic Journal* 38 (2005): 617-626.
33. Mannocci F, et al. "The isthmuses of the mesial root of mandibular molars: A microcomputed tomographic study". *International Endodontic Journal* 38 (2005): 558-563.
34. Tu MG, et al. "Detection of permanent three-rooted mandibular first molars by cone-beam computed tomography imaging in Taiwanese individuals". *Journal of Endodontics* 35 (2009): 503-507.
35. Matherne RP, et al. "Use of conebeam computed tomography to identify root canal systems in vitro". *Journal of Endodontics* 34 (2008): 87-89.
36. Taylor C, et al. "Endodontic applications of cone-beam volumetric tomography". *Journal of Endodontics* 33 (2007): 1121-1132.
37. Song JS, et al. "The prevalence and morphologic classification of distolingual roots in the mandibular molars in a Korean population". *Journal of Endodontics* 36 (2010): 653- 657.

38. Tu MG., *et al.* "Prevalence of three-rooted primary mandibular first molars in Taiwan". *Journal of the Formosan Medical Association* 109 (2010): 69-74.
39. Sujatha. I., *et al.* "Prevalence of three rooted mandibular permanent first molars in a south Indian population-Radiovisio-graphic Evaluation". *American Overseas School of Rome* 2.1 (2012): 8-12.
40. Turp JC and Alt KW. "Anatomy and morphology of human teeth. In: Alt KW, Rosing FW, Teschler-Nicola M, eds. *Dental Anthropology. Fundamentals, Limits and Prospects*". Austria: Springer (1998): 71-94.
41. Norman W., *et al.* "Birooted primary canines: report of three cases". *Pediatric Dentistry* 18.4 (1996): 328-330.
42. Trope M., *et al.* "Mandibular premolars with more than one root canal in different race groups". *Journal of Endodontics* 12 (1986): 343-345.
43. Cleghorn BM., *et al.* "The root and root canal morphology of the human mandibular first premolar: a literature review". *Journal of Endodontics* 33 (2007): 509-516.
44. Nganba K., *et al.* Case Series of Three Rooted Primary Mandibular First Molars and Their Management 6.9 (2017).
45. De Moor RJG., *et al.* "The radix entomolaris in mandibular first molar: an endodontic challenge". *International Endodontic Journal* 37 (2004): 789-799.
46. Taylor AR. "Variations in the human tooth form as met with isolated teeth". *Journal Anatomy Physiology* 33 (1899): 268-272.
47. Campbell TD. "Dentition and the palate of the Australian Aboriginal". Adelaide: Keith Sheridan Foundation, Adelaide Publication 2 (1925).
48. Drennan MR. "The dentition of the Bushmen tribe". *Annals of South African Museum* 24 (1929): 61-87.
49. Shaw JC. "The teeth, the bony palate and the mandible in Bantu Races of South Africa". London, UK: John Bale, Sons and Danielson (1931).
50. Pedersen PO. "The East Greenland Eskimo dentition. Numerical variations and anatomy. A contribution to comparative ethnic odontography". *Copenhagen: Meddeleser om Gronland* (1949): 14-144.
51. Jorgensen KD. "The deciduous dentition. A descriptive and comparative anatomical study". *Acta Odontologica Scandinavica* 14 (1956): 1-202.
52. Skidmore AE and Bjorndahl AM. "Root canal morphology of the human mandibular first molar". *Oral Surgery, Oral Medicine, Oral Pathology* 32 (1971): 778-784.
53. Turner CG. "Three-rooted mandibular first permanent molars and the question of American Indian origins". *American Journal of Physical Anthropology* 34 (1971): 229-241.
54. Curzon ME and Curzon AJ. "Three-rooted mandibular molars in the Keewatin Eskimo". *Journal of the Canadian Dental Association* 37 (1971): 71-72.
55. Curzon ME. "Three-rooted mandibular permanent molars in English Caucasians". *Journal of Dental Research* 52 (1973): 181.
56. Sugiyama K., *et al.* "A study on the three roots in the mandibular first deciduous molar". *The Japanese Journal of Pediatric Dentistry* 14 (1976): 241-246.
57. Walker RT and Quackenbush LE. "Three-root lower first permanent molar in Hong-Kong Chinese". *British Dental Journal* 159 (1985): 298-299.
58. Walker RT. "Root form and canal anatomy of mandibular first molars in a southern Chinese population". *Dental Traumatology* 4 (1988): 19-22.
59. Harada Y., *et al.* "Frequency of three-rooted mandibular first molars. Survey of X-ray photographs". *Shika Kiso Igakkai Zasshi* 31 (1989): 13-18.
60. Younes SA., *et al.* "Three-rooted permanent mandibular first molars of Asian and black groups in the Middle East". *Oral Surgery, Oral Medicine, Oral Pathology* 69 (1990): 102-105.
61. Sperber GH and Moreau JL. "Study of the number of roots and canals in Senegalese first permanent mandibular molars". *International Endodontic Journal* 31 (1998): 112-116.
62. Song JS., *et al.* "Incidence and relationship of an additional root in the mandibular first permanent molar and primary molars". *Oral Surgery, Oral Medicine, Oral Pathology, and Oral Radiology* 107 (2009): e56-e60.
63. Schafer E., *et al.* "The prevalence of three-rooted mandibular permanent first molars in a German population". *Journal of Endodontics* 35 (2009): 202-205.

64. Tu MG., *et al.* "Prevalence of three-rooted primary mandibular first molars in Taiwan". *Journal of the Formosan Medical Association* 109 (2010): 69-74.
65. Garg AK., *et al.* "Prevalence of three-rooted mandibular permanent first molars among the Indian population". *Journal of Endodontics* 36 (2010):1302-1306.
66. Yang Y., *et al.* "Prevalence of 3-rooted first permanent molars among a Shanghai Chinese population". *Oral Surgery, Oral Medicine, Oral Pathology, and Oral Radiology* 110 (2010): e98-e100.
67. Peiris R., *et al.* "Root and canal morphology of permanent mandibular molars in Sri Lankan population". *Odontology* 95 (2007): 16-23.
68. Huang RY., *et al.* "Three-dimensional analysis of the root morphology of mandibular first molars with distolingual roots". *International Endodontic Journal* 43 (2010): 478-484.

Assets from publication with us

- Prompt Acknowledgement after receiving the article
- Thorough Double blinded peer review
- Rapid Publication
- Issue of Publication Certificate
- High visibility of your Published work

Website: www.actascientific.com/

Submit Article: www.actascientific.com/submission.php

Email us: editor@actascientific.com

Contact us: +91 9182824667