



Osteonecrosis of the Jaws Associated with the Use of Bisphosphonates in A Patient with Chronic Kidney Disease

Kaohana Thaís da Silva*, Larissa Nicole pasqualotto, Fabiana Seguin and Gadebayo Rabelo de Oliveira

Department of Odontology, Universidade Estadual Do Oeste Do Paraná, Brasil

***Corresponding Author:** Kaohana Thaís da Silva, Department of Odontology, Universidade Estadual Do Oeste Do Paraná, Brasil.

Received: August 27, 2019

Published: January 18, 2020

© All rights are reserved by **Kaohana Thaís da Silva, et al.**

Abstract

Bisphosphonates are synthetic substances of inorganic pyrophosphate that have been based on the treatment of patients with osteolytic diseases, such as multiple myeloma, malignant hypercalcemia, Paget's disease or patients with bone metastases. Its main pharmacological effect is the inhibition of bone resorption caused by osteoclasts, which have their function diminished. Its adverse effects are infrequent, but include pyrexia, kidney function problems, hypocalcemia and, more recently, Maxillomandibular osteonecrosis induced by bisphosphonates. This report describes a clinical case of mandibular osteonecrosis induced by bisphosphonates in a patient with chronic kidney disease and the Therapeutic protocol performed.

Keywords: Osteonecrosis of The Jaws; Bisphosphonates; Chronic Kidney Disease

Introduction

Bisphosphonates are synthetic substances of inorganic pyrophosphate, which resemble natural polyphosphates, have been based, over the last 3 decades, on the treatment of patients with osteolytic diseases, such as multiple myeloma, Malignant hypercalcemia, Paget's disease or patients with bone metastases [1].

The main pharmacological effect of bisphosphonates is the inhibition of bone resorption caused by osteoclasts, which have their function diminished. They also present other side effects, such as inhibition of calcification in the treatment of malignant hypercalcemia, prevention of osteoporosis and reduction of the inflammatory reaction of the joints in the treatment of arthritis [1]. The most potent, which contain nitrogen, are the N-BPs, represented by Aledronate, Ibandronate, Incadronate, Olpadronate, Pamidronate, Risedronate, and zoledronate, while non-N-BPs are mainly clodronate, Etidronate, and Tiludronate [2].

The anti-resorption properties of bisphosphonates increase approximately ten times between generations of the drug. Its adverse effects are infrequent, but include pyrexia, kidney function problems, hypocalcemia and, more recently, Maxillomandibular osteonecrosis induced by Bisphosphonates (OIB) [1-2].

The OIB is characterized by the inability of the bone tissue affected in repairing and remodeling in the face of inflammatory conditions triggered by mechanical stress (chewing), Exodontias, irritations by prosthetics or dental and periodontal infection, leading to Necrotic bone exposure in the Maxillo-Mandibular [3] region. They involve individualized, complex and dasafiadores treatments, requiring prolonged antibiotic therapy, CIRURGIAS4, hyperbaric oxygen Therapy, among other therapies, which may not result in cura [3-4].

The present study aims to explain a clinical case of mandibular osteonecrosis induced by bisphosphonates, in a patient with

chronic kidney disease, suggesting a therapeutic protocol and its implications.

Case Report

Patient E. C. B., 66 years old, genus Maculino, leucoderma, chronic kidney disease for 9 years, performs peritoneal dialysis three times a day; History of rheumatoid arthritis and fracture of the basin and acetabulum for 10 years, which included, in addition to rigid internal fixation, use of a drug based on a trihydrate sodium alendronate (Bonalen®), in the form of a 13.06 mg tablet once a week during the Period of 10 years, follows with great difficulty to walk, using wheel chair. He sought dental care at the Center for Odontological Specialties (CEO) of the State University of Western Paraná (UNIOESTE), due to the presence of intense pain in the right mandibular body, originating after the extraction of elements 47 and 48 performed 2 Months. The clinical examination showed, class II malocclusion, absence of several dental elements, in the region corresponding to the alveolus of the element 47 suppuration, bone exposure, erythematous edges in soft tissues and high sensitivity to touch. Panoramic radiography revealed poorly defined radiolucidal areas in the right mandibular body, with the alveoli corresponding to 47 and 48 radioluric, without the expected healing aspect for the period (Figure 1). The administration of Clindamycin 300mg of 8/8h and paracetamol 500mg of 6/6h orally was initiated, using chlorhexidine 0.12% for mouthwashes, as an auxiliary medium in oral hygiene and incisional biopsy of the lesion was performed under local anesthesia with lidocaine 2% with adrenaline 1:100,000. Histopathologic report revealed areas of bone necrosis with presence of inflammatory infiltrate.

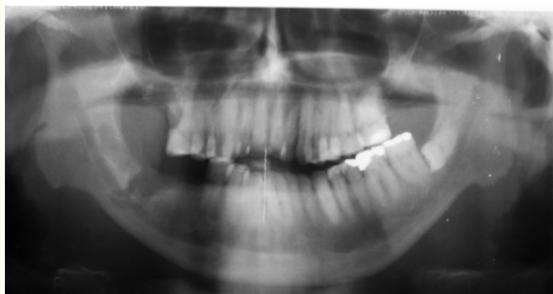


Figure 1: Panoramic radiograph showing diffuse radiolucent area, corresponding to the alveoli of elements 47 and 48, extracted 2 months ago, with no healing aspect compatible with the period.

The patient evolved with pathological fracture in the region 15 days after incisional biopsy (Figure 2), was hospitalized and after collection of laboratory exams (blood count, Coagulogram,

TGO/TGP, Glycemia, serum levels of urea, creatinine, potassium, phosphorus, Alkaline phosphatase, calcium and sodium) submitted to surgery for removal of necrotic tissue, corresponding to the region of elements 47 and 48, with approximately 1.5 cm and posterior rigid internal fixation with a reconstruction plate of the 2.4 mm system, performed by Submandibular intra-and extraoral access (Figure 3) under general anesthesia. He remained hospitalized for 7 days for hospital care and intravenous antibiotic therapy. It followed with the pre-stipulated medication, only with the increase of the dose of clindamycin to 600mg intravenous (iv) 6/6h, indication of tramal 100mg IV when severe pain. The Hydroelectrolytic replacement was based on 500mL of glycinate serum every 12h. A liquid and pasty diet was recommended and careful oral hygiene was performed.

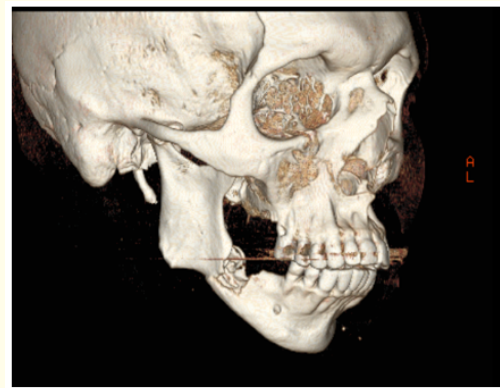


Figure 2: Tomography showing pathological fracture in the right mandibular body region.

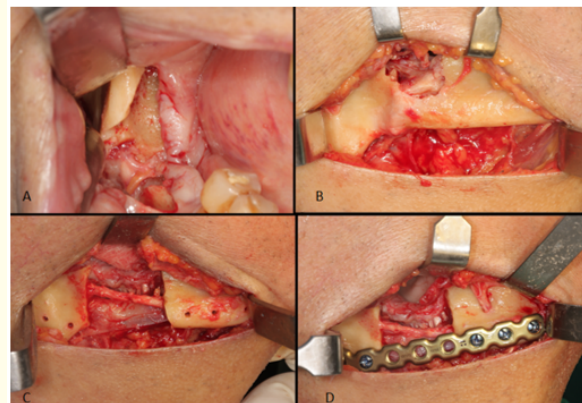


Figure 3: (A) Intraoral access, (B) Submandibular extraoral access, (C) Removal of necrotic bone tissue with preservation of the inferior alveolar nerve, (D) Rigid internal fixation using 2.4mm fixation system.

After hospital discharge, the patient followed a weekly outpatient follow-up, with significant improvement in complaints, tissue repair compatible with the postoperative period; 2 months later the region before with necrotic bone exposure was completely closed and without the presence of fistulas.

At 8 months postoperatively, no areas of bone exposure or function failure, associated complaints or radio/tomographic signs of new areas of OIB (Figure 4) were observed.

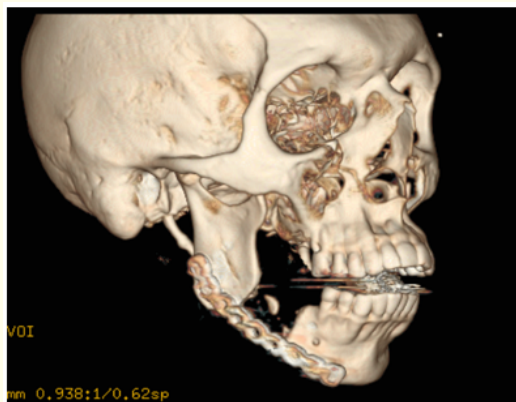


Figure 4: Tomography 8 months postoperatively, no evidence of new osteonecrosis areas.

Results and Discussion

Bisphosphonates reduce bone resorption in a dose-dependent manner, mainly by inhibitory recruitment and promoting apoptosis of osteoclasts. Recently, a strong relationship has been identified between the chronic use of these medications and the maxillomandibular osteonecrosis induced by bisphosphonates (OIB) 1-3. There are controversies regarding the pathogenesis of the disease. The higher concentration of bisphosphonates in the maxillary bones may be related to blood flow and greater bone turnover in these sites, which occurs by the presence of the teeth and periodontal ligament that require daily bone remodeling 4. However, there are assertions that the absorption of bisphosphonates is not increased in the jaws when compared to other ossos^{3, 5} and that the pathology occurs in the jaws due to the microbiota of the oral cavity, frequent exposures to the external environment resulting of dental surgical procedures, which make the region more susceptible to infections³, and resulting from

periodontitis and/or extensive carious lesions with endodontic involvement that create acidic environments in the oral cavity, since the Bisphosphonates are released on the bone surfaces in acidic pH, resulting in an increase in the LOCAL5 concentration.

The diagnosis of OIB is defined based on some particularities: current or anterior treatment with bisphosphonates, bone exposed in the Maxillo-mandibular region, which persisted for more than 8 weeks and absence of history of radiotherapy in the MAXILARES⁶.

The risk of developing OIB is not exclusive to patients receiving intravenous bisphosphonates (IV) ⁶. What is observed is that when the administration of bisphosphonates IV, zoledronate For example, the mean time of induction of osteonecrosis may be only 9 months, while in patients who use oral biphosphonates, such as alendronate, the mean is 30 - 52, months⁷. Therefore, the risk of osteonecrosis in patients who use oral bisphosphonates, more expressive in cases where the duration of treatment is greater than 3 YEARS⁶, data coincide with the case exposed.

The OIB, because it is a poorly known pathology, does not yet have treatment based on standardized orientations. The protocol is directed to each case, depending on the stage of the disease and the systemic condition of the affected patient. It should be directed towards elimination or control of pain, prevention of progression of the bone exposure area and removal of bony projections that cause inflammation of soft tissue and pain, in addition to closure by first intention of the alveoli after EXODONTIAS³. It has been proposed bone resections, debridement, antibiotic therapy, hyperbaric oxygen therapy, platelet-rich plasma, sequestrectomy, local irrigation with antimicrobial solutions, laser therapy, low doses of parathyroideo hormone (PTH) and OZONIOTERAPIA^{3, [5-6]}. The patient in the present report was treated with bone resection performed in low rotation under constant irrigation with 0.9% physiological saline, in order to avoid heating and increase in the area of bone necrosis; Debridement, manipulation and careful closure of soft tissues; and intravenous antibiotic therapy for 7 days followed by oral route for two months, rigorous oral hygiene and pasty diet.

The option to use rigid internal fixation of the 2.4 mm system should consider the presence of bone GAP after resection. In the present case, in addition to the loss of continuity of the bone tissue, the selection of the 2.4 mm system was made considering the impossibility of bone reconstruction with autogenous bone by

the related comorbidities. Such fixation system requires precise adaptation of the plate, with attention at the time of perforations, which should be performed under intense irrigation with 0.9% physiological saline, with subsequent installation of the screws with minimal stress. Occlusal Trauma should be checked and whenever possible corrected, so that there is a decrease in chewing overload at the site. In the present case report, it was not possible to perform occlusal adjustment, since the patient did not have the lower molars and had anterior open bite, the occlusion followed with touch basically in premolars figure.

Whenever the patient's systemic conditions allow to consider the interruption of oral bisphosphonates over a period of 3 months prior to oral surgery to decrease the risk of osteonecrosis, the use of the medicinal product should not be restarted Before bone healing has occurred [3-6]. This approach is based on reports from the literature demonstrating the relationship of osteoclasts activity with bisphosphonate administration and showed better treatment outcomes after drug discontinuation. The interruption of bisphosphonates IV does not offer any short-term benefits, however, if the patient's systemic conditions allow, long-term suspension may be beneficial in stabilizing osteonecrosis areas, reducing symptomatology and risk Development of OIB in new Locais [3].

In the case reported, the patient is suffering from chronic kidney disease (CKD). In the preoperative planning of such cases, the request for laboratory exams is of paramount importance. The knowledge of the plasma level of potassium is fundamental since hyperkalemia is the most severe and the most common metabolic alteration seen in the preoperative period of patients with CKD, and, when not diagnosed, constitutes one of the main causes of death in Transoperatory [8]. Sodium levels should be observed, since hyponatremia may mean dehydration with sodium loss or, more frequently, hyperhydration with excess water [8].

Often, such patients are anemic, requiring complete blood count to verify the degree of anemia and possible leukopenia because, malnutrition leads these patients to lymphopenia, reduction of neutrophilic activity and worsening of immunity Cellular by the deficiency of amino acids, vitamin B6 and Zinco [9]. The role of uremic toxins in the induction of leukocyte apoptosis has also been demonstrated. The granulocytes are deficient in various defense

functions, such as chemotaxis, phagocytosis, oxidative metabolism and degranulation. Peripheral mononuclear cells exhibit deficient phagocytosis and reduced cytokine production capacity, contributing to reduced humoral immunity, lower response to vaccines, reduced lymphocyte function and reduced production capacity of IMUNOGLOBULINAS [8-9].

Evaluation of the Bleeding Time (TS) is usually prolonged, although usually the platelet count, prothrombin time (TP) and partial thromboplastin time (TTP) have normal values. However, bleeding can be a significant problem, characterized by a tendency to prolonged hemorrhage and hematoma formation easily. Due to a qualitative and non-quantitative defect of platelets, leading to less formation of factor III with inhibition of platelet aggregation and alteration in the interaction of platelets with the endothelium of the vessels, whose cause seems to result from biochemical alterations Promoted by the URÊMICAS8-9 toxins.

It is also essential, together with laboratory monitoring, to select non-nephrotoxic drugs and, at the same time, to fulfill the required function. For local anesthesia, a preference should be given to lidocaine anesthetic, which is metabolized in the Figado9-10. In relation to general anesthesia, with the advent of new drugs that are not metabolized or excreted by the kidneys, there is tranquility in induction, being usually done through thionembutal, fentanyl as analgesic and atracurium as muscle relaxant, because it is Metabolized in plasma [10].

As for antibiotic medication, if preference to drugs with hepatic metabolism, such as amoxicillin, erythromycin, Clindamycin and metronidazole, being contraindicated Tetracylinicas and aminoglycosides. However, whenever possible, the nephrologist should be contacted for the adjustment and choice of medicamento [10].

Analgesics, such as paracetamol and acetylsalicylic acid, can be safely used in low to moderate doses, but use should be cautious when in higher doses. Nsaids should be avoided due to fluid and sodium retention in the presence of more severe circulatory alterations, and may lead to an exaggerated decline in renal function, since it presents nephrotoxicity and inhibits prostaglandins, since they have a role Preservation of hemodynamic Renal [10].

Conclusion

The lack of a protocol for the treatment of OIB, the presence of comorbidities and the need for manual resection using FIR from the 2.4 system make it complex to approach in the case described, requiring careful follow-up of the case. The reduction to the maximum of masticatory stress and immunocompetence also deserve attention, since they are important factors in decreasing the emergence of new complications.

Acknowledgements

None.

Conflict of Interest

None.

Bibliography

1. Schioldt M. "Management of Osteonecrosis of the Jaw in Patients Receiving Antiresorptive Treatment". In: The Duration and Safety of Osteoporosis Treatment. 3th ed. Springer International Publishing. 27 (2016): 193-202.
2. Yamamoto FP. "Study of the presence of osteonecrosis in the Madybula after molar extraction in rats treated with alendronate sodium [doctoral thesis]". São Paulo: University of São Paulo (2010).
3. Zanata A., et al. "Mandibular osteonecrosis associated with the use of sodium bisphosphonate in a patient with multiple myeloma". *Portuguese Journal of Dental Dentistry and maxillofacial Surgery* 55.2 (2014): 115-120.
4. Fede D., et al. "Osteonecrosis of the jaws in patients assuming oral bisphosphonates for osteoporosis: a retrospective multi-hospital-based study of 87 Italian cases". *European Journal of Internal Medicine* 24 (2013): 784-790.
5. Otto S., et al. "Bisphosphonate-related osteonecrosis of the jaw: is pH the missing part in the pathogenesis puzzle?" *Journal of Oral and Maxillofacial Surgery* 68.5 (2010):1158-1161.
6. Ruggiero SL., et al. "American Association of Oral and Maxillofacial Surgeons Position Paper on Bisphosphonate-Related Osteonecrosis of the Jaws - 2009". *Journal of Oral and Maxillofacial Surgery* 67.1 (2009): 2-12.
7. Assael LA. "Oral bisphosphonates as a cause of bisphosphonate-related osteonecrosis of the jaws: Clinical findings". *Journal of Oral and Maxillofacial Surgery* 67.1 (2009): 35-43.
8. Medeiros NH., et al. "Chronic renal failure and its interferences in dental care: literature review". *See dental Univ Cid São Paulo* 26.3 (2015): 24-28.
9. Costa-son JZC., et al. "Dental care in patients with chronic renal failure". *Rev Cir Traumatol Buco-Maxilo-FAC* 7.2 (2007): 19-28.
10. Chidambaram R. "Optimal antibiotic dosage for chronic kidney disease patient: a pharmacological manual for oral clinicians". *Recent patents on anti-infective drug Discovery* 10.2 (2015): 113-123.

Assets from publication with us

- Prompt Acknowledgement after receiving the article
- Thorough Double blinded peer review
- Rapid Publication
- Issue of Publication Certificate
- High visibility of your Published work

Website: www.actascientific.com/

Submit Article: www.actascientific.com/submission.php

Email us: editor@actascientific.com

Contact us: +91 9182824667