



## Immunoexpression of Matrix-Metalloproteinase-9 in Patients with Asymptomatic and Symptomatic Oral Lichen Planus – A Clinicopathological Study

Rohini Pandey<sup>1</sup>, Venkatesh Naikmasur<sup>2\*</sup> and Kaveri Hallikeri<sup>3</sup>

<sup>1</sup>Department of Oral Medicine and Radiology, SDM College of Dental Sciences and Hospital, Dharwad, India

<sup>2</sup>Professor, Vice Principal, Department of Oral Medicine and Radiology, SDM College of Dental Sciences and Hospital, A Constituent Unit of Shri Dharmasthala Manjunatheshwara University, Sattur, Dharwad, India

<sup>3</sup>Professor, Department of Oral and Maxillofacial Pathology, SDM College of Dental Sciences and Hospital, Dharwad, India

**\*Corresponding Author:** Venkatesh Naikmasur, Professor, Vice Principal, Department of Oral Medicine and Radiology, SDM College of Dental Sciences and Hospital, A Constituent Unit of Shri Dharmasthala Manjunatheshwara University, Sattur, Dharwad, India.

**E-Mail:** drvnmasur@gmail.com

**Received:** December 23, 2019

**Published:** December 31, 2019

© All rights are reserved by **Venkatesh Naikmasur, et al.**

### Abstract

**Background:** Oral lichen planus has been a mucosal disease of much enigma in speciality of oral medicine and pathology due to its intertwined pathophysiology, unidentifiable etiologic factors and absence of suitable management regimen to maintain its remission. Unfolding of pathologic progression in order to identify and further ameliorate the key process or etiology causing its manifestation. In the present study we used MMP-9 to get an insight of histopathological feature of both symptomatic and asymptomatic variant of OLP and compare their expression.

**Methodology:** Study consist of asymptomatic -Group-A (reticular) and symptomatic -group-B (atrophic, erosive) oral lichen planus. Following incisional biopsy paraffinized blocks were prepared. Tissue sections were stained with routine H and E and immunostain MMP-9. Immunopositive cells were counted in the epithelium and connective tissue at 40X magnification, mean was calculated. Pattern of expression and distribution of MMP-9 was evaluated.

**Results:** The age group ranged from 23 - 75 years of age with mean age of 45.70 years, with female predominance. The comparison of expression of MMP-9 in group A and B showed a significantly higher expression in Group B than group A. No significant relation of variant of OLP with any gender was detected. No significant difference elicited on noting the pattern of expression in variants of OLP. It was noted that erosive and atrophic forms of OLP has significantly higher MMP-9 expression than reticular OLP.

**Conclusion:** A statistically significant expression of MMP-9 in symptomatic variant of OLP was seen when compared to asymptomatic type, however no significance was seen in pattern of expression of MMP-9 in different cell layers of both variants of OLP.

**Keywords:** Atrophic; Erosive; MMP9; Oral Lichen Planus; Reticular; Symptomatic

### Introduction

Oral lichen planus (OLP) is a chronic inflammatory T cell mediated disease and one of the most discussed disease in the field of dentistry. A lot of research has been directed to understand its clinico-pathological mechanism and triggering factors associated with the auto-immune nature of the disease [1]. The prevalence of OLP is 0.22%-5% when studied among different group of population around the world; the incidence is 2.2% on an average [2].

The common age group of OLP involvement is 30-80 years with greater prevalence in females [3]. Clinical features of oral lichen

planus includes erythema, intersecting striations and is mostly symmetric, affecting buccal mucosa, gingiva and tongue. Erosive and atrophic type of lichen planus presents with symptoms like burning sensation, whereas reticular, and plaque type are asymptomatic [4].

Associated symptoms are characterized histologically by dense sub-epithelial lymphocytic infiltrate and epithelial basal cell destruction [1]. The normal integrity of basement membrane is maintained by living basal cell keratinocyte due to its secretion of collagen-4 and laminin 5 into epithelial basement membrane zone. In turn, keratinocyte require a basement membrane derived cell survival signal to prevent its apoptosis [3]. Apoptotic keratinocytes

are no longer able to perform this function which results in disruption of basement membrane as it cannot send the survival signal. This sets a vicious cycle which relates to the chronic nature of the disease [3]. The cytotoxic T cells further attack the basement membrane cells, signaling attraction of multiple inflammatory cytokines and enzymes at the site of action. As a result chemokines, mast cells and several matrix metalloproteinases are recruited at the site of lesion leading to further tissue breakdown and inflammation [4].

Matrix-metalloproteinases are set of Zn dependent protein digesting enzymes which perform several functions such as angiogenesis, cell migration, proteolytic activation of growth factors, tissue remodeling, wound healing and tumour invasion. Multiple studies have shown upregulation of MMP-2, MMP-3 and MMP-7 in oral lichen planus epithelium, MMP-9 along with its activators is also upregulated in OLP lesional T-cells resulting in basement membrane degeneration [5]. The magnitude of MMP-9 expression in tumor cells depicts its invasiveness, angiogenic and infiltrative nature. It has been studied that patients with elevated MMP-2 and MMP-9 expression had shorter disease free survival after treatment [5].

The increased matrix degradation will elevate inflammatory infiltrate concentrate in basement membrane thus increasing the local symptoms and discomfort associated with the condition [6].

Unlike other studies aimed at unfolding different aspects of etiopathogenesis of OLP. The present study is focusing on an insight to correlate the matrix degradation in oral lichen planus and its association with symptoms of oral lichen planus prevailing.

## Material and Methods

### Sample selection

The study consisted of group A 20 asymptomatic, group B consisted of 20 symptomatic cases of oral lichen planus and group C control tissue. All the cases of oral lichen planus were clinically diagnosed and confirmed histopathologic ally. Informed consent was taken from all the participants. Patients with chronic inflammatory disorders (eg: Rheumatoid arthritis, Systemic lupus erythematosus etc.), lactating mothers and pregnant females were not included in the study. The IHC procedure followed was based on instructions provided by Gene Pulse Scientific.

### Documentation of data

The clinical data was collected from the patient history and clinical examination. The clinical parameters evaluated were age, gender, site, symptoms associated, a range of symptoms were enquired which suggest the nature of the lesion manifestation, such as burning sensation while eating, taste deficit, difficulty in tongue movement, episodic occurrence.

## Immunohistochemical staining

### Interpretation of staining

The presence of brown colored end product at the site of target antigen was considered as positive immunoreactivity as appreciated in the positive control.

- Cell cytoplasm staining for MMP-9 was considered positive immunoreactions.

### Selection of field for counting cells

The sections were scanned under low power to determine the areas that were evenly stained. Representative fields were selected carefully in each slide by scanning the slides from left to right of every slide to avoid recounting of the same areas.

### Counting of cells

The counting was performed with a binocular light microscope under high power magnification (x40). The microscope was fitted with an eyepiece (x10) having an oculometer grid with 100 blocks (10x10), to count the cells proficiently and without bias. In each high power field, the cells in each block of the grid were counted as number of positive cells. A cell with cytoplasmic staining is accounted.

Two individual observers carried out all the observations to eliminate the interobserver bias. Kappa value for inter-observer reproducibility is 0.32 - 0.63.

In each slide cells were counted in step ladder pattern to avoid recounting of the same areas irrespective of number of fields.

Total number of cells were counted under four high power views (40X), and a mean is obtained. The pattern of staining was also assessed by noting the staining in layers of tissue specimen i.e epithelial and connective tissue layer. The distribution of staining uptake i.e focal and diffuse staining was assessed in each slide under high power view.

### Statistical analysis

The data were analyzed by means of IBM SPSS Statistics 20.0 software. The participants' demographic data i.e age, gender were analyzed on the basis of mean and standard deviation. Comparison of MMP-9 expression in the two groups of Oral lichen planus was performed by independent t-Test. Association between gender and variants of oral lichen planus were established on the basis of Chi-square test. Association between the pattern of MMP-9 expression in different cell layer and its distribution of staining pattern were ascertained with Chi-square test.

## Results

Group A is asymptomatic reticular form of oral lichen planus, and Group -B consisted symptomatic form either erosive or

atrophic oral lichen planus. Female predominance was noted in the gender wise distribution in both the groups, but statistical significant difference was not noted (Table 1). The participants belonged to the age group of 23-40 years, with a mean age of 45.70 yrs.

Group	Male	%	Female	%	Total
Group A (Asymptomatic)(Reticular 20 cases)	9	45.00	11	55.00	20
Group B (Symptomatic)Atrophic - 3 cases & Erosive- 17 cases	8	40.00	12	60.00	20
Total	17	42.50	23	57.50	40
Chi-square=0.1023 P = 0.7494					

**Table 1:** Comparison of gender wise distribution of population in groups A and B.

Higher expression of immunopositive cells were observed in the asymptomatic OLP compared to control group with high statistical significant difference (Table 2a).

Groups	N	Mean	SD	SE	t-value	P-value
Group C (Control)	5	10.6	3.26	1.45	-0.5205	*0.0268
A(Asymptomatic)	20	75.85	45.03	10.07		

**Table 2a:** Comparison of expression of MMP-9 immunopositive cells in control and asymptomatic group of oral lichen planus \*p<0.05.

Similarly highly significant difference in number of MMP-9 immunopositive cells was observed between the control and symptomatic group (Table 2b) and among group A and group B symptomatic cases had higher expression than asymptomatic OLP (Table 2c).

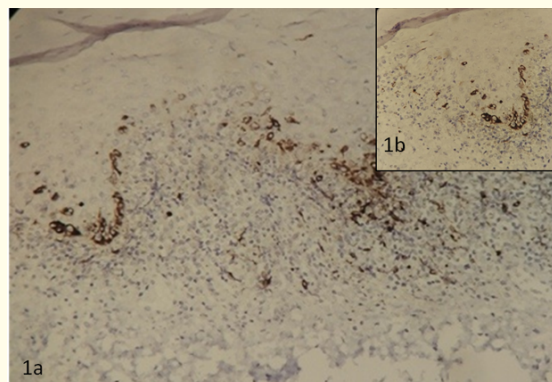
Groups	N	Mean	SD	SE	t-value	P-value
C (Control)	5	10.6	3.26	1.45	-2.609	*0.0153
B(Symptomatic)	20	104.08	35.44	7.92		

**Table 2b:** Comparison of expression of MMP-9 immunopositive cells in control and symptomatic group of oral lichen planus \*p<0.05.

Groups	N	Mean	SD	SE	t-value	P-value
A(Asymptomatic)	20	75.85	45.03	10.07	-2.2029	0.0337*
B(Symptomatic)	20	104.08	35.44	7.92		

**Table 2c:** Comparison of expression of MMP-9 immunopositive cells in asymptomatic and symptomatic oral lichen planus groups by independent t test \*p<0.05.

The MMP-9 expression was seen focally in the basal cell layer of the epithelium in both study (Figure 1a and 1b) and control group showed negative immunostain. Statistically significant difference was not seen between groups (Table 3).

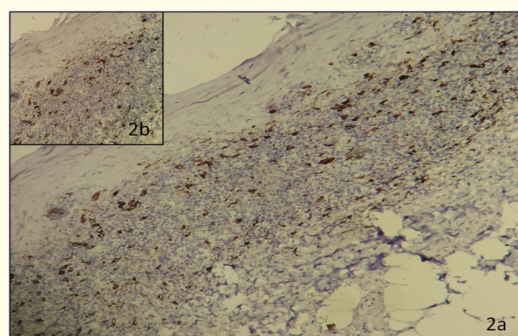


**Figure 1:** Photomicrograph of MMP9 immunohistochemical staining shows with intense cytoplasmic expression at the basal cell layer of epithelium 1a (20x) & insert 1b (40x).

Groups	Epithelium (location)		Distribution	
	Basal cells (%)	Suprabasal cells (%)	Focal (%)	Diffuse (%)
Group A	16 (80)	4 (20)	15 (75)	5 (25)
Group B	11 (55)	9 (45)	13 (65)	7(35)
Total	27 (67.50)	13 (32.50)	28 (70)	12(30)
Chi-square= 2.84 P = 0.0911			Chi-square= 0.4762 P = 0.4901	

**Table 3:** Comparison of location of staining of the two groups, in epithelial cell layer \*p<0.005.

In stroma, the lymphocytes showed positive staining with focal distribution than diffuse in both groups (Figure 2a and 2b). Statistical significant difference was not noted between the groups (Table 4).



**Figure 2:** Photomicrograph of MMP9 immunohistochemical staining shows with intense cytoplasmic expression in the connective tissue lymphocytes 2a (20x) & insert 2b (40x).

Symptomatic type lichen planus showed highest immunopositivity compared to asymptomatic lichen planus. Expression of MMP-9 immunopositive cells was assessed in the three clinical forms of oral lichen planus and compared by using Kruskal Wallis ANOVA test showed statistical significant difference between the groups (Table 5).

OLP-type	N	Mean	SD	SE	Sum of ranks
Reticular	20	63.36	20.83	4.66	257.00
Atrophic	3	113.17	31.42	18.14	86.00
Erosive	17	117.16	44.57	10.81	477.00
Total	40	89.96	42.47	6.72	
H-value	17.1386				
P-value	0.0002*				

**Table 5:** Comparison of MMP-9 expression in different forms of oral lichen planus by Kruskal Wallis ANOVA test \*p<0.005.

### Discussion

The pathogenesis of OLP involves multiple intermingled processes that include interaction between inflammatory cells, cytokines and chemokines. The end result is however apoptosis of basal cell keratinocytes. The stimulus for this entire pathophysiology is initiated by any allergen, systemic diseases, contact reaction etc. The etiology of genesis of OLP has a wide spectrum of agents ranging from genetic predisposition, environmental interactions or sporadic autoimmunity [7].

Epithelial lining of visceral body surfaces including oral cavity, serves as a second line of defense, preventing the invasion of foreign pathogens as well as providing a barrier against inner inflammatory processes to extend superficially, thus prolonging the time duration to allow the resolution of inflammation internally. This key process holds the control over unleash of symptoms of many diseases [6].

Extracellular proteolysis is one of the crucial events in any autoimmune or inflammatory disorder causing tissue injury. MMP are family of enzymes performing the principal function of extracellular matrix (ECM) degradation and proteolysis. There are 20 members in this family of zinc dependent endopeptidases. All these MMPs share a common biochemical property but have different substrate specificity, making them unique in their action. The family consists of two subgroups of MMPs based on their characteristic action. The gelatinase or collagenase (eg: MMP-2, MMP-9) cleaves collagen IV, and stromelysins (MMP-3, MMP-10) which cleaves collagen IV and laminin [8].

MMP have long been identified as enzymes playing a causal role in extracellular matrix degradation and have been studied in

several diseases to understand their pathophysiologic role. The more the ECM and basement membrane degradation more will be the streaming of inflammatory infiltrate and symptoms associated [9].

Many researchers have employed several techniques to measure levels of MMP expression, which includes methods such as ELISA, real time PCR, zymography, flow cytometry and immunohistochemistry can be used in local lesional tissue staining with respective MMP antibody. [8]. The gelatinolytic activity of MMPs were studied and investigated initially in tumorigenesis and invasiveness of oral squamous cell carcinoma. Histopathologic ally highly invasive cases of squamous cell carcinoma has shown high levels of MMP-2 and MMP-9 in serum levels [9,10].

MMPs have a crucial role in cell regulation. Its offset can cause molecular shedding and lead to processesing of bioactive molecules such as cell surface receptors, defensins, cytokines, chemokines, adhesion molecules and growth factors. The role of MMPs in tissue degenerative diseases had concentrated attempts to pharmacologically control its up regulation and abstain it's activation cascades [11].

In this study we chose a collagenase i.e MMP-9 to estimate the potential tissue changes and it's correlation with asymptomatic and symptomatic variants of OLP. Immunohistochemistry was used to stain the lesional tissue and obtain MMP-9 expression level and pattern. Each variant group of OLP had 20 subjects. The participants in our study belonged to the age range of 23 - 75 years. The maximum number of participants belonged to the age group of 23 - 40 years. As mentioned by Scully, et al. the lichen planus is reported in middle aged individuals of age group 30 - 60 years, and rarely involve the pediatric population [12]. All the participants in our study as well belonged to the adult population with minimum age of 23 years and an average age of 45.70 years indicating the similar age predisposition as mentioned by Scully, et al [12].

Amongst the total participants, 17 were male and 23 were female. A higher number of female subjects support the sexual predilection of the disease towards females. Studies conducted by Eisen D to understand the clinical features, malignant potential and systemic associations of OLP conducted amongst 723 patients had 64.9% of female participation [13]. A retrospective study conducted by Pakfetrat, et al. in 420 Iranian patients with OLP confirms the finding with 1.6 times more female subjects than male [14].

The MMP-9 expression level was analysed in the control group and both study groups. The control group showed a range of 6 - 15 immunopositive cells and a mean of 10.6 immunopositive cells. The MMP-9 immunopositive cells ranged from 34.5-95.5 cells in group A, the asymptomatic OLP group, with mean number

of immunopositive cells being 75.85. The expression level was considerably higher in Group B consisting of symptomatic OLP with range of immunopositive cells being 33.25 -240.50 and mean immunopositive cells of 104.08. Presentation of symptoms are strongly associated with inflammatory infiltrate. Cultured supernatant of OLP lesional T cells as well as peripheral T cells in OLP patients contained higher MMP-9 levels than those in healthy controls, thus justifying the remarkably higher immunoexpression of MMP-9 in both studies groups than control group [15].

On exposure to any exogenous allergen or antigen, there is activation of mast cells and Langerhans antigen presenting cells, which initiate the local immune response and cytokine release. The degranulation of mast cells is thus stimulated by cytokines (TNF- $\alpha$ ) which causes expression of endothelial leucocyte adhesion molecule and intercellular adhesion molecule (ICAM), these agents further facilitate lymphocyte migration releasing chymases and MMP expression in lesional tissue [7,16]. The comparison of expression of MMP-9 immunopositivity indicates significantly higher expression in symptomatic OLP than asymptomatic.

A study conducted by Mazarella, et al. in 2005, to assess the level of MMPs in two clinical forms of oral lichen planus (erosive and reticular), showed strong MMP-3 and MMP-9 expression in erosive oral lichen planus, suggesting basement membrane disruption and contribution of these MMPs in flow of inflammatory infiltrate through breaching basement membrane and in turn release of several factors amplifying inflammatory reaction. Thus an increase in symptomatic and inflammatory activity can be positively correlated with higher MMP-9 expression. The findings of this study holds true with results obtained in our study, proving role of MMP-9 in exaggeration of the inflammatory responses in symptomatic OLP [1].

We also analyzed the MMP-9 expression pattern in different cellular layer of OLP lesional tissue. The control group showed no immunopositive cells in epithelial layer. However in the study groups, it was observed that the maximum immunopositivity is seen in basal cell layer of epithelium, suggesting the upregulated activity of MMP-9 in basement membrane disruption and basal cell apoptosis. These findings were consistent with the results obtained in a study done by Zhou, et al. 2001 aimed to understand the role of MMPs and their inhibitors in pathogenesis of OLP where in, they state that apoptotic basal cells and rete-ridges of epithelium showed a positive immunostaining for MMP-9 and MMP-2 [8].

It has been suggested by several models that T-lymphocytes which mainly secrete MMP-9 are able to cross the basement membrane and causes the prodestructive activity, MMP-9 was thus identified in the inflammatory infiltrate in lamina propria with predominant positivity in lymphocytes [17]. In our study as well

lymphocytes are the only cell in connective tissue which acquired the MMP-9 immunostaining in both variants of OLP indicating the lymphocytes as the chief source of MMP-9.

No absolute remark can be made on the distribution pattern of MMP-9 expression in both OLP variants, as they showed a non-significant difference in distribution pattern, also not much literature is available on assessment of distribution characteristics of MMPs in OLP.

Three clinical forms of OLP were mainly observed in the participants included in the asymptomatic and symptomatic variants of OLP. Reticular form was present in asymptomatic variant and atrophic and erosive forms were present in symptomatic group of OLP. It was found that the MMP-9 expression in atrophic and erosive forms were markedly higher than reticular forms. A study conducted by Mazarella, et al. to evaluate the MMP expression in reticular and erosive forms of OLP, found that increased MMP-3 and MMP-9 expression in erosive OLP, suggested cooperation of epithelial cells and lymphocytes in BM disruption. MMP-9 which is mainly secreted by lymphocytes release additional factors that amplify inflammation, MMP-3 conjugates MMP-9 production and activation. The degraded basement membrane produces MMP-1 and MMP-3 amplifying MMP-9 activity. This cascade enhances inflammation, contributing to erosions. This quantifies the inflammatory load of erosive and atrophic OLP [1].

ECM degradation was higher in symptomatic variant of OLP compared to asymptomatic variants of OLP, also immunopositive cells are seen noticeably higher in basal cell layer with diffuse pattern in connective tissue cells (i.e lymphocytes) leading to basement membrane disruption and apoptosis of basal cells leading to clinical manifestation of atrophic and erosive forms of OLP. Both basal cells of epithelium and lymphocytes play a role in synthesis and mediation of MMP-9. T-cell lymphocytes and keratinocytes derived MMP-9 play a key role in pathogenesis if OLP, therefore novel therapies should be directed to block the MMP-9 activity thus controlling pregression of OLP [18,19].

Even though we were able to assess partially the inflammatory activity in asymptomatic and symptomatic variants of OLP in our study through MMP-9 expression, the activities and regulation of MMP cannot be assessed without understanding the function of their inhibitory proteins which are tissue inhibitors of matrix metalloproteinase (TIMPs). Most commonly known TIMPs are TIMP-1, TIMP-2 and TIMP-3. In a study by Rubaci, et al. it was observed that the MMP-2/TIMP-1 and MMP-7/TIMP-1 ratios were higher in OLP patients than control groups. These results suggested that the increased MMP expression and imbalance of MMP/TIMP ratio play a pivotal role in pathogenesis of OLP. Disruption of MMP and TIMP balance is the factor which also determines the malignant

potential of OLP [20]. MMP/TIMP disturbances has been associated with serious disease such as arthritis, tumor growth and metastasis (Bode., *et al.* Insights into MMP-TIMP interactions) [21]. Future studies should involve assessment of multiple MMPs and their inhibitory protein action in OLP and compare it with moderately to severely dysplastic lesions to produce more adequate data.

In future, studies should be proposed with sufficient sample size to evaluate the variation of MMP-9 activity and ECM degradation in different gender and age groups. Studies with larger and equal sample size should be conducted in different variants and forms of OLP, to know whether the proteolytic activity increases or decreases on the basis of ascending age or in specific gender, when a particular variant or form of OLP is taken into consideration.

### Conclusion

MMP 9 is one of the major inflammatory enzyme causes degradation of basement membrane in lichen planus. MMP 9 expression is significantly increased and is well correlated with clinical manifestation of lichen planus. MMPs expression is stimulated by inflammatory cytokines, hormones, and growth factors. If these stimulators are treated the lichen planus will heal successfully. MMP inhibitors can be part treatment in lichen planus.

### Conflict of Interest

None.

### Bibliography

1. Mazzarella N., *et al.* "Matrix metalloproteinase gene expression in oral lichen planus: erosive vs. reticular forms". *The Journal of the European Academy of Dermatology and Venereology* 20.8 (2006): 953-957.
2. MD Mignogna., *et al.* "Clinical guidelines in early detection of oral squamous cell carcinoma arising in oral lichen planus: a 5-year experience". *Journal of Oral Oncology* 37.3 (2001): 262-267.
3. Paulusová V., *et al.* "Expression of matrix metalloproteinase 9 in patients with oral lichen planus". *Acta Medica (Hradec Kralove)* 55.1 (2012): 23-26.
4. Sutinen M., *et al.* "Expression of matrix metalloproteinases (MMP-1 and -2) and their inhibitors (TIMP-1, -2 and -3) in oral lichen planus, dysplasia, squamous cell carcinoma and lymph node metastasis". *British Journal of Cancer* 77 (1998): 2239-2243.
5. Ertugrul AS., *et al.* "MMP-1, MMP-9, and TIMP-1 levels in oral lichen planus patients with gingivitis or periodontitis". *Archives of Oral Biology* 58.7 (2013): 843-852.
6. Li TJ., *et al.* "MMP-7 expression in oral lichen planus and oral squamous cell carcinoma". *Asian Pacific Journal of Tropical Medicine* 6.8 (2013): 640-643.
7. Sugerman PB., *et al.* "Oral lichen planus". *Clinics in Dermatology* 18 (2000): 533-539.
8. Zhou XJ., *et al.* "Matrix metalloproteinases and their inhibitors in oral lichen planus". *Journal of Cutaneous Pathology* 28.2 (2001): 72-82.
9. Kubota T., *et al.* "Expression of mRNA for matrix metalloproteinases and tissue inhibitors of metalloproteinases in periodontitis-affected human gingival tissue". *Archives of Oral Biology* 41.3 (1996): 253-262.
10. Ikebe T., *et al.* "Gelatinolytic activity of matrix metalloproteinase in tumor tissues correlates with the invasiveness of oral cancer". *Clinical and Experimental Metastasis* 17.4 (1999): 315-322.
11. Impola U., *et al.* "Differential expression of matrilysin-1 (MMP-7), 92 kD gelatinase (MMP-9), and metalloelastase (MMP-12) in oral verrucous and squamous cell cancer". *The Journal of pathology* 202.1 (2004): 14-22.
12. Scully C., *et al.* "Update on oral lichen planus: Etiopathogenesis and management". *Critical Reviews in Oral Biology and Medicine* 9.1 (1998): 86-122.
13. Eisen D. "The clinical features, malignant transformation and systemic associations of oral lichen planus: a study of 723 patients". *Journal of the American Academy of Dermatology* 46.2 (2002): 207-214.
14. Pakfetrat A., *et al.* "Oral lichen planus: a retrospective study of 420 Iranian patients". *Medicina Oral Patologia Oral y Cirugia Bucal* 14.7 (2009): e315-e318.
15. Roopashree MR., *et al.* "Pathogenesis of oral lichen planus - a review". *Journal of Oral Pathology and Medicine* 39.10 (2010): 729-734.
16. Ismail SB., *et al.* "Oral lichen planus and lichenoid reactions: etiopathogenesis, diagnosis, management and malignant transformation". *Journal of Oral Science* 49.2 (2007): 89-106.
17. GA Rosenberg. "Matrix metalloproteinases in neuroinflammation". *Glia* 39.3 (2002): 279-291.
18. Mona El-Sayed and Howyda Mohamed Ebrahim. "Are tumor necrosis factor- $\alpha$  and matrix metalloproteinase-9 able to induce basal cell degeneration and enhance tissue destruction in cutaneous lichen planus?" *Egyptian Journal of Pathology* 36.2 (2016): 170-177.

19. Paulusová V, *et al.* "Expression of matrix metalloproteinase 9 in patients with oral lichen planus". *Acta Medica (Hradec Kralove)* 55.1 (2012): 23-26.
20. Rubaci AH, *et al.* "The roles of matrix metalloproteinases-2, -7, -10 and tissue inhibitor of metalloproteinase-1 in the pathogenesis of oral lichen planus". *Journal of Oral Pathology and Medicine* 41.9 (2012): 689-696.
21. Bode W and K Maskos. "Structural basis of the matrix metalloproteinases and their physiological inhibitors, the tissue inhibitors of metalloproteinases". *Journal of Biological Chemistry* 384.6 (2003): 863-872.

#### **Assets from publication with us**

- Prompt Acknowledgement after receiving the article
- Thorough Double blinded peer review
- Rapid Publication
- Issue of Publication Certificate
- High visibility of your Published work

**Website:** <https://www.actascientific.com/>

**Submit Article:** <https://www.actascientific.com/submission.php>

**Email us:** [editor@actascientific.com](mailto:editor@actascientific.com)

**Contact us:** +91 9182824667