



## Extensive Periapical Radiolucency Follow-Up Through Periapical Radiography and Computerized Cone Beam Tomography – Case Report

Mario Leonardi<sup>1\*</sup>, Carolina Siqueira<sup>2</sup>, Cícero Lucas Ramalho<sup>3</sup>,  
Caio Vinícius Teixeira<sup>3</sup> and Iwna Marli Pereira<sup>4</sup>

<sup>1</sup>D.D.S., Master's degree in Endodontics by Dentistry Faculty of University of São Paulo -- FOUSP, São Paulo, SP

<sup>2</sup>D.D.S., Specialization student in Endodontics at Núcleo de Estudos e Aperfeiçoamento Odontológico, João Pessoa, Paraíba

<sup>3</sup>D.D.S., Specialization student in Endodontics at Centro Caririense de Pós-graduação, Juazeiro do Norte, Ceará

<sup>4</sup>Dentistry Student at Centro Universitário Dr. Leão Sampaio – UNILEÃO, Juazeiro do Norte, Ceará

**\*Corresponding Author:** Mario Leonardi, D.D.S., Master's degree in Endodontics by Dentistry Faculty of University of São Paulo -- FOUSP, São Paulo, SP.

**Received:** December 23, 2019

**Published:** January 07, 2020

© All rights are reserved by **Mario**

**Leonardi, et al.**

### Abstract

Endodontic treatment has become faster and safer with the development of technologies, allowing effective procedures and greater comfort for both the professional and the patient. The use of Cone Beam Computerized Tomography (CBCT) has brought benefits for the pre, trans and post-operative phases, making it a great tool to evaluate treatment evolution. This study emphasized the follow-up of an extensive periapical radiolucency case, through periapical radiographs and tomographic examinations in 30 days, 150 days and one-year time lapse. The equipment and materials applied made it possible to perform the treatment efficiently. In the 1-year postoperative period, signs of periapical radiolucency repair, bone neoformation and absence of CBCT-proven symptoms were radiographically shown, indicating the success of the proposed therapy.

**Keywords:** Cone Beam Computed Tomography; Endodontics; Diagnosis; Dental Radiography; Root Canal Therapy

### Abbreviations

CBCT: Cone Beam Computerized Tomography; APA: Acute Periapical Abscess; EDTA: Ethylenediamine Tetraacetic Acid; CPMC: Camphorated Paramonochlorophenol; AP – Apical Periodontitis; DPR- Digital Periapical Radiography; CT – Computerized Tomography; TR – Traditional Radiographs.

### Introduction

Radiographic examination is the most commonly used research method in dental practice for the evaluation of dental lesions [1]. However, intraoral images of periapical radiographs have

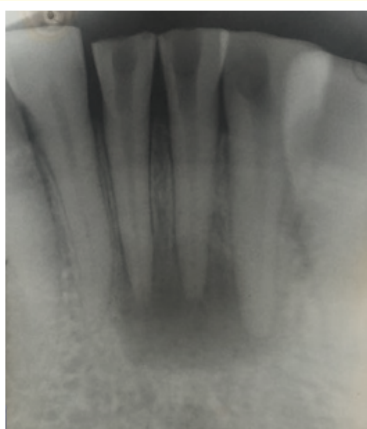
some limitations due to their two-dimensional view, restricting information about the location, size and extension of these lesions [2].

Cone Beam Computed Tomography (CBCT) has been considered the gold standard in endodontics through the construction of three-dimensional images, bringing benefits in the diagnosis, planning and follow-up of cases [3,4]. Because of its higher sensitivity, this exam provides high resolution images and more accurate information for detecting periapical radiolucency when compared to other radiographic examinations [5].

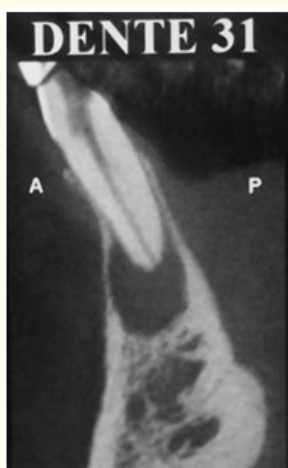
The aim of this paper is to report the clinical case of a patient who presented extensive periapical radiolucency and long-term success of endodontic treatment, controlled through the use of radiographic and tomographic examinations to preserve the clinical results.

**Case presentation**

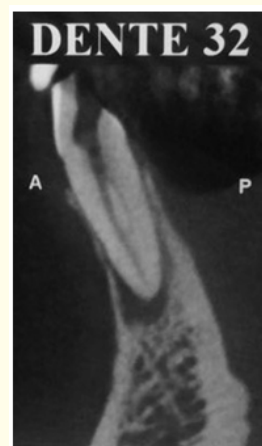A 55-year-old norm systemic male patient, leukoderma, referred to the CECAPE University clinic, in the endodontics specialization department, with the initial complaint of “bad taste in the mouth” and increased volume in the periapical region of the buccal mucosa of teeth 31, 32 and 41. On clinical examination, these elements showed negative pulp sensitivity response to cold test and presence of painful symptoms on palpation and vertical and horizontal percussion. Radiographically, extensive periapical radiolucency was observed, suggestive of acute periapical abscess (APA) (Figure 1). To complement the anamnesis and ensure an effective follow-up of the case, a CBCT was requested (Figure 2 to 5).



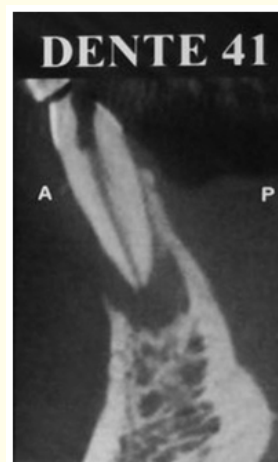**Figure 1:** Periapical radiography showing extensive radiolucid image between elements 31, 32 and 41.



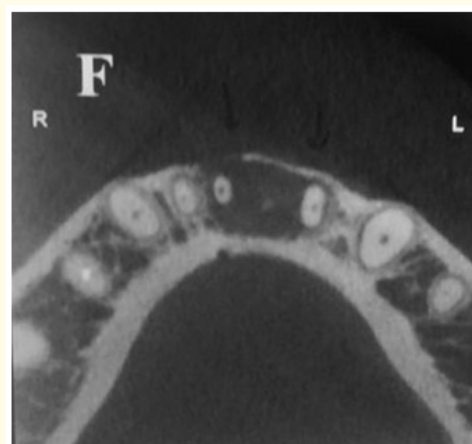
**Figure 2:** Specific CBCT slice (transaxial), radiolucid image in element 31 apical region.



**Figure 3:** Specific CBCT slice (transaxial), radiolucid image in element 32 apical region.

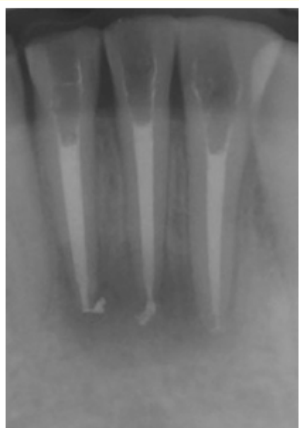


**Figure 4:** Specific CBCT slice (transaxial), radiolucid image in element 41 apical region.




**Figure 5:** Axial CBCT slice, diffuse radiolucid image between elements 31, 32 and 41.

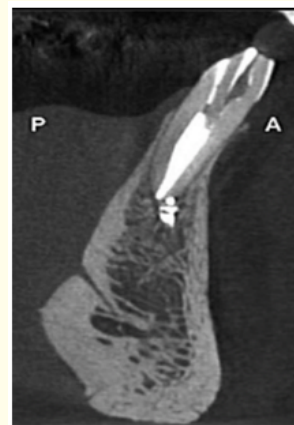
After clinical, radiographic and tomographic analysis, endodontic treatment of the three elements was proposed. Through CBCT it was also verified the presence of two root canals in each tooth. Access surgery and foraminal debridement were performed, using K #10 files and #15, followed by instrumentation with Reciproc R25 and R40 files in the buccal and lingual canals, respectively. After that, treatment continued with passive ultrasonic irrigation with sodium hypochlorite at 2.5% associated with 17% EDTA. The canals were filled with calcium hydroxide paste associated with camphorated paramonochlorophenol (Calen CPMC), ultrasound activated. Finally, the teeth were endodontically filled after 14 days with R40 cones and AH Plus sealer, using the continuous wave condensation technique. The postoperative period was satisfactory with total regression of signs and symptoms, observing the evolution of repair compatible with normality patterns. Clinical follow-up was performed for 30 (Figure 6), 150 days (Figure 7) and 01 year (Figures 8 to 11). After this period, periapical radiolucency repair, bone neof ormation and absence of CBCT-proven symptoms could be observed.



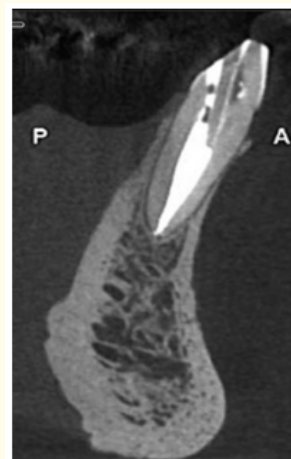
**Figure 6:** Follow-up periapical radiograph taken after 30 days.



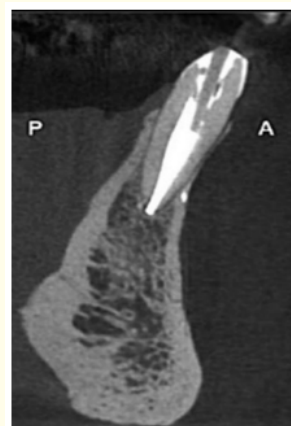
**Figure 7:** Follow-up periapical radiograph taken after 150 days.



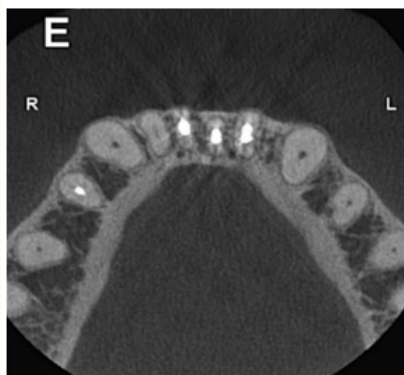**Figure 8:** Specific CBCT slice (transaxial), one-year follow-up and bone repair in element 31 apical region.



**Figure 9:** Specific CBCT slice (transaxial), one-year follow-up and bone repair in element 32 apical region.



**Figure 10:** Specific CBCT slice (transaxial), one-year follow-up and bone repair in element 41 apical region.



**Figure 11:** Axial CBCT slice, one year follow-up and bone repair between elements 31, 32 and 41.

## Discussion

Cone Beam Computerized Tomography is a three-dimensional imaging system that allows radiographic evaluation of dentoalveolar anatomy in orthogonal planes [6]. It was introduced in the field of endodontics in order to provide greater precision and reliability in the analysis of risk variables associated with root canal treatment prognosis [7].

The prognosis is the estimated progress of a disease [8]. In the context of Apical Periodontitis (AP), this term applies to both the course of time and the chances of cure. Thus, the main objective of evaluating outcomes after root canal treatment in teeth with pre-therapeutic apical pathology should be to monitor the healing or persistence of AP through the assessment of periapical state [9].

Some authors have emphasized that clinical and radiographic follow-up should be performed at regular intervals for a minimum observation period of one year [10]. However, bearing in mind that periapical lesions may remain the same size or only decrease in size, and also that a favourable outcome may be reversed if infection or reinfection occurs, it is advisable to further evaluate the lesion until it is resolved, over a four-year period [9].

Considering the limitations of radiographic examination [11], CBCT assessment may reveal additional prognostic factors [8,12]. The healing results based on clinical findings and compared with images obtained from Digital Periapical Radiography (DPR) and CBCT, led to the detection of a greater number of periapical

radiolucency than those observed in RPD examinations, confirming the effectiveness of CBCT in follow-up. and prognosis of the APA [13].

Compared with periapical radiographs, CBCT is more accurate in detecting periapical radiolucency and endodontic technical errors. In contrast, more recent data using an ex vivo approach suggested that the diagnosis of APA using CBCT is less accurate [14].

Therefore, the advantages of CBCT over traditional radiographs (TR) and computerized tomography (CT) scans and radiographs should be noted: higher accuracy and higher resolution of CBCT, when compared to TR, shorter scanning time and reduced radiation doses, when compared to CT [11]. Regarding the disadvantages one can mention the high cost, shortage of clinical trials proving diagnostic accuracy and a potentially higher radiation dose, in contrast to TR [15].

## Conclusion

At 1-year follow-up, radiographic findings of periapical radiolucency repair, bone neoformation, and absence of CBCT-proven symptomatology were found. Thus, highlighting the importance of radiography and tomography for the control and follow-up of the patient's clinical condition, demonstrating that the proposed treatment was effective and indicating success of the proposed therapy.

## Bibliography

1. Mupparapu M, *et al.* "Differential Diagnosis of Periapical Radiopacities and Radiolucencies". *Dental Clinics of North America* 64.1 (2019): 163-189.
2. Velvart P, *et al.* "Detection of the apical lesion and the mandibular canal in conventional radiography and computed tomography". *Oral Surgery, Oral Medicine, Oral Pathology, and Oral Radiology* 92.6 (2001): 682-688.
3. Patel S. "New dimensions in endodontic imaging: Part 2. Cone beam computed tomograph". *International Endodontic Journal* 42.6 (2009): 463-475.
4. Tyndall DA and Kohltfarber H. "Application of cone beam volumetric tomography in endodontics". *Australian Dental Journal* 1 (2012): 72-81.
5. Perlea P, *et al.* "Pós-treatment periapical periodontitis x-ray versus CBCT- a case report". *Journal of Medicine and Life* 9.1 (2016): 84-87.

6. Kanagasigam S., *et al.* "Diagnostic accuracy of periapical radiography and cone beam computed tomography in detecting apical periodontitis using histopathological findings as a reference standard". *International Endodontic Journal* 50.5 (2017): 417-426.
7. Restrepo-Restrepo FA., *et al.* "Prognosis of root canal treatment in teeth with preoperative apical periodontitis: a study with cone-beam computed tomography and digital periapical radiography". *International Endodontic Journal* 52.11 (2019): 1533- 1546.
8. Liang YH., *et al.* "Endodontic outcome predictors identified with periapical radiographs and cone-beam computed tomography scans". *Journal of Endodontics* 37.3 (2011): 326-331.
9. European Society of Endodontology. "Quality guidelines for endodontic treatment: consensus report of the European Society of Endodontology". *International Endodontic Journal* 39.12 (2006): 921-930.
10. Nascimento EHL., *et al.* "Prevalence of technical errors and periapical lesions in a sample of endodontically treated teeth: a CBCT analysis". *Clinical Oral Investigations* 22.7 (2018): 2495-2503.
11. Patel S., *et al.* "The detection of periapical pathosis using digital periapical radiography and cone beam computed tomography - part 2: a 1-year post-treatment follow-up". *International Endodontic Journal* 45.8 (2012): 711-723.
12. Fernandez R., *et al.* "Impact of three radiographic methods in the outcome of nonsurgical endodontic treatment: a five-year follow-up". *Journal of Endodontics* 39.9 (2013): 1097-1103.
13. Ricucci D., *et al.* "A prospective cohort study of endodontic treatments of 1,369 root canals: results after 5 years". *Oral Surgery, Oral Medicine, Oral Pathology, Oral Radiology and Endodontics* 112.6 (2011): 825-842.
14. Kruse C., *et al.* "Diagnostic accuracy of cone beam computed tomography used for assessment of apical periodontitis: an ex vivo histopathological study on human cadavers". *International Endodontic Journal* 52.4 (2019): 439-450.
15. Petersson A., *et al.* "Radiological diagnosis of periapical bone tissue lesions in endodontics: a systematic review". *International Endodontic Journal* 45.9 (2012): 783- 801.

#### Assets from publication with us

- Prompt Acknowledgement after receiving the article
- Thorough Double blinded peer review
- Rapid Publication
- Issue of Publication Certificate
- High visibility of your Published work

**Website:** [www.actascientific.com/](http://www.actascientific.com/)

**Submit Article:** [www.actascientific.com/submission.php](http://www.actascientific.com/submission.php)

**Email us:** [editor@actascientific.com](mailto:editor@actascientific.com)

**Contact us:** +91 9182824667