

## Buccinator Myomucosal Flap for Reconstruction of Retromolar Trigone Defect Due to Squamous Cell Carcinoma

Otto Alemán Miranda\*, José Luis Martínez Montes de Oca, Alina Betancourt Betancourt, Griselda Navarro Figueredo and Lianet Camila Menéndez Martínez

Private Practice, USA

\*Corresponding Author: Otto Alemán Miranda, private practice, USA.

Received: April 16, 2025

Published: April 23, 2025

© All rights are reserved by

Otto Alemán Miranda., et al.

### Abstract

Squamous cell carcinoma (SCC) of the oral cavity is a frequent malignancy with increasing global incidence. Among its sub-sites, the retromolar trigone poses unique surgical and reconstructive challenges due to its anatomical complexity and proximity to critical structures. The buccinator myomucosal flap (BMF) has emerged as a reliable reconstructive option for moderate intraoral defects. This article reviews the etiology, clinical behavior, and management of oral SCC with a focus on retromolar trigone tumors. It further highlights the anatomical features, technical variants, and clinical applications of the BMF in oral cavity reconstruction, emphasizing its utility in restoring both function and aesthetics with minimal donor site morbidity.

**Keywords:** Buccinator Myomucosal; Reconstruction; Retromolar; Trigone; Squamous Cell Carcinoma

### Introduction

Squamous cell carcinoma (SCC) is the most common malignant neoplasm of the oral cavity [1]. The most significant etiological factors include tobacco use, alcohol, cannabis, changes in local immunology, genetic alterations (such as p53 mutations), and infection by oncogenic viruses, particularly human papillomavirus (HPV 16 and 18) [2,3]. In recent years, there has been an increase in the incidence of this tumor, currently ranking sixth among all malignant neoplasms [4]. Although it has traditionally been more common in middle-aged male smokers and drinkers, its presentation in young non-smoking women has also increased, particularly in relation to HPV [5].

Treatment of oral cavity squamous cell carcinoma (OCSCC) is complex and must be individualized based on patient and tumor characteristics. Surgical staging, including neck dissection, is essential for proper diagnosis and prognosis [1]. Reconstruction of

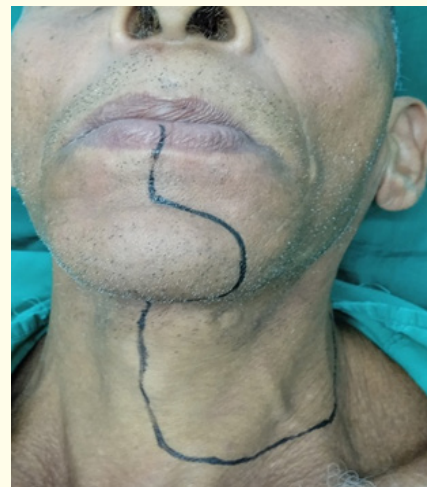

Figure 1

defects resulting from oncologic resection presents a major challenge, especially in the retromolar trigone, where both function and aesthetics must be preserved. In this context, the buccinator myomucosal flap (BMF) has proven to be a versatile and effective option [6].

## Development

### Anatomy and tumor spread

The oral cavity extends from the outer edge of the lips to the junction of the hard and soft palate, and posteriorly to the region of the circumvallate papillae at the base of the tongue. It includes structures such as the lips, anterior two-thirds of the tongue, buccal mucosa, floor of the mouth, gums, retromolar trigone, and hard palate [2].

Lymphatic drainage in this area occurs primarily toward the submental, submandibular, buccal, and jugulodigastric lymph nodes. Midline structures tend to drain bilaterally, increasing the risk of regional dissemination [2].

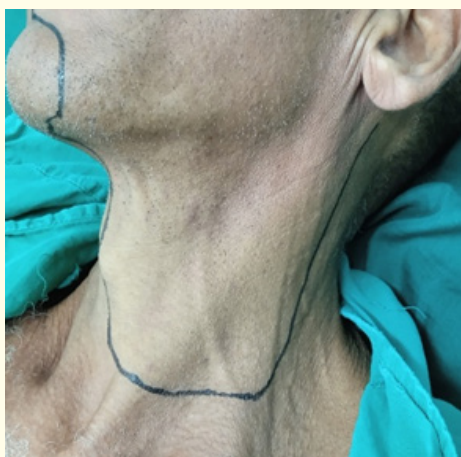

Figure 2

### Precancerous lesions and prognostic factors

The most common precancerous lesions of SCC include leukoplakia, erythroplakia, and erythroleukoplakia. Leukoplakia is the most frequent and is clinically diagnosed by exclusion. In contrast, erythroplakia, though less common, has a higher risk of progressing to dysplasia or carcinoma [3].

In stages I and II, oral SCC has a high cure rate through surgery or radiotherapy, depending on site, depth of invasion, and surgical margins [4]. Depth of invasion has been identified as a key prognostic factor, as has extracapsular nodal extension [5].

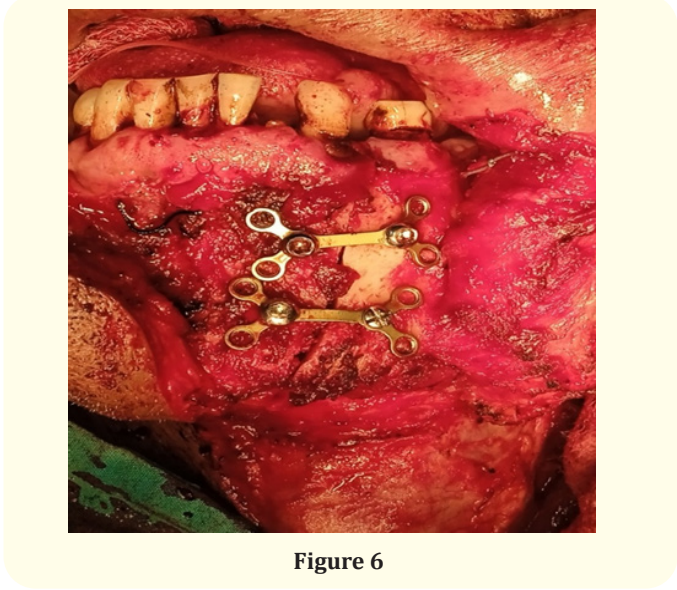
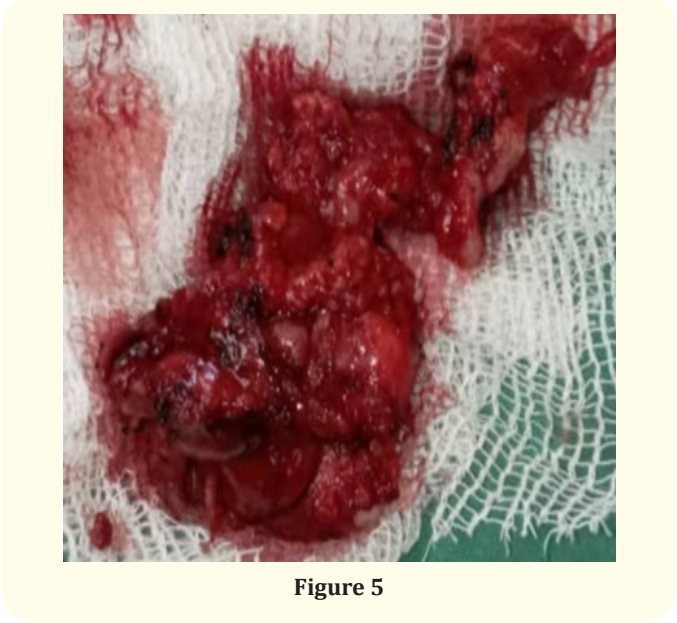
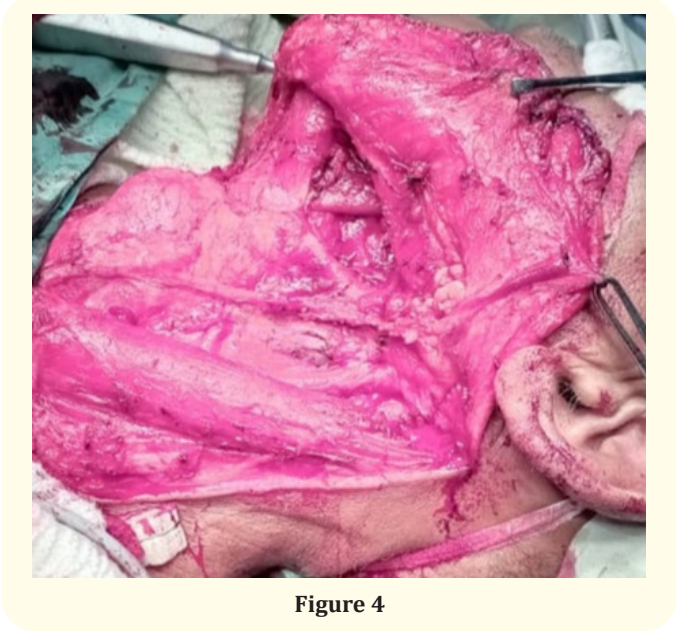
### Surgical reconstruction with buccinator myomucosal flap

The choice of reconstructive method depends on the size and location of the defect. Small defects can be repaired using local flaps, while large defects require regional or microvascular free flaps [6]. For moderate defects, such as those in the retromolar area, the BMF offers an excellent solution due to its versatility, reliable vascularization, and minimal donor site morbidity.

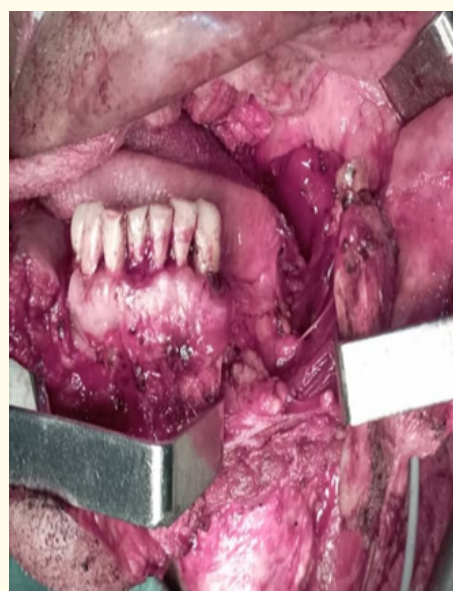
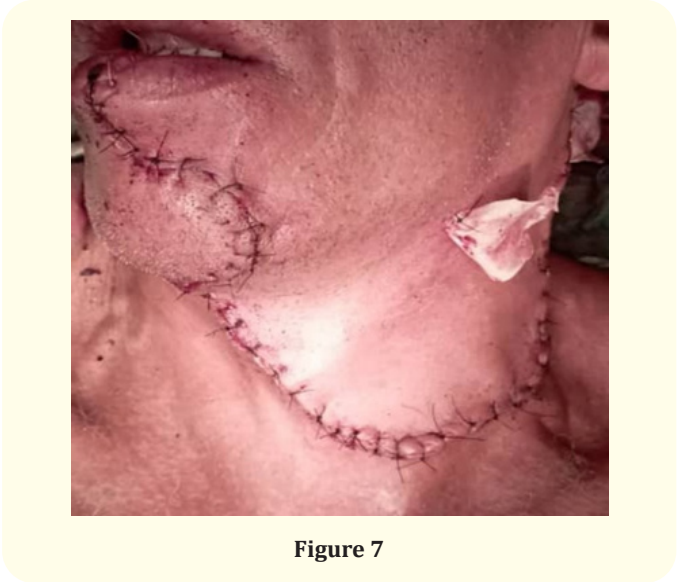
Figure 3

In addition to the oncologic resection and reconstruction with the buccinator myomucosal flap, the patient underwent a bilateral neck dissection to evaluate and manage potential regional lymph node metastases, given the high likelihood of lymphatic spread in carcinomas of the retromolar trigone. A paramedial mandibular approach was employed to adequately access the surgical site, allowing for optimal exposure without compromising functional structures. Subsequently, rigid fixation of the mandibular segment was performed using titanium miniplate osteosynthesis, ensuring bone stability and promoting favorable postoperative recovery.



The BMF was first described by Kaplan in 1975 using buccal mucosa. Later, Maeda in 1987 included fibers from the buccinator muscle to enhance vascularity. Various technical modifications exist, depending on the predominant vascular pedicle (buccal artery, facial artery, or angular branch), allowing the flap to reach areas such as the palate, lower lip, floor of the mouth, nasal cavity, and even periorbital region.

The most common approach is intraoral, though prior dissection of the facial pedicle through a nasolabial or submandibular incision may also be performed. The flap can be designed in fusi-form, Y-shaped, or island configurations depending on the defect to be repaired. The donor area is usually closed primarily or covered with a skin graft in larger defects.

Clinical Applications

The BMF has proven effective in reconstructing multiple intra-oral defects, including those of the palate, tongue, lip, floor of the mouth, and maxillary region. Its predictable vascular anatomy and wide arc of rotation allow coverage of ipsilateral and even midline-crossing defects. In a clinical series, it was successfully used in four cases: two in the floor of the mouth, one in the palate, and one in cleft palate repair.

Conclusions

Squamous cell carcinoma of the retromolar trigone presents both diagnostic and therapeutic challenges due to its location and dissemination potential. Accurate staging, including lymph node dissection, is critical to determine the prognosis [1,5]. Following oncologic resection, reconstruction of the resulting defect plays a key role in restoring function and aesthetics.



The buccinator myomucosal flap has emerged as a viable and effective option for reconstructing moderate oral cavity defects. Its versatility, reliable vascular supply, low complication rate, and the possibility of primary closure at the donor site make it a preferred choice in appropriately selected cases [6,7].

## Bibliography

1. Gallegos-Hernández JF. "Tratamiento del carcinoma epidermoide de la cavidad oral; el valor de la estadificación quirúrgica". *Gaceta Mexicana de Oncología* 14.1 (2015): 23-28.
2. Instituto Nacional del Cáncer (NCI). "Tratamiento del cáncer de labio y de cavidad oral (PDQ®)".
3. Fistera. "Guía clínica de Cáncer de la cavidad oral y orofaringe".
4. National Comprehensive Cancer Network (NCCN). Head and Neck Cancers Guidelines.
5. Huang SH., *et al.* "Depth of invasion and recurrence in oral cancer staged by sentinel node biopsy". *Head Neck* 41.7 (2019): 2100-2106.
6. González García R., *et al.* "Colgajo miomucoso de buccinador en la reconstrucción de defectos del área maxilofacial". *Revista Española de Cirugía Oral y Maxilofacial* 27.4 (2005): 197-205.