



Conservative Surgical Treatment of Recurrent Odontogenic Keratocyst: A Case Report with 10 Years Follow Up

Nasser Al Alami^{1*}, Yaqeen Alaa Aldin AlNaqawa²

¹Oral and MaxilloFacial Surgeon, EHS -Emirates Health Service, UAE

²Intern Dentist trained in Department of Oral and Maxillofacial Surgery EHS, UAE

***Corresponding Author:** Nasser Al Alami, Oral and MaxilloFacial Surgeon, EHS -Emirates Health Service, UAE.

DOI: 10.31080/ASDS.2025.09.2015

Received: March 06, 2025

Published: April 09, 2025

© All rights are reserved by
Nasser Al Alami., et al.

Abstract

Background: Odontogenic keratocysts (OKCs) are complex odontogenic lesions with high recurrence rates despite advances in treatment approaches. Conservative surgical methods like marsupialization and curettage have shown promise in reducing morbidity compared to aggressive resection, but long-term outcomes remain uncertain.

Case Presentation: We report a case of a 19-year-old patient diagnosed with an orthokeratinized OKC extending from #36 to #46 in the mandible. The patient underwent initial curettage and marsupialization followed by conservative post-operative care. Three years later, recurrence was noted but treated with repeated curettage with peripheral ostectomy and marsupialization. Nine years after the initial treatment, follow-up examination showed excellent bone regeneration without signs of recurrence.

Discussion: This case demonstrates the potential effectiveness of conservative surgical approaches like marsupialization and curettage in managing recurrent OKCs, particularly in young patients. While resection offers lower recurrence rates, conservative methods may be viable alternatives with less morbidity. The WHO's 2017 classification of OKC as a developmental cyst supports conservative treatment approaches. Future studies are needed to investigate long-term outcomes of conservative management in aggressive OKCs.

Conclusion: This report advocates for further exploration of conservative surgical options in treating OKCs, balancing efficacy with patient-centered outcomes.

Keywords: Surgical Treatment; Odontogenic; Keratocyst; 10 Years

Introduction

The odontogenic keratocyst (OKC) has been one of the most debated pathological entities in the maxillofacial region since the mid-20th century. Its nature has been enigmatic since its discovery. Its aggressive clinical behavior and high recurrence rate led to its reclassification as an intraosseous benign neoplasm, termed keratocystic odontogenic tumor (KCOT), in the World Health Organization (WHO) classification of 2005 [1]. However, reports of successful treatment through marsupialization prompted a re-evaluation. In the WHO's 2017 revised classification [2], the OKC

was reclassified as a cystic lesion rather than a benign intraosseous neoplasm [1]. Despite extensive research, a definitive understanding of its behavior remains elusive.

Approximately half of all OKCs occur in the angle of the mandible, often extending into the ascending ramus and the body of the mandible. Patients frequently remain asymptomatic until the cyst reaches a significant size, sometimes involving the maxillary sinus and the entire ascending ramus, including the condylar and coronoid processes [3]. Recurrence rates for OKCs vary widely, ranging

from 0% to 100%. These can often be attributed to a combination of factors, including incomplete removal of the cystic lining, presence of satellite cysts or daughter cysts, and subtle variations in surgical technique. The thin and friable nature of the orthokeratinized epithelium poses challenges during enucleation, increasing the risk of residual cystic tissue. The biological behavior of OKC, although less aggressive than that of the parakeratinized variant, may still involve mechanisms such as epithelial proliferation and local invasion, which could contribute to its reappearance.

Treatment approaches have been developed based on molecular studies and comprehensive reviews, aiming to minimize recurrence. Blanas, *et al.* [4] reported recurrence rates of 17% to 56% following simple enucleation in their systematic review of 14 studies. They recommended the use of Carnoy's solution for three minutes post-enucleation, which reduced recurrence rates to 1.6%, comparable to resection but with lower morbidity.

Stoelinga [5] proposed a treatment strategy tailored to OKC's behavior, advocating careful enucleation, excision of overlying mucosa, and the application of electrocoagulation or Carnoy's solution in areas where the cyst adhered to soft tissues. Conversely, Pogrel [6] suggested marsupialization as a standalone treatment,

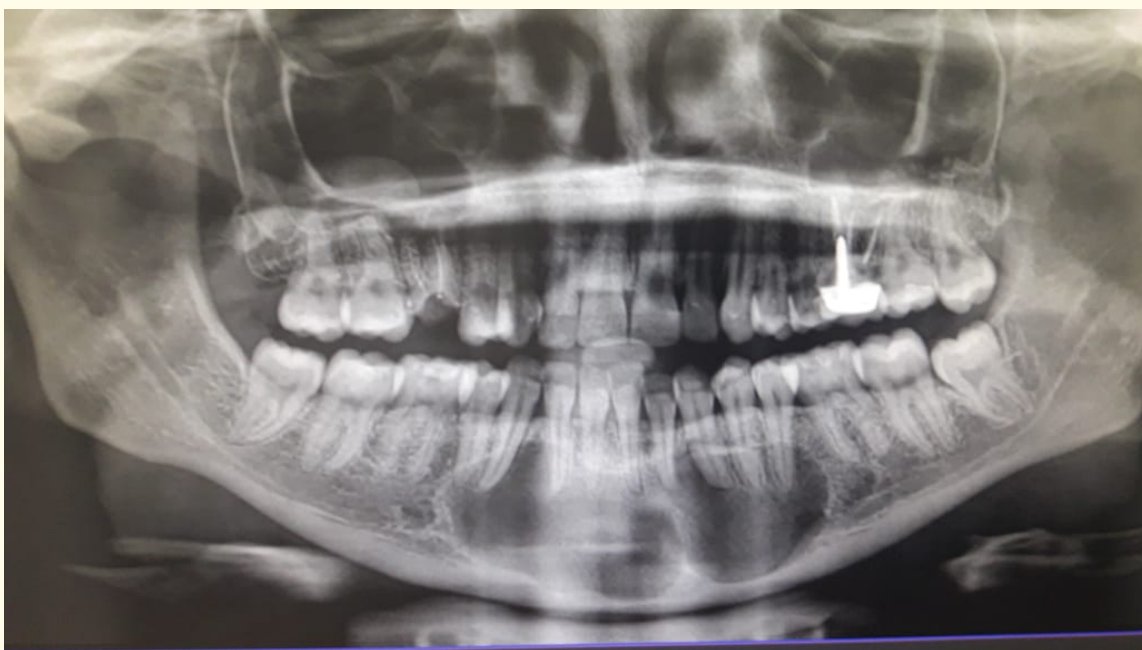citing an average follow-up of 2.9 years. He observed uprighting and eruption of teeth within the cyst, attributing this to reduced interleukin-1 alpha levels in OKCs after marsupialization [7]. Histological analysis following marsupialization revealed normal epithelium without daughter cysts, remnants, or basal epithelial budding. Preoperative bcl-2 protein expression, initially confined to the basal layer, was absent in postoperative specimens, which exhibited normal oral mucosa [6].

To the best of the authors' knowledge, the extensive nature of this lesion has been documented only once in the literature by Gupta, *et al.* [8]. The management approach in this case was guided by Pogrel's findings, [6] which demonstrated that marsupialization can serve as a definitive treatment for OKCs.

Case Report

Patient History

A 19-year-old patient presented with complaints of pain and pus discharge in the lower anterior region, extending from tooth number #36 to #46. (Figure 1) Clinical examination revealed no extraoral swelling, no bone expansion, nor root resorption in the affected area. (Figure 2) Incisional biopsy confirmed the diagnosis of an orthokeratinized odontogenic keratocyst (OKC). (Figure 3).



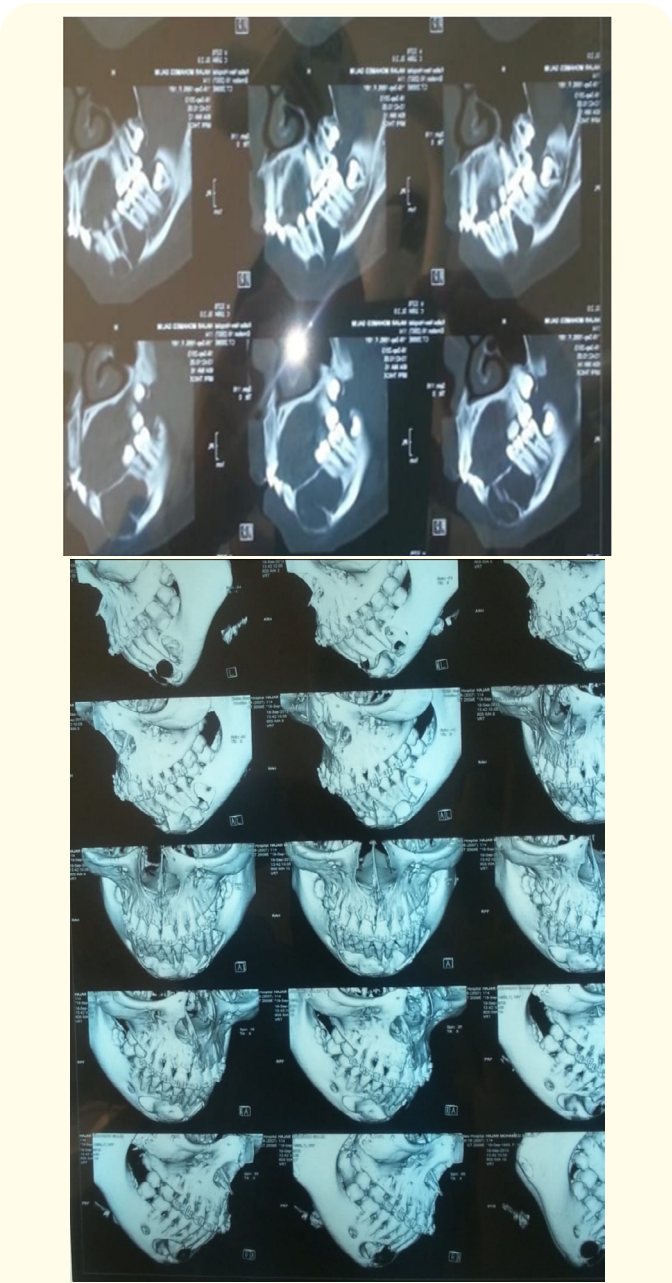


Figure 1: Panoramic x ray show well defined multilocular radio-lucency extending bilaterally between #36 to #46 extending to lower border of mandible and pushing inferior alveolar nerve CT Scan sagittal sections and 3D show extensive osteolytic lesion with outer mandibular cortex perforations and no root resorption.

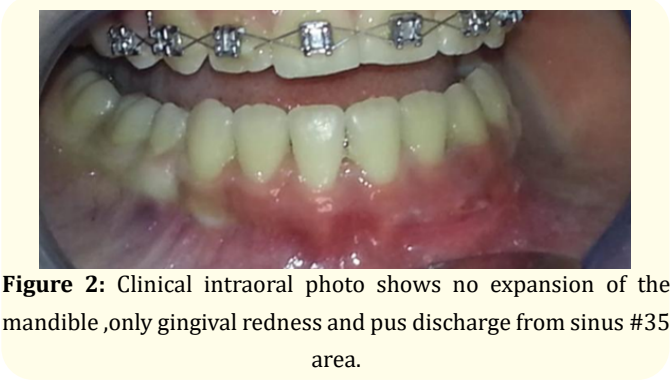

Figure 2: Clinical intraoral photo shows no expansion of the mandible ,only gingival redness and pus discharge from sinus #35 area.

Case:	Collected:	Received:	Requested by:
02-SP-19-005672	20/11/2019 12:25 GST	23/11/2019 12:57 GST	Dr Nasser Mohammed A
1 Surg Path Final Report			
Status:	Date:	By:	At:
Authenticated	26/11/2019 12:50 GST	Desh Deepak Idnani	MSK Sheikh Khal
Clinical Information			
Specimen Description: cystic lining and content (lesion and mandibular symphysis bilaterally with pus discharge			
Clinical History: recurrent lesion started 7 years ago extended from lower molar right side to the other side			
Clinical Diagnosis: odontogenic keratocyst			
Gross Description			
Received container labeled with patient name and medical record number having formalin fixed multiple soft tissue pieces measuring 3x0.8x0.5 cm, all submitted in 2 blocks.			
DDVDDI			
Microscopic Description			
Sections studied shows fragments of cyst lined by 6-8 cell thickness squamous epithelium without rete ridges, underlying fibroconnective tissue stroma has mixed inflammatory cell infiltration by neutrophils, plasma cells, lymphocytes and histiocytes with fibrosis. Lumen shows anuclear keratin. No evidence of malignancy seen.			
Diagnosis			
Orthokeratinized Odontogenic Keratocyst- Mandible			
Pathologist: Dr. Desh Deepak Idnani			
(Electronically signed by)			
Verified: 26/11/2019			
DDVDDI			
Comment			
Follow up recommended.			

Figure 3: Histopathology report of incisional biopsy diagnose the lesion as orthokeratinized odontogenic cyst mandible.

Initial Management

Radiographically, an eggshell- bone outline huge cystic lesion of the mandible with buccal cortex perforations. Surgical intervention included curettage with marsupialization was done on the first visit, using a mucoperiosteal elevator (Figure 4). Antibiotics were prescribed preoperatively and for 10 days postoperative. Postoperative care involved regular irrigation with diluted betadine and saline on alternate days, followed by bi-weekly irrigation and redressing for six months. A CT scan conducted 4 months postoperatively revealed a significant reduction in the size of the lesion with bone formation and minimal pus discharge (Figure 5). Patient was asked for continuation of treatment by surgical curettage , however she refused to be subjected to a second surgery. Therefore, follow up was on for almost 1 year (Figure 6).

Follow-up and recurrence

The patient did not return for follow-up until three years later, when recurrence was noted, lesion was smaller in size compared

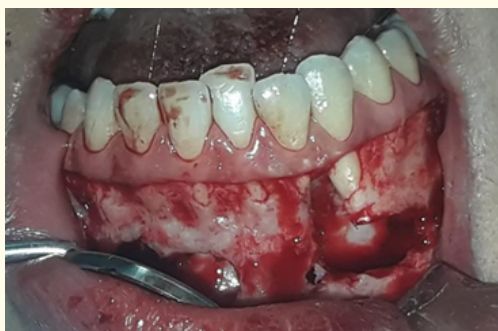

Figure 4: Surgical procedure performed under local anesthesia involved incomplete enucleation, overlying egg shell bone removed with periosteal elevator. Marsupialization done by iodoform packing.

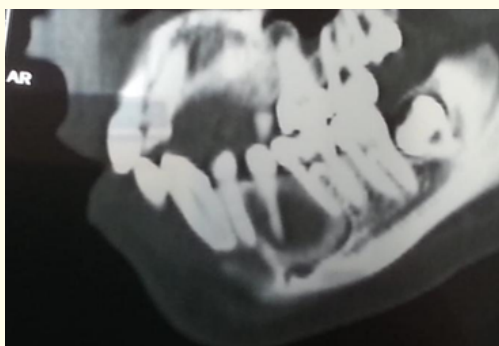

Figure 5: After 4 months follow up lesion significantly reduced in size with evidence of bone regeneration.

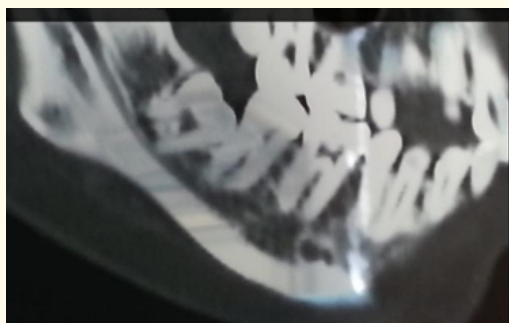

Figure 6: Follow up CT scan after 12 months show almost complete healing of the cystic lesion.

to the original size of the lesion, accompanied by renewed pus discharge. (Figure 7) In recurrence, vitality testing was conducted for the teeth involved #36 to #46, and concluded that tooth number #32 was not vital, therefore, root canal treatment was done for #32. To exclude any possible trigger for recurrence. Moreover, surgical curettage with peripheral ostectomy using a low speed handpiece surgical bur, and followed by packing with iodoform gauze was performed for marsupialization. Postoperatively, pus discharge reduced significantly, eventually subsiding completely.

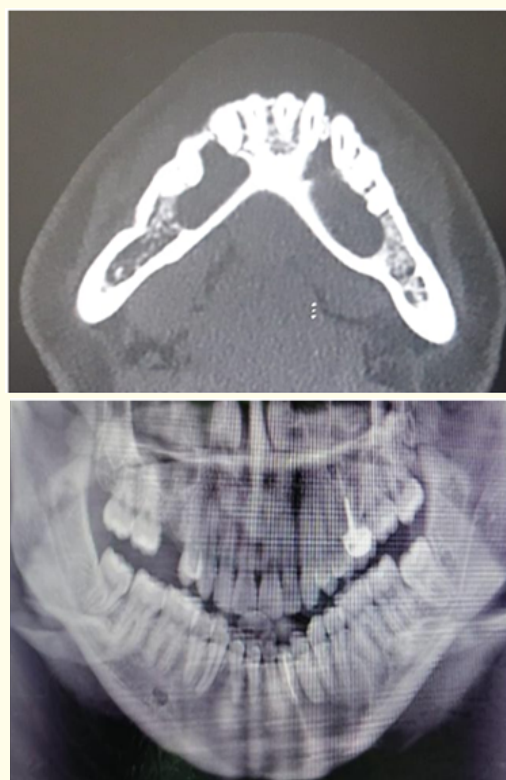

Figure 7: Recurrence of the lesion after 3 years seen in Panoramic x ray and axial section CT scan showing as 2 cysts separated by bony septum. RCT performed for non vital tooth #32.

Long-term outcome

A follow-up examination conducted 5 years later demonstrated excellent bone regeneration with no signs of recurrence (Figure 8).

Discussion

The reclassification of OKC from benign odontogenic tumors to odontogenic developmental cysts was driven by new insights into

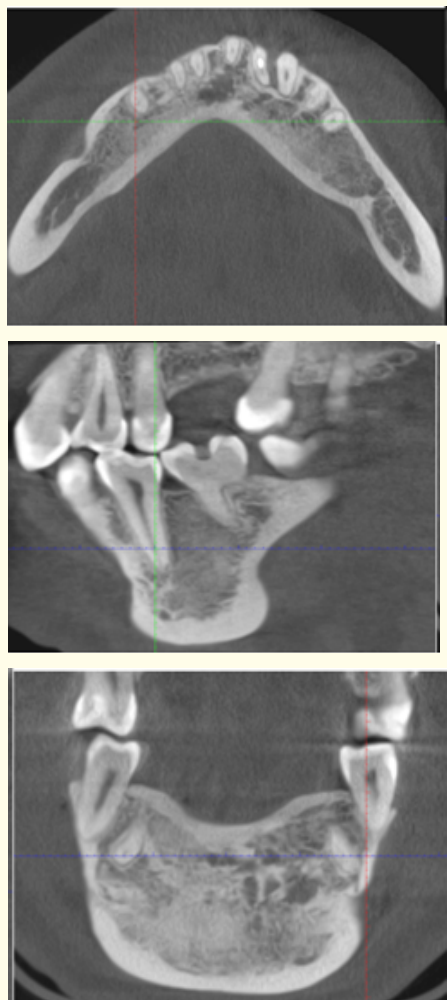


Figure 8: Follow up CT scan axial,sagittal and coronal sections show complete healing and bone regeneration.

its morphogenesis and biological behavior. Studies have shown that PTCH1 gene mutations, previously associated with OKCs, are not specific to this entity, as they also occur in follicular cysts. Depending on whether the lesion is sporadic or linked to Gorlin–Goltz syndrome, PTCH1 alterations are found in 30–85% of cases. Additionally, evidence indicates that OKCs can regress after decompression or marsupialization, with the cyst lining undergoing a spontaneous transformation into normal oral epithelium. These findings disqualify OKCs from being classified as neoplastic lesions and support their reclassification as odontogenic developmental cysts [9].

This change in nomenclature has influenced treatment strategies for OKCs, which are now guided by factors such as the patient's age, compliance, and the size and location of the lesion [9]. Bone resection remains the most effective approach for reducing recurrence rates, with segmental resection and marginal resection yielding recurrence rates of 0% to 8.4% [9-13]. However, these procedures are typically reserved for multi-chamber lesions due to their invasiveness.

Enucleation with peripheral ostectomy has emerged as a promising alternative, involving the surgical excision of the lesion followed by selective removal of surrounding peripheral bone using a powered handpiece to ensure complete eradication of macroscopic remnants [14]. After the primary enucleation, a surgical handpiece equipped with a large round bur was employed to remove peripheral bone under copious irrigation.

This case underscores the efficacy of conservative surgical treatment modalities, such as marsupialization and curettage, in managing recurrent OKCs. Moreover, the treatment plan was thoroughly discussed with the patient who was only 19 years old and did not want to undergo multiple invasive procedures with significant morbidity, that will eventually not lead to optimum esthetics. Therefore, a conservative surgical treatment plan was conducted using the support of both conducted studies of Pogrel., *et al*, and Stoelinga., *et al*. on their conservative surgical approaches.

Pogrel [6] extensively highlighted the advantages of marsupialization, emphasizing its ability to reduce lesion size and recurrence while preserving vital structures. Similarly, Stoelinga [5] advocated for enucleation combined with adjunctive measures like Carnoy's solution to minimize recurrence. While Blanas., *et al*. noted slightly higher recurrence rates with conservative methods compared to resection, this case demonstrates their potential as viable alternatives, particularly for patients prioritizing structure preservation [4].

In case of our 19-year-old patient, resection can be especially aggressive, given its potential to cause significant functional and cosmetic consequences. This procedure often requires removal of extensive bone and scarifying teeth, which necessitate subsequent reconstructive surgeries, leading to long-term morbidity. Additionally, such invasive treatment can result in permanent paresthesia,

loss of jaw continuity, and impairment of masticatory function, profoundly affecting the patient's quality of life during critical developmental years. For a young patient, the goal of treatment is not only to minimize recurrence but also to preserve function, aesthetics, and quality of life. Enucleation with peripheral ostectomy represents a balanced approach, offering effective management of OKCs with relatively low morbidity, making it a more appropriate choice for this age group. This underscores the importance of individualized treatment planning, taking into account both the biological behavior of the lesion and the patient's age, anatomy, and overall health status. Future studies should further investigate long-term outcomes of conservative surgical management in aggressive OKCs.

Conclusion

This case highlights the potential effectiveness of conservative treatment modalities, such as marsupialization and curettage, even in cases of recurrent OKC. While studies suggest that resection yields lower recurrence rates, particularly for OKCs due to the presence of daughter cysts, this case suggests that conservative surgical approaches may be viable alternatives. Such methods could minimize patient morbidity while achieving favorable outcomes in select cases. This report advocates for further exploration and consideration of conservative treatment options in managing aggressive OKCs.

Bibliography

1. WHO. Pathology and Genetics of Head and Neck Tumours. World Health Organization Classification of Tumours. IARC Press (2005): 430.
2. Sci-Hub. "Update from the 4th Edition of the World Health Organization Classification of Head and Neck Tumours: Odontogenic and Maxillofacial Bone Tumors". *Head and Neck Pathology* 11.1 (2024): 68-77.
3. Sci-Hub. "Odontogenic keratocysts: clinical features". *Oral and Maxillofacial Surgery Clinics of North America* 15.3 (2024): 335-345.
4. Sci-Hub. "Systematic review of the treatment and prognosis of the odontogenic keratocyst". *Oral Surgery, Oral Medicine, Oral Pathology, Oral Radiology, and Endodontology* 90.5 (2024): 553-558.
5. Stoelinga PJW. "Excision of the overlying, attached mucosa, in conjunction with cyst enucleation and treatment of the bony defect with carnoy solution". *Oral and Maxillofacial Surgery Clinics of North America* 15.3 (2003): 407-414.
6. Pogrel MA. "Decompression and marsupialization as a treatment for the odontogenic keratocyst". *Oral and Maxillofacial Surgery Clinics of North America* 15.3 (2003): 415-427.
7. Sci-Hub. "Marsupialization inhibits interleukin-1alpha expression and epithelial cell proliferation in odontogenic keratocysts". *Journal of Oral Pathology and Medicine* 31.9 (2024): 526-533.
8. Sci-Hub. "Pan-mandibular keratocyst with eosinophilia". *International Journal of Oral Surgery* 14.3 (2024): 311-313.
9. Kaczmarzyk T, et al. "Update of the WHO classification of odontogenic and maxillofacial bone tumours". *Journal of Stomatologia Polskie Towarzystwo Stomatologiczne* (2017): 484-5606.
10. (PDF) Odontogenic keratocyst of the mandible: A case report and literature review" (2024).
11. Sci-Hub. "A systematic review of the recurrence rate for keratocystic odontogenic tumour in relation to treatment modalities". *International Journal of Oral and Maxillofacial Surgery* 41.6 (2024): 756-767.
12. Menon S. "Keratocystic Odontogenic Tumours: Etiology, Pathogenesis and Treatment Revisited". *Journal of Oral and Maxillofacial Surgery* 14.3 (2014): 541.
13. Sci-Hub. "Management and recurrence of keratocystic odontogenic tumor: a systematic review". *Oral Surgery, Oral Medicine, Oral Pathology and Oral Radiology* 116.4 (2024): e271-e276.
14. Sci-Hub. "A systematic review of the recurrence rate for keratocystic odontogenic tumour in relation to treatment modalities". *International Journal of Oral and Maxillofacial Surgery* 41.6 (2020): 756-767.
15. Mario Dioguardi, et al. "Factors and management techniques in odontogenic keratocysts: a systematic review". *European Journal of Medical Research* 29.287 (2024).
16. Fadi Titinchi. "Protocol for management of odontogenic keratocysts considering recurrence according to treatment methods". *Journal of the Korean Association of Oral and Maxillofacial Surgeons* 46.5 (2020): 358-360.