



## Non-Surgical Management of Periapical Lesion and Immature Apex with Bioceramics and Water Based Calcium Hydroxide Paste: A Case Report

Eldho Jijy Varghese\*

Department of Conservative Dentistry and Endodontics Royal Dental College  
Chalissery, Palakkad, Kerala, India

\*Corresponding Author: Eldho Jijy Varghese; Department of Conservative  
Dentistry and Endodontics Royal Dental College Chalissery, Palakkad, Kerala, India.

DOI: 10.31080/ASDS.2023.07.1710

Received: August 21, 2023

Published: September 05, 2023

© All rights are reserved by Eldho Jijy  
Varghese.

### Abstract

Early childhood dental trauma frequently results in the persistence of immature non-vital teeth accompanied by apical periodontitis and inflammatory external root resorption. Due to the lack of a defined apical stop, such teeth provide various challenges to the clinician. The nonsurgical approach is highlighted in this case report. Endodontic treatment of a comparable patient in a unique approach, with long-term clinically favorable results.

**Keywords:** Periapical; Immature; Apex; Calcium Hydroxide

### Introduction

Traumatic tooth injuries are common in early childhood, typically involving maxillary incisors, which can result in nonvital teeth with immature root apex and, in many cases, apical periodontitis and root resorption if not treated promptly. Endodontic therapy axioms include proper access, cleansing, and shape, followed by three-dimensional sealing of the root canal system. Non-vital teeth with underdeveloped apex frequently provide difficulties for clinicians [1-5].

The major reasons include difficulty in estimating working length due to expansion of inflammatory periapical tissue into the root canal space, increased likelihood of irrigating solution apical extrusion, and inability to close the apical third of the root canal system. For the management of such cases, various treatment modalities are recommended, including long-term apexification with calcium hydroxide, retrograde root end filling with various restorative materials, formation of an apical plug with tricalcium phosphate, mineral trioxide aggregate, and, more recently, pulp revascularisation. The concept of an apical matrix has also been proposed in conjunction with an apical plug; various materials such as collagen, hydroxyapatite, demineralised freeze dried bone graft, platelet rich plasma, or a combination of platelet rich plasma and hydroxyapatite have been used to create the apical matrix [6-10].

Recently, the successful use of hydroxyapatite as an apical matrix, as well as bio mimetic obturation in the apical third of the root canal, has been proposed. This study describes the use of tricalcium silicate-based cement as an apical barrier and obturation material with clinically satisfactory results. The concept of an apical matrix has also been proposed in conjunction with an apical plug; various materials such as collagen, hydroxyapatite, deminer-

alised freeze-dried bone graft, platelet rich plasma, or a combination of platelet rich plasma and hydroxyapatite have been used to create the apical matrix.

Recently, the successful use of hydroxyapatite as an apical matrix, as well as bio mimetic obturation in the apical third of the root canal, has been proposed. This study describes the use of tricalcium silicate-based cement as an apical barrier and obturation material with clinically satisfactory results [10-15].

### Case Report

A 14-year-old male patient came to the clinic with complaint of swelling in relation to upper front tooth region. On oral examination, it was found that 21 has zirconia crown and swelling in relation to the buccal aspect of 21. On radiographic examination, 21 showed overextended gutta percha cones with a large radiolucency in the periapical region suggestive of periapical cyst (Figure 1). Re-endodontic therapy was decided in 21. Access opening was done through the crown. There was pus discharge following the access opening. The gutta percha was removed using F3 protaper Gold file and gutta percha solvent (RC solve), a thorough chemomechanical preparation was performed. The root canals were irrigated with combination of 2 percent chlorhexidine and sterile saline solution and was activated with sonic irrigator. The canals were dried with sterile paper points. For the first dental visit, the abscess was drained and calcium hydroxide water based paste was packed within the root canal space using gutta percha points. The access cavity was closed with sterile cotton plug and Cavit-G. The patient was recalled after 7 days. The swelling was reduced and radiographic healing was appreciated in the second dental visit. For the second dental visit, the calcium hydroxide paste was flushed out and thorough irrigation was done using 2 percent chlorhexidine

and sterile saline. New calcium hydroxide paste - Neocal was injected into the canal space. The access cavity was sealed with intermediary restorative material Cavit -G. On the third dental visit after 7 days, the swelling was reduced and radiographic healing was appreciated with complete relief from swelling and the intraoral intervention of the granulomatous tissue was done using a surgical blade no. 15 and curettes. The calcium hydroxide paste was flushed out and thorough irrigation was done using 2 percent chlorhexidine and sterile saline. New calcium hydroxide paste - Neocal was injected into the canal space. The access cavity was sealed with intermediary restorative material Cavit -G. The patient was recalled after 7 days. On the fourth dental visit, satisfactory healing was seen radiographically and obturation was done using bioceramic hydraulic condensation technique in which F3 protaper gutta percha was used as a carrier for the bioceramic sealer (MAARC Ceraseal B) (Figure 2). A permanent core restoration was done using direct composite and the patient was recalled after two weeks for indirect permanent restoration.

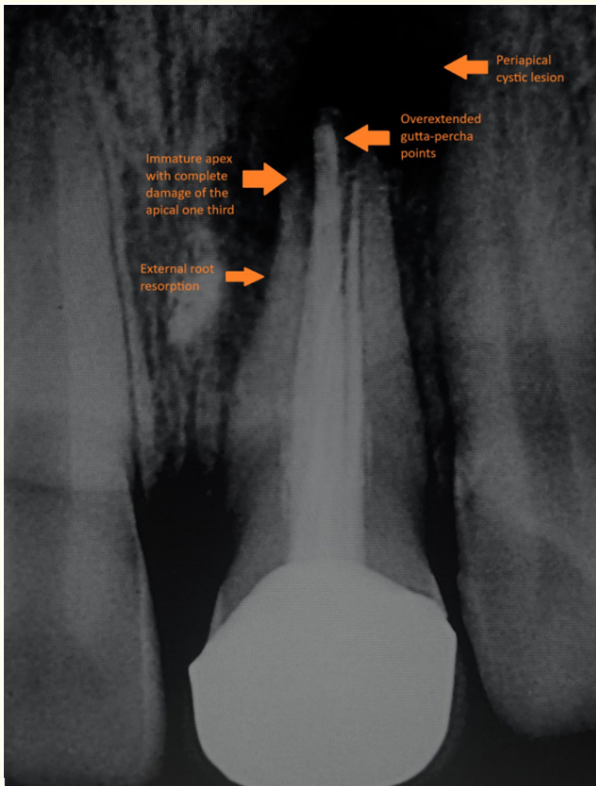


Figure 1

**Discussion**

Microorganisms cause apical periodontitis and removing them from the root canal space during root canal therapy results in predicted healing of apical pathosis. Unfortunately, it is unlikely that microorganisms will be entirely removed by instrumentation alone; encapsulation of bacteria will also significantly impair the physical features and ability of the root filling to adapt to the canal walls. Some sort of irrigation and disinfection is consequently required to eradicate germs, their metabolites, and residual tissue,

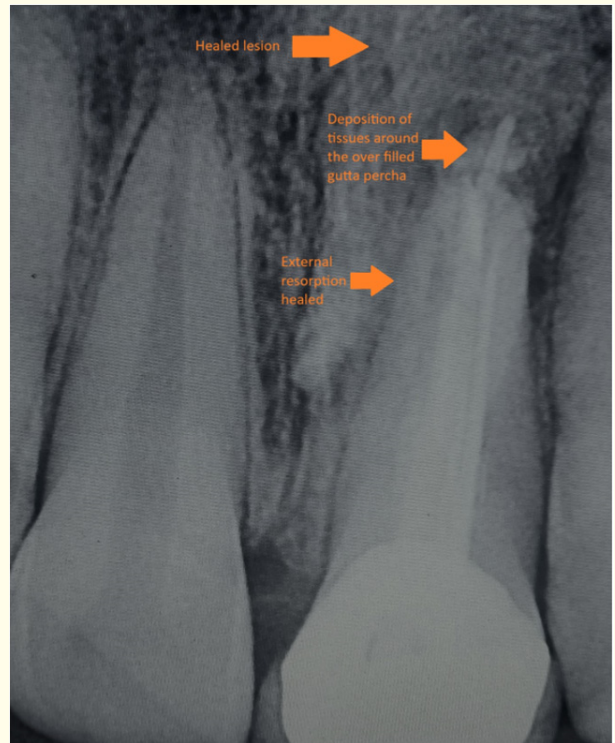


Figure 2

as well as to clear the smear layer and other debris from the canal system. Irrigants, canal rinses, and between-appointment drugs are all examples of chemical (therapeutic) root canal treatments.

Calcium hydroxide has been suggested to improve healing in a range of therapeutic contexts since it was first employed in dentistry (Hermann 1920). The antibacterial action of calcium hydroxide is determined by how quickly it degrades into calcium and hydroxyl ions in a high pH environment. This inhibits essential enzymatic activity for microbial life, such as metabolism, growth, and cellular division. However, the overall mechanism of action of calcium hydroxide remains unknown. Ca (OH)2 is widely used to affect periapical healing by combining its antibacterial action with its ability to promote the formation of hard tissue and periodontal healing.

Ca++ and OH are promptly released when Ca (OH)2 and saline solution are mixed and the paste comes into touch with the tissue and tissue fluids [10-15].

**Conclusion**

Non-surgical approach has to be attempted before proceeding with surgical approach. With the advancements in material science, endodontics is moving a leap ahead with the treatment outcome.

**Acknowledgment**

Dr Abdul Latheef K H, Dr Aswathi, Dr Rahmath Snuba Shareef [Smile 365 Dental Clinic, Kallungal, Vadakkekad, Thrissur, Kerala].

## Bibliography

1. Pavuluri C and Nuvvula S. "Management of Traumatic Injury to Maxillary Central Incisors associated with Inverted Meiodens: A Case Report". *International Journal of Clinical Pediatric Dentistry* 6.1 (2013): 30-32.
2. Finucane D and Kinirons MJ. "External inflammatory and replacement resorption of luxated, and avulsed replanted permanent incisors: a review and case presentation". *Dental Traumatology* 19.3 (2003): 170-174.
3. Trope M. "Treatment of the immature tooth with a nonvital pulp and apical periodontitis". *Dental Clinics of North America* 54.2 (2010): 313-324.
4. Chala S., et al. "Apexification of immature teeth with calcium hydroxide or mineral trioxide aggregate: systematic review and meta-analysis". *Oral Surgery, Oral Medicine, Oral Pathology, Oral Radiology, and Endodontology* 112.4 (2011): e36-42.
5. Coviello J and Brilliant JD. "A preliminary clinical study on the use of tricalcium phosphate as an apical barrier". *Journal of Endodontics* 5.1 (1979): 6-13.
6. Lin JC., et al. "Comparison of mineral trioxide aggregate and calcium hydroxide for apexification of immature permanent teeth: A systematic review and meta-analysis". *Journal of the Formosan Medical Association* 115.7 (2016): 523-530.
7. Albuquerque MTP, et al. "Pulp revascularization: an alternative treatment to the apexification of immature teeth". *Rev Gaúch Odontol, Porto Alegre* 62.4 (2014): 401-410.
8. Moses O., et al. "Healing of dehiscence-type defects in implants placed together with different barrier membranes: A comparative clinical study". *Clinical Oral Implants Research* 16.2 (2005): 210-219.
9. Chhabra N., et al. "Successful apexification of a failed root canal treated immature tooth using a novel technique". *ENDO* 7.2 (2013): 91-95.
10. Chhabra N., et al. "Successful apexification with resolution of the periapical lesion using mineral trioxide aggregate and demineralised freeze-dried bone allograft". *Journal of Conservative Dentistry* 13.2 (2010): 106-109.
11. Holland R., et al. "Tissue reaction following apical plugging of the root canal with infected dentin chips". *Oral Surgery* 49.4 (1980): 366-369.
12. Traebert J., et al. "Aetiology and rates of treatment of traumatic dental injuries among 12 years-old schoolchildren in a town in southern Brazil". *Dental Traumatology* 22.4 (2006): 173-178.
13. Kerekes K., et al. "Follow-up examination of endodontic treatment in traumatized juvenile incisors". *Journal of Endodontics* 6.9 (1980): 744-748.
14. Cvek M., et al. "Antimicrobial effect of root canal debridement in teeth with immature root. A clinical and microbiologic study". *Odontol Revy* 27.1 (1976): 1-10.
15. Alhadainy HA., et al. "Use of a hydroxylapatite-based material and calcium sulfate as artificial floor to repair furcal perforations". *Oral Surgery, Oral Medicine, Oral Pathology, Oral Radiology, and Endodontology* 86.6 (1998): 723-729.