



Retrospective Analysis of the Anthropometric Evaluation of Clinical Outcomes of the different Categories of Unilateral Cleft Lip after Reconstruction

Reda Ahmade Eldesocky Nofel*

Professor of Oral and Maxillofacial Surgery, College of Dentistry, Umm Al-Qura University KSA and Al-Azhar University, Saudi Arabia

***Corresponding Author:** Reda Ahmade Eldesocky Nofel, Professor of Oral and Maxillofacial Surgery, College of Dentistry, Umm Al-Qura University KSA and Al-Azhar University, Saudi Arabia.

DOI: 10.31080/ASDS.2023.07.1607

Received: March 08, 2023

Published: March 23, 2023

© All rights are reserved by **Reda Ahmade Eldesocky Nofel**.

Abstract

The Purpose of the current study was to evaluate the use of lateral columellar flap in correction of different categories of complete unilateral cleft lip.

Data were collected retrospectively from all patients with who were operated on between 2020 and 2022. Of 18 children were suitable for analysis with harelip (complete cleft lip) included in this study. The patients were classified according to the severity of the defect into 3 groups, 6 patients each: Group I mild cleft, Group II moderate cleft and Group III severe cleft. The patients were assessment after correction and at 2, 8 and 14 months post operatively, and all measures were recorded using a caliper for anthropometrics evaluation. Each measurement was done 5 times and the average value was recorded.

At 2 months postoperatively, there was a significant increase ($P < 0.05$) of nostril width (group I) and highly significant increase ($P < 0.01$) in nostril height (group II) as compared to the other group. At 8 months postoperatively, there was a significant increase ($P < 0.05$) and highly significant increase ($P < 0.01$) in nostril height in (group I) as compared to the other groups. There was a significant increase ($P < 0.05$) in philtral height, fullness of the lip and width of cupids. At 14 months post-operatively. A highly significant increase ($P < 0.01$) was noted in nostril widths, nostril height, philtral height and fullness of the lip in (group I) compared to the other groups. While there was no significant difference ($P < 0.05$) between groups and the other lip components. ($F = 30.66$).

All patient recovered uneventfully, and the columellar flap healed completely with no poststorepaire complications. The site of the medial and lateral segments represented the philtrum column. The vertical height of the arch of the Cupid's bow was equal on each sides. The texture of lateral nostril matched the skin of the columellar area, which considered more accepted cosmetically. It has been shown that the currently study flap has augmented the defected lip by additional tissues.

Keywords: Cleft Lip; Cheilorrhaphy; Nasal Deformity

Introduction

Cleft lip and palate has one of the highest incidences in the malformations of the oral cavity, that varies between populations. The background underlying the issue of cleft lip and palate is multifactorial and greatly depends on the genetic factors and environmental factors [1].

Internationally, the incidence of harelip and palate is quite high: harelip represents 1:1000, cleft palate 0.45:1000, complete cleft 1:1800, submucosal cleft 1:1200 and bifid uvula 1:1000 [6,10,12].

A variety of techniques have been used to repair the cleft lip such as: Le Mesurier's quadrilateral flap or rectangular flap [20,30], Z-plasty and modified-Z-plasty repair [11], Millard's rotation advancement flap [24], modified rotation advancement repair (lower one third triangular flap), as well as in utero-neonatal harelip repair [22].

Cheilorrhaphy has received increasing attention in the past two decades, but it remains an incompletely solved problem. The harelip deformity is one of the most major problems that require a continuing search to improve the techniques for their closure [19].

Children with repaired complete harelip invariably show some degree of deformity in their lip, and dentition. The surgical correction of lip and palate leads to a series of well recognized secondary growth disturbances including nostrils asymmetry, wide ala implantation, deformity of the upper lip and characteristic scarring of philtral area as well as, diminished or absent nose border and sever hypoplastic maxilla which leads to retrognathic of the upper lip [8,9].

The majority of children corrected by lateral nasal flap for unilateral harelip did not undergo revisional surgery. They concluded that, this flap technique is one of the most suitable methods for unilateral harelip repair. Riden [19] utilized a small flap from the nostril and the inner aspect of the columella, rolling this flap underneath the columellar base to form the dimple and to increase the fullness of the lip.

The lateral columellar flap is often sufficient to fill the resultant lip defect and even, provide columellar lengthening. They stated that, the evaluation of this flap design is lacking the assessment of the columella, nostril width and height and the length of the deflected lip [17].

In an attempt to overcome such drawbacks of cleft lip correction, a columellar flap was introduced, the tissue deficiency of the medial lip segment is filled with a flap from the lateral surface of nose, and then lowered vertically as one piece to the nostril border of medial side. Although the ideal technique for lip correction is still an issue of controversy, the current study, has hypothesized that the lateral nasal flap could be of value as a suitable technique for unilateral complete harelip reconstruction.

Aim of the work

This study was conducted retrospectively, to assess the lateral columellar flap in reconstruction of unilateral complete cleft lip.

Patients and Methods

Of 18 children,18 were suitable for analysis. A 18 children (12 male and 6 female). The mean age at time of surgery was10 to 15 (mean 12.5) months with repaired of complete unilateral cleft lip were included in this study. Patients were selected from those attending the outpatient clinic of the pediatric surgery, plastic surgery and oral surgery departments.

To be enrolled in the study, the infants had to meet the following criteria: body weight more than 10 pounds, hemoglobin more than 10 gram/deciliter, free from throat pathogens, systemic diseases, white cell count should be below 10,000/Cm³.

Any patient who did not fulfill the criteria was excluded from this study. Detailed history was taken from parents or grandpar-

ents. All children underwent a one stage repair of harelip. The cleft was evaluated clinically and classified according to its severity (26 and 29) into three groups of 6 each

- Group I: patients with mild unilateral complete harelip (≤2mm).
- Group II: patients with moderate unilateral complete cleft (>2mm <3 mm).
- Group III: patients with severe unilateral complete cleft (>3 mm).

The children were evaluated after surgery at 2, 8 and 14 months postoperatively and all measures were recorded using a caliper for direct anthropometrics analysis [2,14]. Each measurement was done three times and the average value was recorded in millimeters. Patients grouping and preoperative clinical observations in all infants are summarized in table 1.

Infants numbers	Columellar deformity	Width of the soft tissue defect	Severity of nasal deformity
4	Short	Mild ≤ 2mm	Mild
4	Deviated	Mild ≤ 2mm	Mild
6	Short	Moderate >2mm - ≤3 mm	Moderate
4	Short	Severe >3 mm	Severe

Table 1: Children grouping and pre-operative clinical observation in all Patient.

Surgical technique

The protocol used in this study, two stay stitches were made bilaterally at the angle of the mouth to ligate the superior labial branch of facial artery bilaterally as well as to aid in retraction of soft tissues. The lateral surface of columella was exposed with two small hooks. The lip was turned up and a relaxing incision at the summit of the labioalveolar sulcus was performed. A mucoperiosteal elevator was used to deeply dissect and pack the area with soaked gauze to decrease the amount of blood loss.

An incision was performed at mucocutaneous nostril of the cleft margin and the columellar flap was elevated at edge of the lip. The mucoperiosteum of nostril floor was elevated. The muscle of lateral lip segment was dissected free from its dermal and mucosal attachments and then it was turned to recipient site, followed by a relaxing incision at the summit of the labioalveolar fold. Through this relaxing incision, supraperiosteal undermining was made upward to free the attachment of nasal ala and to free the lower part of the side of the nose from the maxilla. Lateral lip segment and the extended small rectangular mucocutaneous flap was moved as one piece medially and sutured with already prepared medial seg-

ment (Figure 1). A three-layer closure of mucosa, muscle and skin was performed on the lip. The red line or cutaneous nostril line of the two segments was placed in the same line. Sutures were removed

7 days postoperatively. Patients were discharged from hospital 3 days post-operatively with follow up card. The patients were kept on fluids for 24 hours and instruct his/her mother to avoid sucking or breast feeding for seven days.

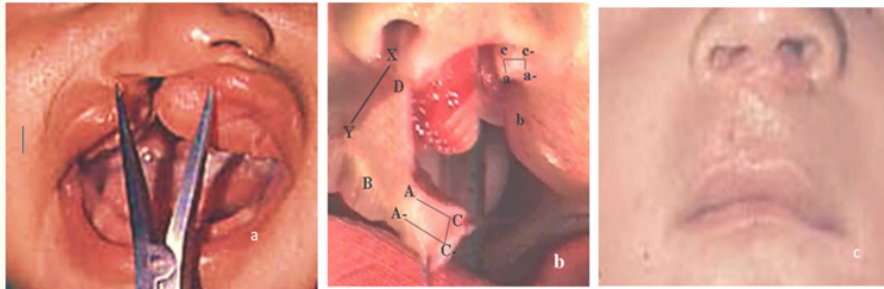


Figure 1: (a) Showing measurements of the cleft dimensions using a caliper and (b) the designing of the flap. (c) 14 months postoperatively.

Evaluation

Clinical and anthropometric evaluations were undertaken for all patients preoperatively and at 2, 8 and 14 months postoperatively as follows:

Clinical evaluation

Patients were closely inspected immediately after surgery and through the first three days. Considerations were given to the following: flap healing processes and changes in color of the flap, infection, which may reflect partial or complete necrosis of the flap, the integration between the flap with the skin margin and underlying tissues. This was done by testing the union using cotton pellet and probing, symmetry of nostrils, lip fullness and symmetry of the nostril and cupid's bow.

Anthropometric evaluation

Anthropometric evaluation is a quantitative method in which surface measurements were recorded directly from the patient nose and lip using a fine bipoint caliper [3,18,22,26]. These included three points measured on the nose (nostril height, nostril width and the columellar length) and four points on the upper lip (cutaneous lip height, nostril (red lip) height, Cupid's bow height as well as width and fullness of lip). All measurements were recorded for all children preoperatively and at 2, 8 and 14 months postoperatively).

Cleft Lip Component Symmetry Index (CLCSI)

It is a quantitative method in which surface measurements were recorded directly from the patient during growth. Harelip component symmetry index (CLCSI) described by (3 and 22) was used to assess the symmetry of both cleft and non-cleft side according to the following formula

$$CLCSI = \frac{Cleft.side.A1}{Noncleft.side.A2} \times 100 .$$

A value of 100 would indicate perfect symmetry of the components, and a value either less or more would mean a degree of asymmetry. Statistical analysis: The collected data was tabulated and statistically analyzed using a software program (SPSS v. 8) at a level of significant 5%.

Results

At 2 months postoperatively, there was a significant increase ($P < 0.05$) of nostril width (group I) and highly significant increase ($P < 0.01$) in nostril height (group II) as compared to the other group. At the same time there were an alternative change in fullness of the lip, nostril height, cupid's height and width, philtral height and length of columella as showing in figure 2. At 8 months postoperatively, there was a significant increase ($P < 0.05$) and highly significant

cant increase ($P < 0.01$) in nostril height in (group I) as compared to the other groups. There was a significant increase ($P < 0.05$) in philtral height, fullness of the lip and width of cupids.

Additionally (at 8 months), there was a very highly significant increase ($P < 0.001$) in nostril height particularly in (group I). No

significant difference between groups was noted in the cupid's height and length of columella as shown in fig.2. At 12 months post-operatively, a highly significant increase ($P < 0.01$) was noted in nostril widths, nostril height, philtrum height and fullness of the lip in (group I) compared to the other groups, while there was no significant difference between groups in the other components (Figure 2).

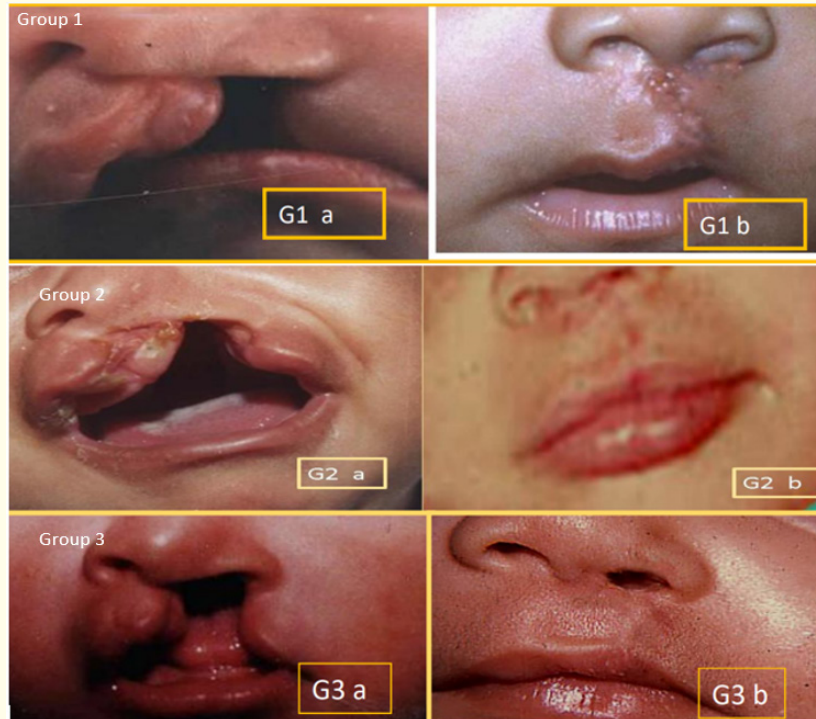

Figure 2: Showing (G1a and b) group 1 preoperative and 14 months post operatively, (G2a and b) group 2 pre and 14 months post operatively, (G3a and b) group 3 pre and 14 months post operatively.

At 14 months post-operatively. A highly significant increase ($P < 0.01$) was noted in nostril widths, nostril height, philtral height and fullness of the lip in (group I) compared to the other groups. While there was no significant difference ($P < 0.05$) between groups and the other lip components. ($F = 30.66$).

Discussion

Correction of cleft lip nasal deformities (CLND) is often unsatisfactory because of problems resulting from cartilage weakness and strong soft tissue forces. Therefore, strong cartilaginous sup-

port, such as rib cartilage, is mandatory [4,5]. The reconstruction of cleft lip deformity has been a subject of considerable attention, and continual search for improving the techniques of closure [9]. Results of the present study showed that, the nostril flap for repairing harelip is a simple one but necessitate surgical experience and could be performed in a reasonable time with no complication. This agreed with [23].

The current work may lend support to previous thought that, results of repaired cleft lip are related to the severity of cleft. The resultant symmetry of repaired cleft lip with mild and moderate

Components	Nostril widths	Nostril height	Philtral height	Fullness of lip	Width of cupid's	Vermillion height	Cupid's height	Length of columella
Groups								
Group I X	6.49 b	6.28 a	8.2 a	6.49 c	2.87 b	6.03 c	1.80 a	5.42 a
S. D	+1.01	+0.74	+1.25	+1.01	+0.44	+0.63	+0.45	+1.01
Group II X	5.84 a	6.45 a	5.44 a	4.28 b	2.44 b	5.62 b	2.04 a	5.28 a
S. D	+0.45	+1.32	+0.81	+0.64	+0.03	+0.66	+0.05	+0.41
Group III X	5.62 a + b	5.44 c	5.46 a	3.87 a + c	1.69 a	3.46 a + c	2.31 a	4.44 b
S. D	+0.87	+0.67	+0.33	+0.09	+0.01	+0.03	+0.03	+0.06

Table 2: Duncan test analysis between 3 groups postoperatively.

S. D= Standard deviation. X= Mean.

groups in this study were promising, while severe cases showed some degree of asymmetry represented by shortening of the cleft side, compared to the non-cleft side. This was in full agreement with Thomson and Reinders [23], who found that the surgical results of repaired cleft lip were related to the severity of preoperative deformity. Moreover, this finding was corroborated with Hotman [13], who found that, the patients in severe category of clefts repaired, had lips that tended to be short, while those with mild category have lips that tended to be long.

Not surprisingly, analysis of the results showed greater improvement of fullness of repaired cleft lip and decrease in disproportion of fullness in operated and non-operated side especially at the third prospective period. This was concurred with the study performed by Vender and Mullilcen [27], who noted that, the discrepancy of lip fullness between the cleft and non-cleft side was decreased with time up to the end of the post-operative follow up lastes. These improvements in fullness of repaired cleft lip seemed to be attributed to technical refinements and experiences as well as adhering to the basic principles of cheiloplasty especially at planning for initial surgery.

Expectedly, application of cleft lip component symmetry index regarding the fullness of repaired lip revealed a more symmetric nostril. The significant improvement of the repaired lip fullness was uncorroborated with the findings of Amaratunga [7], who found that, the repaired lip with rotation advancement flap was thinner at cleft side than the normal one. This could be due to differences in either the surgical technique used for repair or the children's age, which was 9 months in the study of Amaratunga [7].

Regarding the nostril height, the current study showed that, adequate nostril height and symmetry was achieved better with lateral flap in the mild and moderate cases than severe cases. These findings were in accordance with Amaratunga [7], who noted that, the nostril height in cleft side and non cleft side was equal postoperatively.

This study demonstrated that, the nostril width that was nearly three times as wide on the cleft side as on the normal side before repair represented a significant improvement after surgery in all prospective period especially in the child who had smallest degree of deformity. These findings were in accordance with Amaratunga [7] and uncorroborated with [10] who noted that, the child treated by lateral flap, needs nasal revision surgery. This could be due to differences in the method of measurement of nostril width.

Concerning the cleft lip symmetry index for evaluation of nostril component, this study showed an obvious increase in the final gain in nostril at 1, 6 and 12 months postoperatively. This could be explained by avoidance of an incision around the ala of the nose, which might cause limitation of growth of this area due to presence of scar. This finding was in accordance with that of [25].

The current study showed that, the lateral flap creates a more natural contour of the upper lip and a more horizontal portion of Cupid's bow was achieved. Preservation of Cupid's bow height and width in the medial segment in the current study seemed to affect the symmetry of Cupid's bow height and width. This was in agreement with, who claimed that, the advancement of tissues to the other side will produce asymmetry of Cupid's bow height and

width. While it disagreed with that of Mohler [15], who noted that, the rotation of tissues to non-cleft side will lead to symmetry of horizontal position of Cupid's bow. This could be due to difference in the method employed, selection criteria and age of the children.

Clinical observation of the current study showed that, the flap used in cleft lip repair restored the philtral height effectively. Moreover, it was found to be symmetrical in both cleft and non-cleft sides of repaired lip in all prospective periods. This probably is due to the avoidance of perialar incision. This incision was considered as the main cause of ugly scar formation which might interfere with the normal growth of tissue. This was confirmed by Woude D and Mulliken [28].

Conclusion

The anthropometric analysis is a straightforward and easy-to-use tool for describing and analyzing overall cleft lip reconstruction at the end of treatment and post operatively for patients with complete unilateral cleft lip.

Based on the findings of the current study, the following conclusions could be drawn: Lateral columellar flap used for repair of the lip deformity is a simple successful procedure performed in a reasonable time. The proximity of both donor and recipient sites permits rapid flapping without complication or morbidity of the flap. The procedure does not leave behind any noticeable defect. This study shows that the mild and moderate harelip cases could be easily repaired with lateral nostril flap. However severe cleft lip needs more extension and dissection of skin, muscle and mucosa as well as increased length of the flap design. Cleft lip component symmetry index value seemed to be a suitable and reliable measure for the objective assessment of the results of cleft lip repair patients. The flap provides symmetrical lip and nose components studied. There is coherent relation between the degree of preoperative severity and the final outcome of repaired lip.

Bibliography

1. Anna Paradowska-Stolarz., et al. "Current Concepts and Challenges in the Treatment of Cleft Lip and Palate Patients-A Comprehensive Review". *Journal of Personalized Medicine* 12.12 (2022): 2089.
2. Talaat WM., et al. "Anthropometric Analysis of Secondary Cleft Lip Rhinoplasty Using Costal Cartilage Graft". *Journal of Craniofacial Surgery* 30.8 (2019): 2464-2468.
3. Chiang Sarah N., et al. "Unilateral Cleft Lip Repair: Technical Maneuvers to Achieve Vermilion and Mucosal". *Plastic Reconstructive Surgery - Global Open* 10.2 (2022): e4125.
4. Allori AC and Mulliken JB. "Evidence-Based Medicine: Secondary Correction of Cleft Lip Nasal Deformity". *Plastic and Reconstructive Surgery* 140.1 (2007): 166e-176.
5. Farhad Hafezi., et al. "Correction of Cleft Lip Nose Deformity with Rib Cartilage". *Aesthetic Surgery Journal* 33.5 (2013): 662-673.
6. Vyas T., et al. "Cleft of lip and palate: A review". *Journal of Family Medicine and Primary Care* 9.6 (2020): 2621-2625.
7. Amaratunga N. "A comparison of Millard's and LeMesuries's methods of repair of the Cleft Lip using a new index". *Journal of Oral and Maxillofacial Surgery* 46 (1988): 353.
8. Carincl F., et al. "Genetics of non- syndromatic Cleft Lip and palate". *The Cleft Palate Craniofacial Journal* 37 (2000): 33.
9. Court B., et al. "Lip height and lip width after extended Mohler unilateral Cleft Lip repair". *Plastic and Reconstructive Surgery* 111 (2003): 17.
10. Eric S., et al. "Ideal corrective surgery for Cleft Lip patient". *Plastic and Reconstructive Surgery* 5 (2000): 203.
11. Fernandes D and Hudson D. "The modified Z. plasty for unilateral Cleft Lip repair". *British Journal of Plastic Surgery* 46 (1993): 67.
12. Granger B., et al. "Primary correction of unilateral Cleft Lip". *Plastic and Reconstructive Surgery* 110 (2002): 185.
13. Hotman L. "The surgical technique for the Cleft Lip repair". *The Cleft Palate Craniofacial Journal* 5 (1995): 88.
14. John B and Mulliken L. "Principles and techniques of bilateral complete Cleft Lip repair". *Plastic and Reconstructive Surgery* 75 (1996): 477.
15. Lee T. "Upper lip measurements at the time of surgery and follow-up after modified rotation advancement flap repair in unilateral Cleft Lip". *Plastic and Reconstructive Surgery* 104 (1999): 911.

16. Mohler L. "Unilateral Cleft Lip repair". *Plastic and Reconstructive Surgery* 80 (1987): 511.
17. Mortier P and Maertiont V. "Evaluation of the results of Cleft Lip and surgical treatment". *The Cleft Palate Craniofacial Journal* 34 (1997): 247.
18. Nechal P, et al. "Digital two-dimensional photogrammetry: A comparison of three techniques of obtaining digital photographs". *Plastic and Reconstructive Surgery* 103 (1997): 1819.
19. Noordhoff M. "Reconstruction of nostril in unilateral and bilateral Cleft Lips". *Plastic and Reconstructive Surgery* 73(1989):52.
20. Riden K. "Oral and maxillofacial surgery, Cleft Lip and palate". Second ed Bios scientific publishers Bristol UK (1998): 75.
21. Saunders D, et al. "Growth of the Cleft Lip following a triangular flap repair". *Plastic and Reconstructive Surgery* 177 (1986): 227.
22. Slade P, et al. "Relationships between cleft severity and attractiveness with unrepaired cleft". *The Cleft Palate Journal* 32 (1996): 318.
23. Song R, et al. "A new principle for Cleft Lip repair, the lateral columellar flap method". *Plastic and Reconstructive Surgery* 102 (1998): 1848.
24. Steleniki E, et al. "A long term, controlled outcome analysis of in utero versus neonatal Cleft Lip repair using an ovine model". *Plastic and Reconstructive Surgery* 104 (1999): 607.
25. Tardy M, et al. "Facial aesthetic surgery. Second ed Mosby". Chicago London (1995): 24.
26. Thomson H and Reinders F. "Appraisal of the unilateral complete Cleft Lip repair". *Plastic and Reconstructive Surgery* 96 (1995): 549.
27. Vender G and Mullilcen L. "Assessment of repaired unilateral Cleft Lip patient". *The Cleft Palate Craniofacial Journal* 2 (1997): 115.
28. Woude D and Mulliken J. "Effect of lip adhesion on labial height in two-stage repair of complete Cleft Lip". *Plastic and Reconstructive Surgery* 100 (1997): 567.
29. Wikipedia contributors. Classification of cleft lip and cleft palate. In Wikipedia, The Free Encyclopedia 16 (2023): 50.
30. Sadam Elayah, et al. "Primary unilateral incomplete cleft lip repair by a modified rotational advancement technique". *Journal of Stomatology Oral and Maxillofacial Surgery* (2022): 101325.