



## Case Report - Management of Pansinusitis with Periorbital Cellulitis Complicating External Sinus Lifting Procedure

**Nasser Al Alami\***

Specialist Oral and Maxillofacial, Surgery in Department of Oral and maxillofacial surgery EHS, UAE

\*Corresponding Author: Nasser Al Alami, Specialist Oral and Maxillofacial, Surgery in Department of Oral and maxillofacial surgery EHS, UAE.

**Received:** January 03, 2023

**Published:** January 20, 2023

© All rights are reserved by **Nasser Al Alami.**

### Abstract

Perforation of the maxillary sinus membrane is a common complication during sinus lifting procedures (10-40%). Maxillary sinusitis might result and displacement of the graft material may be a contributing factor. Antibiotic Regimes with removal of the implants perforating the sinus have been used for management of sinusitis with immediate or late replacement of the dental implants.

Patient with recurrent severe maxillary, ethmoid and frontal sinusitis attended our center complaining from periorbital cellulitis. She visited multiple ENT clinics for several months with limited improvement on antibiotics and nasal decongestants but the infection was severe and recurrent. CT scan revealed titanium membrane displacement into the maxillary sinus. Drainage was done intra-orally and removal of the titanium membrane. She had history of External sinus lifting procedure right side 9 years ago for placement of 3 implants to replace upper posterior teeth. Patient insisted not to remove the implants being stable and essential for her chewing. She accepted any treatment not involving removal of dental implants without warranty on the result. After curettage of infected bone graft and granulation tissue, sinus membrane was elevated and PRF used to fill the space above the implant apices. The infection resolved completely within 10 days. Follow up of the patient for more than 60 months did not show any recurrence. CT Scan taken after one year shows formation of bony partition between the implants and the maxillary sinus.

**Keywords:** Pansinusitis; Periorbital Cellulitis; Sinus

### Introduction

The most common intraoperative complication of lateral open sinus lifting is perforation of Schneiderian membrane. It has been reported in average 20-25% of sinus augmentation cases.

### Risk factors

- The thickness of the Schneiderian membrane.
- Presence of bony septa in the sinus.
- Height of the alveolar bone
- Surgeon skills and experience

Occurrence of perforation might compromise the viability of the augmented bone and lead to postoperative complication. Sinusitis might be a consequence as a result of bone graft or dental implant infection after contamination of the maxillary sinus by bacteria from the oral cavity. or Sinusitis has been reported in 4.2 to 8.4% of cases after sinus lifting [6].

### Contributing factors

- Blockage of the ostium due to overfilling of the sinus or mucositis
- Interruption of mucosal activity due to large perforation of the membrane.
- Decreased air flow into the sinus.
- Protruding dental implants into the sinus.

### Clinical manifestations

- Purulent drainage around the implants.
- Facial pain and pressure.
- Nasal Congestion.
- Foul smell.
- Ocular pruritis.

It was found that sinusitis is rare after small perforations of the Schneiderian membrane for healthy patients.

Study done on 175 augmented sinuses reported one infection in intact sinuses (115) 0.8% and 3 infections in perforated sinuses (60) 5%. All four infections resolved after culture sensitivity and placement of the patient on an appropriate antibiotic for 10 days. (Avelox -moxifloxacin hydrochloride) ,400 mg daily for 10 days plus Flonase (fluticasone propionate)), two sprays in each nostril daily for 21 days [1].

Intraoperative Complications may lead to postoperative complications, they did not influence implant survival [6].

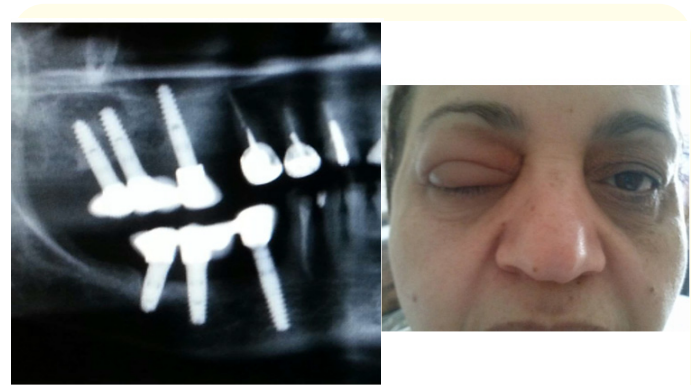Management of sinusitis is complex and might necessitate removal of the graft material and dental implants after control of infection by systemic antibiotic course. Medical management involves systemic antibiotic course, use of nasal douching with saline solution, irrigation of the sinus with antiseptic solution and use of corticosteroids and antihistamine medications. Medical management alone is not predictable on outcome and sinus surgery is indicated if the pathology persists after nonsurgical treatment. Sinus surgery might be performed by endoscopy through the nasal or oral cavity (Functional Endoscopic Sinus Surgery -FESS) or via conventional Cadwell luc osteotomy .It involves irrigation of the sinus and occasionally removal of contaminated bone graft and dental implants.

Chiapasco M proposed treatment protocols based on a combined endoscopic (FESS) and intra-oral surgical approach under general anesthesia. For one out of 20 patients, it was necessary to perform a second combined surgical treatment to treat the persisting sinusitis. Surgery involved co-operation between ENT and Maxillofacial Surgeons [5].

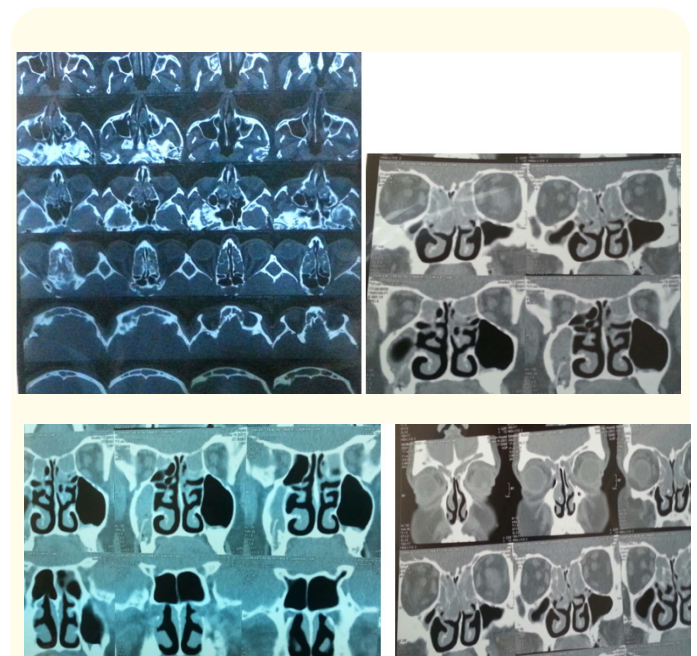
**Case Report**

62 years old patient with recurrent severe maxillary, ethmoid and frontal sinusitis attended our center complaining from periorbital cellulitis. She attended multiple ENT clinics for several months with limited improvement on antibiotics and nasal decongestants but the infection was severe and recurrent. CT scan revealed titanium membrane displacement into the maxillary sinus. She had

history of External sinus lifting procedure right side 9 years ago for placement of 3 implants to replace upper posterior teeth. Patient insisted not to remove the implants being stable and essential for her chewing.



**Figure 1:** Preoperative OPG show dental implants penetrating the maxillary sinus right side and maxillary sinusitis. Clinically patient has periorbital cellulitis closing the right eye, cheek swelling



**Figure 2 and 3:** CT scan Axial and coronal sections showing spread of sinusitis to frontal, ethmoidal sinuses as well as right maxillary sinus which contains radio opaque foreign body.

Drainage was done intraorally and removal of the titanium membrane but infection recurred when patient stopped antibiotics. Treatment plan was discussed with the patient and she refused the traditional treatment to remove the 3 dental implants penetrating the maxillary sinus right side. On the other hand, this case was considered life threatening as periorbital cellulitis can lead to cavernous sinus thrombosis, meningitis, brain abscess and death. An alternative solution was approved by the patient to perform curettage of the infected bone graft and Granulation tissue in the maxillary sinus right side, elevation of the perforated Schneiderian membrane and use of PRF membrane to isolate the dental implant apices from the perforated Schneiderian membrane and maxillary sinus to promote healing. This approach is unique and no high expectations were given to the patient about the success although improvement was anticipated. After 7 days of oral antibiotic Avalox (Moxifloxacin 400mg OD) patient was ready for the procedure. The maxillary sinus was irrigated using diluted antiseptic solution with curettage of infected bone graft and granulation tissue. PRF membranes used to fill the space between the dental implants and the Schneiderian membrane. No collagen membrane used to avoid any unwanted reaction. The plan was to eliminate source of infection and to provide a sort of isolation between the dental implants and the maxillary sinus right side.

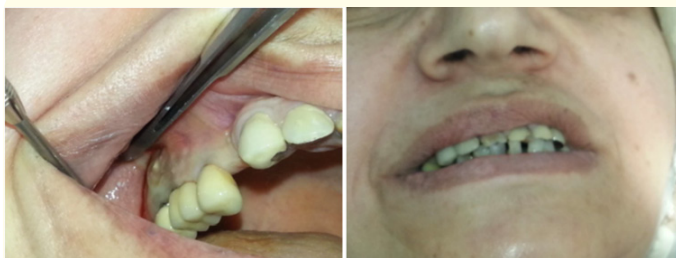

Figure 4

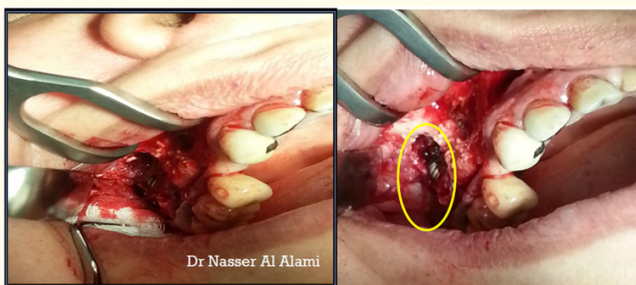


Figure 5

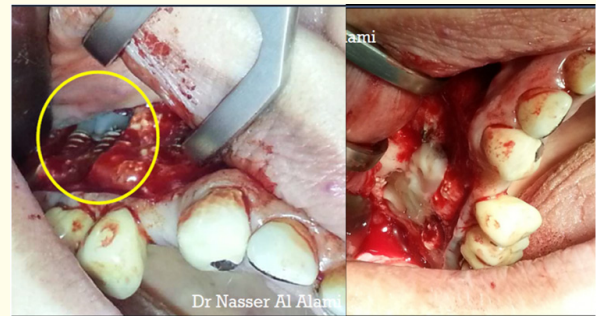


Figure 6

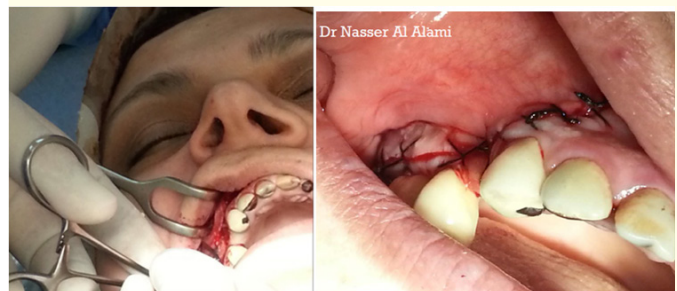


Figure 7

Figures show step by step surgical procedure under antibiotic coverage .Curretage of the maxillary sinus right side and removal of infected bone graft and granulation tissue. Use of PRF after elevation of perforated Schneiderian membrane in the space above dental implants and buccally then suturing

Antibiotic was stopped at 7<sup>th</sup> day postoperatively without any complaint, pain or swelling, and the patient did not develop recurrent infection for more than 6 years. CT SCAN taken 5 months postoperatively showed resolution of sinusitis in the maxillary, ethmoidal and frontal sinuses and healing process around posterior implant apices that were penetrating the maxillary sinus. Patient had normal breathing, smell sensation and foul smell disappeared.

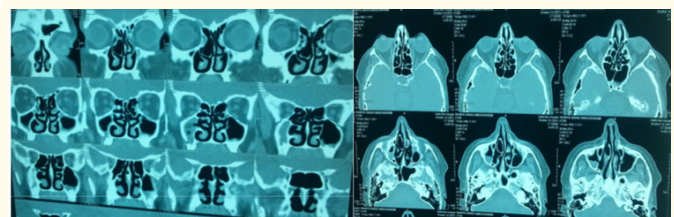
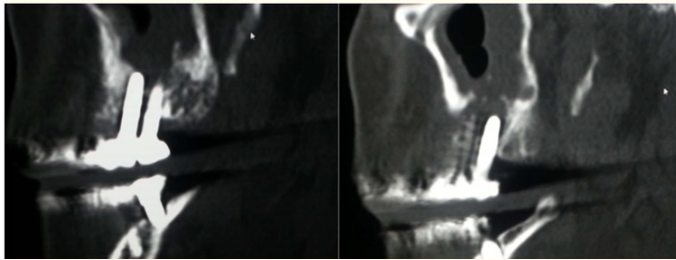
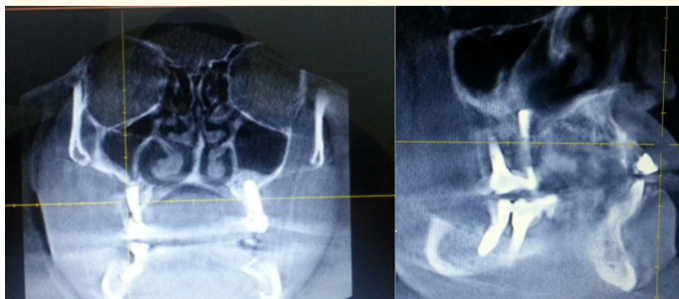


Figure 8



**Figure 9:** Postoperative CT scan after 6 months show resolved sinusitis, clear maxillary, ethmoidal and frontal sinuses. Signs of bone healing around dental implant apices.

CT scan was repeated 12 months postoperatively. Not only all sinuses were clear but also showing bone formation around dental implant apices forming bony partition with the maxillary sinus. Patient was followed for more than 6 years and was free from recurrent sinusitis. No antibiotics were used since then and the patient did not scarify her dental implants.



**Figure 10:** Postoperative CT Scan after 12 month shows bone formation around posterior dental implants right side and formation of bony partition between them and the maxillary sinus.

### Discussion

Maxillary sinusitis may result after perforation of the Schneiderian membrane during sinus lifting procedure. Treatment protocols involve use of antibiotics, FESS procedure and removal of dental implants penetrating the maxillary sinus. FESS procedure aim to curettage the maxillary sinus and remove source of infection. On the other hand a study by Eric and Kraut found that Intraoperative complications during lateral sinus lifting may lead to postoperative complications, but they did not influence implant survival. Treatment of this case was by an alternative approach without using

FESS procedure or scarifying dental implants that were stable and functional. Several studies found that PRF can be used to predictably elevate the sinus floor and in case of perforation, the fibrin matrix can aid in wound closure [2,3]. Dr Ziv Mazor reported that the use of PRF as the sole filling material during a simultaneous sinus lift and implantation stabilized a high volume of natural regenerated bone in the subsinus cavity up to the tip of the implants. Choukroun’s PRF is a simple and inexpensive biomaterial, and its systematic use during a sinus lift seems a relevant option, particularly for the protection of the Schneiderian membrane [4].

Implant removal might subject the patient to excessive trauma and bone loss which will complicate future replacement of dental implants and mandate bone graft. In this case PRF aided in healing of the perforated Schneiderian membrane, bone healing and treatment of the maxillary sinusitis.

This technique need to be evaluated on larger number of cases and to be compared with standard protocols.

### Conclusion

- Preoperative CBCT is Mandatory to evaluate available bone height and thickness and treatment planning.
- Team approach with ENT for case selection, preparation and management of postoperative complications.

### Bibliography

1. Eric Oh DDS and Richard A Kraut DDS. “Effect of Sinus Membrane Perforation on Dental Implant Integration: A Retrospective Study on 128 Patients”. *Implant Dentistry* 20 (2011): 13-19.
2. Diss A., et al. “Osteotome sinus floor elevation using Choukroun’s platelet-rich fibrin as grafting material: A 1-year prospective pilot study with microthreaded implants”. *Oral Surgery, Oral Medicine, Oral Pathology, Oral Radiology, and Endodontology* 105 (2008): 572-579.
3. Choi BH., et al. “The use of autologous fibrin glue for closing sinus membrane perforations during sinus lifts”. *Oral Surgery, Oral Medicine, Oral Pathology, Oral Radiology, and Endodontology* 101 (2006): 150-154.

4. Ziv Mazor. "Sinus floor augmentation with simultaneous implant placement using Choukroun platelet rich fibrin as the sole grafting material: a radiologic and histologic study at 6 months". *Journal of Periodontology* 80 (2009): 2056-2064.
5. M Chiapasco, *et al.* "The treatment of sinusitis following maxillary sinus grafting with the association of functional endoscopic sinus surgery (FESS) and an intraoral approach". *Clinical Oral Implants Research* 24.6 (2013): 623-629.
6. Schwartz AD, *et al.* "The prevalence of surgical complications of the sinus graft procedure and their impact on implant survival". *Journal of Periodontology* 75 (2004): 511-516a.