

The Implications of the Human Immunodeficiency Virus on Oral Health

Lynceia Angel, Adriana Bruzon Sanchez, Crystal Dey* and Dina Harlequin.

School of Dentistry, University of Guyana, Guyana

*Corresponding Author: Crystal Dey, School of Dentistry, University of Guyana, Guyana.

DOI: 10.31080/ASDS.2023.07.1534

Received: November 22, 2022

Published: December 15, 2022

© All rights are reserved by Crystal Dey., et al.

Abstract

Background Information: This systematic review focuses on analyzing scientific data to identify the Implications of the Human Immunodeficiency Virus (HIV) on Oral Health. Oral symptoms that are diagnostic and prognostic of HIV infection are associated. According to anecdotal evidence, the prevalence of oral lesions has decreased after Highly Active Antiretroviral Therapy was introduced (HAART). There were just a few prevalence studies carried out throughout the HAART era.

Significance of Research: Globally, HIV/AIDS has turned into a human and social disaster, affecting developing countries in Africa, Southeast Asia, and Latin America in particular. Due to the worldwide increase in the number of people living with HIV, there is a greater chance for a dental professional, particularly a dentist, to treat a seropositive patient. The advent of HAART has significantly impacted the treatment outcomes seen among HIV seropositive individuals and has revolutionized the treatment of HIV amongst the said population.

Objectives: To review published literature with the purpose of understanding the prevalence and variations of the Oral Health Implications of seropositive adults globally, who are on HAART compared to those who are not on HAART.

Methods: Electronic literature searches were conducted from April 2022 to July 2022, to discover relevant papers that were published. Three investigation systems were utilized in this research: PubMed Central (PMC), Scielo and EbscoHost. A wide number of investigations were found to be "generally relevant" to the research topic. Investigations filtered through the system's electronic database were set from the year 1997 to date.

Each study was graded using a quality assessment instrument given by the National Heart, Lung, and Blood Institute. Preferred Reporting Items for Systematic Reviews and Meta-Analyses (PRISMA) recommendations were followed to evaluate each analysis using standardized methods.

Results: Twenty articles were included in this systematic review which included cross-sectional, retrospective cohort, randomized control, case-control, and comparative studies with a focus on the study's topic. The prevalence and variation of the oral manifestation of HIV was greater in adults aged 18 years and older who were not on HAART as compared to adults aged 18 years and older who were on HAART.

Conclusion: According to this systematic review, Highly Active Antiretroviral Therapy (HAART) may have a positive effect on oral manifestations of HIV in seropositive patients, however, more research is needed to investigate and provide more data on the effect of HAART on oral aspects of HIV.

Keywords: Highly Active Antiretroviral Therapy; HAART; Oral Manifestations; Oral Lesions; Human Immunodeficiency Virus; HIV

Abbreviations

HAART: Highly Active Antiretroviral Therapy; HIV: Human Immunodeficiency Virus; NRTI: Nucleoside Analog Reverse Transcriptase Inhibitors

Introduction

Globally, HIV remains a major public health problem. This issue has been noted mainly in developing countries, especially in Africa, South Asia and Latin America. At the culmination of the year 2020, it was estimated that 37.7 million people were living with HIV (WHO). The Human Immunodeficiency Virus (HIV) invades the body's immune system and is characterized by a gradual and progressive reduction in the number of cluster-differentiated 4 (CD4⁺) T cells which results in increased susceptibility to opportunistic infections that can ultimately lead to the death of the infected individual [1].

When the disease was initially reported in the year 1981, several oral conditions were found to be associated with HIV/AIDS such as oral candidiasis, hairy leukoplakia, Kaposi sarcoma and linear gingival erythema [2]. Also, the manifestation of these oral lesions has been reported to indicate early clinical signs of HIV infection. The World Health Organization's classification of oral manifestations of HIV in Adults breaks the lesions down into three categories. The first category entails "Lesions Strongly Associated with HIV Infection" and includes periodontal diseases like Linear Gingival Erythema, Necrotizing Ulcerative Gingivitis, and Necrotizing Ulcerative Periodontitis as well as Candidiasis (Erythematous and Pseudomembranous types), Hairy Leukoplakia and Kaposi's Sarcoma [3]. The second category involves "Lesions Less Commonly Associated with HIV Infection" for example infections with Mycobacterium species, Melanotic Hyperpigmentation, Necrotizing Ulcerative Stomatitis, Thrombocytopenic Purpura, Salivary Gland Diseases, viral infections (herpes simplex, human papilloma, varicella zoster), and ulcers not otherwise specified [3]. The third category highlights 'Lesions Seen in HIV infection' and include bacterial infections (Actinomyces israelii, E. coli, Klebsiella pneumonia), cat scratch illnesses, medication reactions (lichenoid, ulcerative, toxic epidermolysis, erythema multiforme), epithelioid angiomatosis, fungal infections other than Candida species, neurological disorders (facial palsy, trigeminal neuralgia) and viral infections (cytomegalovirus, Molluscum contagiosum) [3].

These HIV-associated oral lesions have resulted in grave psychological and economic impacts on the affected individuals and their communities. It has been estimated that more than 90% of persons with HIV infection will present with at least one oral manifestation during the disease. In addition, about 50% of people with HIV infection may have oral lesions present and up to 80% of people diagnosed with AIDS will have them present [4].

There are three stages of infection through which HIV positive individuals who are not on treatment usually pass: first, acute HIV infection; second, a period of clinical latency and third, a final increase in viral load with a simultaneous collapse in healthy CD4⁺ T cells during which Acquired Immune Deficiency Syndrome (AIDS) appears [5]. The first stage is the 'Seroconversion Illness', commonly referred to as the Primary or Acute HIV infection and takes place within the first two to ten weeks after exposure to the virus. In this stage, there is a rapid decline in the numbers of CD4⁺ T cells and an increase in the quantity of virus circulating in the blood [6]. Consequently, the infected individuals are usually very contagious and many may present with flu-like symptoms ('About HIV/AIDS: HIV Basics')[7], such as fever, lymphadenopathy, pharyngitis, headaches, and rashes [6]. Common oral manifestations of this stage include erythematous candidiasis, linear gingival erythema, angular cheilitis and oral hairy leukoplakia [4].

The second or chronic stage of HIV infection occurs after the 10th week of being infected. This period of clinical latency involves rapid multiplication of the virus. However, multiplication occurs at a slower rate than in the previous stage resulting in milder symptoms [8]. This period can last anywhere from seven to ten years but the disease progresses differently amongst individuals [5]. The longer seropositive persons go without treatment the further their CD4⁺ T cell count will decline. This is followed by the redevelopment of symptoms which may include skin conditions, weight loss, joint pain, bacterial pneumonia, prolonged diarrhea and night sweats, amongst other opportunistic infections [9]. Oral manifestations are also present and include oral hairy leukoplakia [4].

The third or final stage of HIV infection is known as Acquired Immune Deficiency Syndrome (AIDS). In this stage, the viral load increases rapidly while the CD4⁺ T cell count decreases simultaneously. A count that is lower than 200 cells/mm³, as well as the presence of certain opportunistic infections, indicates a progres-

sion to the third and final stage of HIV infection. The term AIDS was first used in 1982 by the Centre for Disease Control to describe “a disease at least moderately predictive of a defect in cell-mediated immunity, occurring in a person with no known cause for diminished resistance to that disease” (Canadian Foundation for AIDS Research [10]. The common oral manifestations in this stage include pseudomembranous candidiasis, angular cheilitis, necrotizing ulcerative gingivitis, periodontitis, Kaposi’s sarcoma and major and minor aphthous ulcers [4].

Since AIDS was first described, oral manifestations have played an important role in diagnosing the patient and assessing their prognosis. Reports showed that 90% of AIDS patients present with oral manifestations. Thus, dental professionals play a very important role in the early detection of HIV which can result in a reduction of new infections [11].

Triple therapy or Highly Active Antiretroviral Therapy (HAART) was introduced in 1996 and marked the onset of durable effects of drug therapy due to its ability to suppress viral replication and produce genetic barriers against drug resistance [12]. HAART drugs are produced by incorporating protease inhibitors of HIV into the usual AIDS therapy (AZT), this resulted in a dramatic change in the course of the illness and even reduced the mortality and morbidity of patients [13]. Physicians and researchers also noted a decrease in opportunistic infections like *Pneumocystis carinii* [14], oral candidiasis, and progressive multifocal leukoencephalopathy, and infections by *Mycobacterium avium* complex (Currier) [15].

Azidothymidine (AZT) also known as Zidovudine (ZVD) is a part of the class of drugs known as nucleoside reverse transcriptase inhibitors (NRTIs). It was included in a screening program from the National Cancer Institute (NCI) which aimed to identify drugs that could be potentially used to treat HIV/AIDS (National Institute of Allergy and Infectious Diseases) [16]. Though the initial results were quite favourable and impressive the benefits did not last long as it was discovered that viral resistance was taking place the longer the patient took the drug [17]. As other drugs were created and tested the methods of monotherapy and combination therapy for treatment were also acknowledged and explored [18]. Dual-NRTI combination therapy was found to be more effective than monotherapy but it was still only effective for a limited time hence, triple therapy or HAART is marketed as the gold standard for the treatment of HIV [19].

Clinical relevance

Globally, HIV/AIDS has turned into a human and social disaster affecting developing countries in Africa, Southeast Asia and Latin America in particular. Because of the worldwide increase in the number of people living with HIV there is a greater chance for a dental professional particularly the dentist to treat a seropositive patient. Consequently, oral health team members should be increasingly involved in HIV prevention and treatment for individuals with HIV seropositive status [4].

According to Petersen., *et al.* [20], HIV infection has been linked to poor oral health in several studies. In a workshop carried out by Johnson., *et al.* (2006), xerostomia was one example of an oral manifestation that negatively impacted the lives of HIV seropositive adults. For instance, the decreased salivary flow rate may increase the risk of dental caries and cause difficulty in chewing, swallowing and tasting food, while also lowering the quality of life. Approximately 40-50% of HIV-positive persons have oral fungal, bacterial or viral infections that occur early in the course of the disease [20]. Coogan and Sweet [21], highlighted that Pseudomembranous oral candidiasis, oral hairy leukoplakia, HIV gingivitis, periodontitis, Kaposi’s sarcoma and non-lymphoma Hodgkin’s are all oral lesions strongly linked to HIV infection.

The introduction of potent antiretroviral therapy has had a significant impact on clinical care for people infected with HIV [22]. Changes in the immune system and clinical outcomes after such therapy are important considerations for dental clinicians treating HIV patients (Rathbun) [23]. According to Caperna., *et al.* (2012), the term “highly active antiretroviral therapy” (HAART) came from the development of a combination of at least three medications that could suppress HIV viral replication below the level that a viral load test could detect. Most HAART regimens contain at least two of the three antiretroviral drug classes: nucleoside analog reverse transcriptase (RT) inhibitors, non-nucleoside analog RT inhibitors, and protease inhibitors (Shafer and Vuitton) [28].

The co-administration of different drugs that inhibit viral replication by multiple mechanisms such that the propagation of a virus resistant to one agent is inhibited by the action of the other two agents is a key cornerstone of HAART (Eggleton and Nagalli) [13]. HAART has revolutionized HIV-1 disease therapy drastically reducing the rate of mortality and opportunistic infections and increas-

ing the resolution of persistent opportunistic infections. A decrease in the usage of antimicrobial drugs, which results in fewer *C. difficile* infections is another advantage of HAART (Elson and Smith) [26]. Until now, dental practitioners have been looking for methods to enhance the treatment regimens for HIV-positive people. However, understanding the medicines utilized in the management process is critical to better identifying, treating and managing the oral manifestations that negatively influence the lives of seropositive adults on HAART.

The World Health Organization (WHO) has taken several steps to prevent HIV/AIDS-related oral illnesses. The World Health Organization's Oral Health Program has created a handbook that intends to give a systematic approach to the execution of epidemiological studies of oral disorders connected to HIV infection; to provide standards for the collecting, analysis, reporting and distribution of data from such studies and to promote comparison of findings across studies [20]. It also aims to encourage oral health experts and public health practitioners to include oral health status in the management of HIV patients' care and the implementation of oral disease surveillance.

The Global Oral Health Program of the World Health Organization has increased its efforts to prevent HIV/AIDS-related oral diseases. In 2004, a WHO-sponsored meeting on oral health and disease in AIDS in Phuket, Thailand, produced a resolution encouraging national and international health authorities to act [20]. The purpose is to improve oral health promotion and HIV-infected patient care as well as support research on HIV/AIDS, public health activities and surveillance's impact on oral health.

Patients with HIV seropositivity can be detected and provided with appropriate oral care by dental practitioners through identifying and diagnosing the oral manifestations of the HIV disease [24]. Oral manifestations in HIV-positive adults can be reduced with a collaborative effort between the treating Dentist and Medical Physician. Gaurav, *et al.* [25], stated in their article that this collaboration can lead to the selection of an appropriate HAART regimen that works best for the patient.

There are several benefits to using HAART for HIV-infected individuals. This research aims to evaluate the oral health implications of seropositive adults 18 years and older, on highly active antiret-

roviral therapy compared to those who are not. This study will help the relevant authorities particularly those in the Ministry of Health with decision-making about HIV seropositive patients, the use of HAART and its effects on the oral health status of these patients. Changes in public health policy may be influenced by these findings which may potentially lead to free HAART regimens globally. Additional information on the impact of HAART on HIV-infected individuals' oral health status is also provided in this review which serves as a baseline for future investigations. To improve oral health care for HIV-infected patients worldwide new research and activities may be launched by the relevant authorities following this study's findings.

Clinical questions

In the light of the above discussion, our research aims to contribute to accurately documenting the prevalence and variation of oral manifestations of seropositive adults (aged 18 years and older) on Highly Active Antiretroviral Therapy compared to those who are seropositive but who are not on Highly Active Antiretroviral Therapy globally.

- What is the prevalence of oral manifestations in seropositive adults aged 18 years and older on HAART?
- What is the variation of oral manifestations in seropositive adults age 18 years and older on HAART?
- What is the prevalence and variation of oral manifestations in seropositive adults aged 18 years and older on HAART as compared to seropositive adults aged 18 years and older who are not on HAART?
- **P:** Seropositive adults aged 18 years and older
- **I:** Analysis of the prevalence and variation of oral manifestations in seropositive adults age 18 years and older on HAART
- **C:** Comparison of the prevalence and variation of oral manifestations in seropositive adults age 18 years and older on HAART to seropositive adults age 18 years and older who are not on HAART.
- **O:** To evaluate the oral health implications in seropositive adults age 18 years and older globally who are on HAART compared to those who are not on HAART.

Design

This is a systematic review that adheres to the Preferred Reporting Items for Systematic Reviews and Meta-Analyses (PRISMA) guidelines [29].

Eligibility

This study only looked at full-text sources in the English and Spanish languages. Qualitative and quantitative methods were used. Since this systematic review evaluates the oral implications of HIV seropositive adults 18 years and older on HAART, compared to seropositive adults 18 years and older that are not on HAART globally, there were no constraints on location. Cross-sectional, retrospective cohort, randomized control, case-control and comparative studies with a focus on the study’s topic, were all included in this systematic review. Only research that was published within the past 25 years was included in order to ensure that only the most up-to-date materials were cited.

To be eligible for this research, the articles needed to meet the following criteria. Firstly, each article had to include HIV-positive adults 18 years and older. Since this research is centred around that particular age range, it was essential that each article referenced included these adults within their research population. The sole aim of this research is to evaluate the oral implications of HIV on Seropositive adults globally, who are on HAART as compared to those who are Seropositive but are not on HAART. Consequently, in order to be included the subjects had to be HIV Seropositive.

In order to get a representative sample of adults, this study did not restrict participants based on their race, place of origin, or gender. Regardless of region, gender, or ethnicity, any study that examines the impact of HIV on the oral health of seropositive adults on HAART was eligible for inclusion in this review. Another criterion for this research paper included study participants who had been taking HAART for at least three months or who would have had intentions of starting HAART. All studies utilizing human participants had to follow established research ethics guidelines in order to be eligible for this research study. As such, only studies that obtained informed consent from participants were selected for evaluation.

With the criteria outlined in this section, the validity and quality of this systematic review was enhanced while selection bias was significantly reduced.

Information sources and search strategy

Electronic literature searches were conducted from April 2022 to July 2022, to discover possibly relevant papers that had been published. Three investigation systems were utilised in this research: PubMed, Scielo and EbscoHost. A wide number of investigations were found to be “generally relevant” to the research topic. Investigations filtered through the system’s electronic database were set from the year 1997 to date. A thorough analysis and methodology was carried out to choose investigations that best match our inclusion criteria and were considered “significantly relevant” to the research topic. The keywords used for PubMed were “HAART” OR “Highly Active Antiretroviral Therapy” AND “oral lesions” OR “oral manifestations” AND “HIV”. Limiters applied to the search include (1) Language: English, Spanish (2) Age: Adult 19+ years (3) Content Type: Review, Clinical Trial, Meta-Analysis, Randomized Controlled Trial, Systematic Review (4) Publication Date: 1997-2022.

For EbscoHost and SciELO the keywords were the same as PubMed however, the limiters applied to EbscoHost were (1) Publication Date: 1997-2022 (2) Subject: HIV and Highly Active Antiretroviral Therapy and (3) Language: English, Spanish. Table 1 below shows the detailed search strategy utilised for PubMed, SciELO and EbscoHost respectively.

Database	Search Strategy (May to July 2022)
PubMed	HAART) or (highly active antiretroviral therapy) and (oral manifestations) OR (oral lesions) AND (HIV
SciElo	(HAART) or (highly active antiretroviral therapy) and (oral manifestations) OR (oral lesions) AND (HIV)
EbscoHost	(HAART) or (highly active antiretroviral therapy) and (oral manifestations) OR (oral lesions) AND HIV

Table 1: Strategies for the Database Search.

Study selection

The articles that came from the electronic searches done in accordance with the chosen search strategy were scrutinized independently by each of the four reviewers. The papers were evalu-

ated based on the inclusion and exclusion criteria using the title, abstract and full text of each journal. The selection of all papers that were pertinent and thus eligible to be included in this systematic review reduced the number of articles that were produced from the electronic research.

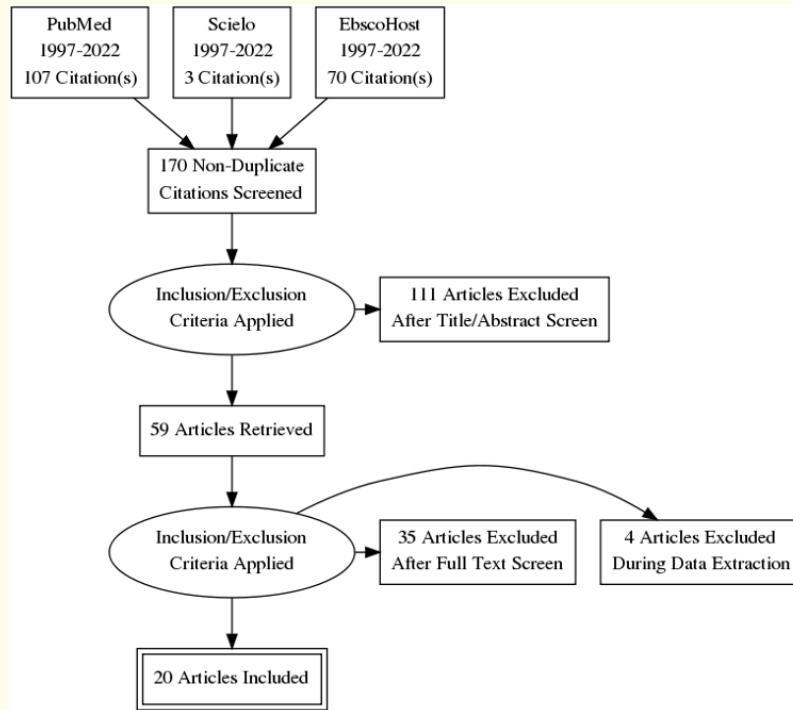


Figure 1: PRISMA Flow Diagram Showing the Identification and Selection of Studies for this Systematic Review.

Study characteristics

	Name of Study	Author, Year of Study	Study Design	No. of P	Age Range (Years)	Inclusion Criteria	Country	Region
1.	Effects of long-term use of HAART on oral health status of HIV-infected subjects	Wipawee., <i>et al.</i> [30]	Cross-sectional Study	207	19-59	HIV Seropositive Adults HAART patients Published within the past 25 years (1997-2022) Language: English Informed Consent	Thailand	Asia
2.	The impact of Highly Active Antiretroviral Therapy (HAART) on the clinical features of HIV - related oral lesions in Nigeria	Taiwo and Hassan [31]	Prospective Cohort Study	142	19-75	HIV Seropositive Adults HAART patients Published within the past 25 years (1997-2022) Language: English Informed Consent	Nigeria	Africa

3.	Prevalence of HIV related oral lesions in people living with HIV and on combined antiretroviral therapy: a Nigerian experience	Eweka., <i>et al.</i> [32]	Cross-sectional Study	491	18-80	HIV Seropositive Adults HAART patients Published within the past 25 years (1997-2022) Language: English Informed Consent	Nigeria	Africa
4.	Oral Lesions in HIV/AIDS Patients Undergoing Highly Active Antiretroviral Treatment Including Protease Inhibitors: A New Face of Oral AIDS?	Salobreña., <i>et al.</i> [1]	Randomized Control Study	154	23-66	HIV Seropositive Adults HAART patients Published within the past 25 years (1997-2022) Language: English Informed Consent	Spain	Europe
5.	Oral lesions and immune status of HIV infected adults from eastern Nepal	Naidu., <i>et al.</i> [33]	Cross Sectional Study	81	20-60	HIV Seropositive Adults HAART patients Published within the past 25 years (1997-2022) Language: English Informed Consent	Nepal	Asia
6.	Oral manifestations of HIV infection in relation to clinical and CD4 immunological status in northern and southern Thai patients	Kerdpon., <i>et al.</i> [34]	Cross Sectional Study	237	21-64	HIV Seropositive Adults HAART patients Published within the past 25 years (1997-2022) Language: English Informed Consent	Southern & Northern Thailand	Asia
7.	Prevalence of Oral Manifestations and Their Association with CD4/CD8 Ratio and HIV Viral Load in South India	Gaurav., <i>et al.</i> [25]	Cross Sectional Study	103	24-68	HIV Seropositive Adults HAART patients Published within the past 25 years (1997-2022) Language: English Informed Consent	Southern India	Asia
8.	Oral manifestations of an HIV positive cohort in the era of highly active anti-retroviral therapy (HAART) in South London	Cooper., <i>et al.</i> [35]	Cross Sectional Study	203	21-68	HIV Seropositive Adults HAART patients Published within the past 25 years (1997-2022) Language: English Informed Consent	London, England	Europe
9.	A real-world, cross sectional study of oral lesions and their association with CD4 cell counts and HIV viral load in Yunnan, China	Shu., <i>et al.</i> [22]	Cross Sectional Study	1812	> 20	HIV Seropositive Adults HAART patients Published within the past 25 years (1997-2022) Language: English Informed Consent	Yunnan, China	Asia

10.	Impact of highly active antiretroviral therapy on oral manifestations of patients with human immunodeficiency virus/ acquired immunodeficiency syndrome in South India	Baddam., <i>et al.</i> [36]	Cross Sectional Study	320	21-40	HIV Seropositive Adults HAART patients Published within the past 25 years Language: English Informed Consent	South India	Asia
11.	Oral lesions among persons with HIV disease with and without highly active antiretroviral therapy in southern India	Umadevi., <i>et al.</i> [37]	Cross Sectional Study	100	>18	HIV Seropositive Adults HAART patients Published within the past 25 years (1997-2022) Language: English Informed Consent	Chennai, South India	Asia
12.	HIV-Related Oral Lesions, Demographic Factors, Clinical Staging and Antiretroviral Use	Amador., <i>et al.</i> [38]	Cross Sectional Observational Study	850	>18	HIV Seropositive Adults HAART patients Published within the past 25 years (1997-2022) Language: English Informed Consent	Mexico City, Mexico	North America
13.	Oral carriage of Candida species in HIV infected patients during highly active antiretroviral therapy (HAART) in Belem , Brazil	Ribeiro., <i>et al.</i> [39]	Cross Sectional Observational Study	246	18-66	HIV Seropositive Adults HAART patients Published within the past 25 years (1997-2022) Language: English Informed Consent	Brazil	South America
14.	Evaluation of Sociodemographic Factors and Prevalence of Oral Lesions in People living With HIV From Cacoal , Rondonia, Amazon Region of Brazil	Da Rocha., <i>et al.</i> [40]	Descriptive Cross- Sectional Study	113	Mean age (39.7)	HIV Seropositive Adults HAART patients Published within the past 25 years (1997-2022) Language: English Informed Consent	Brazil	South America
15.	Lesiones bucales en pacientes con VIH / SIDA asociadas a tratamiento antirretroviral y carga viral	Ricardo., <i>et al.</i> [41]	Cross-Sectional study	166	Mean age (36.1)	HIV Seropositive Adults HAART patients Published within the past 25 years (1997-2022) Language: Spanish Informed Consent	Colombia	South America

16.	Prevalence of oral lesions and the effects of HAART in adult HIV patients attending a tertiary hospital in Lagos, Nigeria	Eweka., <i>et al.</i> [3]	Cross-Sectional Study	114	18-63	HIV Seropositive Adults HAART patients Published within the past 25 years (1997-2022) Language: English Informed Consent	Nigeria	Africa
17.	Orofacial lesions associated with long-term highly active antiretroviral therapy among HIV-seropositive adults in Ibadan, Nigeria	Abe., <i>et al.</i> [42]	Cross Sectional Study	227	18-80	HIV Seropositive Adults HAART patients Published within the past 25 years (1997-2022) Language: English Informed Consent	Nigeria	Africa
18.	Oral lesions frequency in HIV-positive patients at a tertiary hospital, Southern Brazil	Peppes., <i>et al.</i> [43]	Quantitative Case Control Study	449	28-48	HIV Seropositive Adults HAART patients Published within the past 25 years (1997-2022) Language: English Informed Consent	Brazil	South America
19.	Effect of HAART on the Oral Manifestations in Human Immunodeficiency Virus Positive Patients: A Clinical Study, Tiruchirappalli, Tamil Nadu	Selvi., <i>et al.</i> [44]	Cross Sectional Study	240	25-34	HIV Seropositive Adults HAART patients Published within the past 25 years (1997-2022) Language: English Informed Consent	India	Asia
20.	Oral Lesions as Clinical Markers of Highly Active Antiretroviral Therapy Failure: A Nested CaseControl Study in Mexico City	Amador., <i>et al.</i> [45]	Cohort Study	431	Mean age (34.4)	HIV Seropositive adults Patients in HAART therapy Patients with record in database from April 1997-May2005	Mexico	North America

Table 2: Shows the Characteristics of Studies Included in the Systematic Review.

Quality and risk of bias assessment of individual studies

	Name of Study	Author and Publication Year	Quality Assessment	Risk of Bias
1	Effects of long-term use of HAART on oral health status of HIV-infected subjects	Wipawee., <i>et al.</i> [30]	GOOD	Low risk of reporting and selection
2	The impact of Highly Active Antiretroviral Therapy (HAART) on the clinical features of HIV - related oral lesions in Nigeria	Taiwo and Hassan [31]	GOOD	Low risk of performance and attrition
3	Prevalence of HIV related oral lesions in people living with HIV and on combined antiretroviral therapy: a Nigerian experience	Eweka., <i>et al.</i> [32]	GOOD	Low risk of reporting
4	Oral Lesions in HIV/AIDS Patients Undergoing Highly Active Antiretroviral Treatment Including Protease Inhibitors: A New Face of Oral AIDS?	Salobreña., <i>et al.</i> [1]	GOOD	Low risk of attrition
5	Oral lesions and immune status of HIV infected adults from eastern Nepal	Naidu., <i>et al.</i> [33]	GOOD	Low risk of reporting and selection
6	Oral manifestations of HIV infection in relation to clinical and CD4 immunological status in northern and southern Thai patients	Kerdpon., <i>et al.</i> [34]	FAIR	Low risk of attrition
7	Prevalence of Oral Manifestations and Their Association with CD4/CD8 Ratio and HIV Viral Load in South India	Gaurav., <i>et al.</i> [25]	GOOD	Low risk of performance and reporting
8	Oral manifestations of an HIV positive cohort in the era of highly active anti-retroviral therapy (HAART) in South London	Cooper., <i>et al.</i> [35]	GOOD	Low risk of information and selection
9	A real-world, cross sectional study of oral lesions and their association with CD4 cell counts and HIV viral load in Yunnan, China	Shu., <i>et al.</i> [22]	FAIR	Low risk of reporting and information
10	Impact of highly active antiretroviral therapy on oral manifestations of patients with human immunodeficiency virus/ acquired immunodeficiency syndrome in South India	Baddam., <i>et al.</i> [36]	GOOD	Low risk of attrition
11	Oral lesions among persons with HIV disease with and without highly active antiretroviral therapy in southern India	Umadevi., <i>et al.</i> [37]	GOOD	Low risk of performance
12	HIV-Related Oral Lesions, Demographic Factors, Clinical Staging and Antiretroviral Use	Amador., <i>et al.</i> [38]	GOOD	Low risk of reporting
13	Oral carriage of Candida species in HIV infected patients during highly active antiretroviral therapy (HAART) in Belem, Brazil	Ribeiro., <i>et al.</i> [39]	GOOD	Low risk of selection and reporting
14	Evaluation of Sociodemographic Factors and Prevalence of Oral Lesions in People living With HIV From Cacoal, Rondonia, Amazon Region of Brazil	Da Rocha., <i>et al.</i> [40]	GOOD	Low risk of reporting
15	Lesiones bucales en pacientes con VIH/SIDA asociadas a tratamiento antirretroviral y carga viral	Ricardo., <i>et al.</i> [41]	GOOD	Low risk of information
16	Prevalence of oral lesions and the effects of HAART in adult HIV patients attending a tertiary hospital in Lagos, Nigeria	Eweka., <i>et al.</i> [3]	GOOD	Low risk of information
17	Orofacial lesions associated with long-term highly active antiretroviral therapy among HIV-seropositive adults in Ibadan, Nigeria	Abe., <i>et al.</i> [42]	GOOD	Low risk of selection
18	Oral lesions frequency in HIV-positive patients at a tertiary hospital, Southern Brazil	Peppes., <i>et al.</i> [43]	GOOD	Low risk of information
19	Effect of HAART on the Oral Manifestations in Human Immunodeficiency Virus Positive Patients: A Clinical Study, Tiruchirappalli, Tamil Nadu	Selvi., <i>et al.</i> [44]	GOOD	Low risk of attrition
20	Oral Lesions as Clinical Markers of Highly Active Antiretroviral Therapy Failure: A Nested Case-Control Study in Mexico City	Amador., <i>et al.</i> [45]	GOOD	Low risk of reporting

Table 3: Shows the Quality Assessment and Risk of Bias for each study used in this Systematic Review which was done with the aid of the Quality Assessment Tool from the National Heart Lung and Blood Institute (2019) and the Cochrane Collaboration Modified Tool for assessing the Risk of Bias (2011).

Results from individual studies

	Study Author	Lesions Documented
1	Wipawee., <i>et al.</i> [30]	Pseudomembranous Candidiasis, Erythematous candidiasis, Oral Hairy Leukoplakia, Aphthous Ulcers, Linear Gingival Erythema, Melanotic Hyperpigmentation
2	Taiwo and Hassan [31]	Pseudomembranous Candidiasis, Erythematous Candidiasis, Oral Hairy Leukoplakia, Aphthous Ulcers, Linear Gingival Erythema, Melanotic Hyperpigmentation, Angular Cheilitis, Kaposi’s Sarcoma
3	Eweka., <i>et al.</i> [32]	Pseudomembranous Candidiasis, Aphthous Ulcers, Melanotic Hyperpigmentation
4	Salobreña., <i>et al.</i> [1]	Pseudomembranous Candidiasis, Oral Hairy Leukoplakia, Linear Gingival Erythema, Melanotic Hyperpigmentation, Necrotizing Ulcerative Gingivitis
5	Naidu., <i>et al.</i> [33]	Pseudomembranous Candidiasis, Erythematous Candidiasis, Oral Hairy Leukoplakia, Aphthous Ulcers, Linear Gingival Erythema, Melanotic Hyperpigmentation, Angular Cheilitis, Kaposi’s sarcoma, Necrotizing Ulcerative Gingivitis/Necrotizing Ulcerative Periodontitis
6	Kerdpon., <i>et al.</i> [34]	Pseudomembranous Candidiasis, Erythematous Candidiasis, Oral Hairy Leukoplakia, Aphthous Ulcers, Linear Gingival Erythema, Angular Cheilitis, Necrotizing Ulcerative Gingivitis, Necrotizing Ulcerative Periodontitis,
7	Gaurav., <i>et al.</i> [25]	Pseudomembranous Candidiasis, Erythematous Candidiasis, Oral Hairy Leukoplakia, Aphthous Ulcers, Linear Gingival Erythema, Melanotic Hyperpigmentation, Angular Cheilitis Necrotizing Ulcerative Gingivitis, Necrotizing Ulcerative Periodontitis
8	Cooper., <i>et al.</i> [35]	Pseudomembranous Candidiasis, Erythematous Candidiasis, Oral Hairy Leukoplakia, Aphthous Ulcers, Linear Gingival Erythema, Angular CheilitisKaposi’s Sarcoma, Necrotising Ulcerative Gingivitis, Necrotising Ulcerative Periodontitis
9	Shu., <i>et al.</i> [22]	Pseudomembranous Candidiasis, Erythematous Candidiasis, Oral Hairy Leukoplakia, Aphthous Ulcers, Kaposi’s Sarcoma
10	Baddam., <i>et al.</i> [36]	Pseudomembranous Candidiasis, Erythematous Candidiasis, Aphthous Ulcer, Melanotic Hyperpigmentations, Angular Cheilitis
11	Umadevi., <i>et al.</i> [37]	Pseudomembranous Candidiasis, Erythematous Candidiasis, Oral Hairy Leukoplakia, Aphthous Ulcers, Melanotic Hyperpigmentation, Angular Cheilitis
12	Amador., <i>et al.</i> [38]	Pseudomembranous Candidiasis, Erythematous Candidiasis, Oral Hairy Leukoplakia, Linear Gingival Erythema, Angular Chelitis, Kaposi’s Sarcoma, Necrotizing Ulcerative Gingivitis, Necrotizing Ulcerative Periodontitis
13	Ribeiro., <i>et al.</i> [39]	Pseudomembranous Candidiasis
14	Da Rocha., <i>et al.</i> [40]	Pseudomembranous Candidiasis, Oral Hairy Leukoplakia, Aphthous Ulcers, Linear Gingival Erythema
15	Ricardo., <i>et al.</i> [41]	Pseudomembranous Candidiasis, Linear Gingival Erythema
16	Eweka., <i>et al.</i> [3]	Pseudomembranous Candidiasis, Oral Hairy Leukoplakia, Aphthous Ulcers, Linear Gingival Erythema, Melanotic Hyperpigmentation, Necrotising Ulcerative Periodontitis
17	Abe., <i>et al.</i> [42]	Pseudomembranous Candidiasis, Aphthous Ulcers, Melanotic Hyperpigmentation, Necrotizing Ulcerative Periodontitis
18	Peppes., <i>et al.</i> [43]	Aphthous Ulcers
19	Selvi., <i>et al.</i> [44]	Pseudomembranous Candidiasis, Erythematous Candidiasis, Aphthous Ulcers, Melanotic Hyperpigmentation, Angular Cheilitis
20	Amador., <i>et al.</i> [45]	Pseudomembranous Candidiasis, Hairy Leukoplakia, Aphthous Ulcers

Table 4: Shows the Oral Lesions documented in each article included within this systematic review, highlighting the names of each author along with the study year.

Synthesis of results

Figure 2: Shows the distribution of oral manifestations of HIV within the two study populations (HAART patients and Non-HAART patients) in percentages. Amongst the patients on a HAART regimen, Melanotic Hyperpigmentation and Pseudomembranous Candidiasis were found to be the most prevalent oral manifestations, with 12.3% and 12% respectively, while Kaposi's Sarcoma and Necrotizing Ulcerative Gingivitis (NUG) were the least prevalent with 2% and 2.3% respectively. On the contrary, the most prevalent oral manifestations amongst the patients not on a HAART regimen were Erythematous Candidiasis and Pseudomembranous Candidiasis with 8.5% and 7% respectively, while Kaposi's Sarcoma and Necrotizing Ulcerative Periodontitis (NUP) were the least prevalent with 0.5% and 1.5% respectively.

Figure 3: Shows the variation of oral manifestations across the study population in percentage. The variation of lesions was calculated and the following could be concluded: Pseudomembranous Candidiasis accounted for 28% of all oral manifestations within the study population, followed by Erythematous Candidiasis (18.7%) and Oral Hairy Leukoplakia (16%).




Figure 4: Details the male-to-female ratio and mean age of the participants of each study included in this research. There were a total of 3,847 male and 2,839 female participants while the mean age per study ranged from 34 to 44.7 years.




Figure 5: Shows the variation of oral manifestations across the various studies included in this systematic review. 20 studies reported on Pseudomembranous Candidiasis, 12 on Erythematous Candidiasis, Linear Gingival Erythema and Melanotic Hyperpigmentation, 8 on Angular Cheilitis, 14 on Aphthous Ulcers, 6 on Necrotizing Ulcerative Gingivitis, 7 on Necrotizing Ulcerative Periodontitis, 13 on Oral Hairy Leukoplakia and 6 on Kaposi's Sarcoma.

Discussion and Results

Summary of evidence

Prevalence of oral manifestations

Figure 2 shows the prevalence of oral manifestations between the HAART and non-HAART populations. Amongst the patients on a HAART regimen, Melanotic Hyperpigmentation and Pseudomembranous Candidiasis were found to be the most prevalent oral manifestations, with 12.3% and 12% respectively. While Kaposi's

Sarcoma and Necrotizing Ulcerative Gingivitis (NUG) were the least prevalent with 2% and 2.3% respectively. On the contrary, the most prevalent oral manifestations amongst the patients not on a HAART regimen were Erythematous Candidiasis and Pseudomembranous Candidiasis with 8.5% and 7% respectively. Kaposi's Sarcoma and Necrotizing Ulcerative Periodontitis (NUP) were the least prevalent with 0.5% and 1.5% respectively. Wipawee., *et al.* [30] highlighted

that the most common side effect of HAART regimen among the seropositive population is Melanotic Hyperpigmentation, so the high prevalence among the HAART study population is of no surprise.

It is generally known that the introduction and usage of HAART reduces the frequency and severity of opportunistic illnesses in HIV-infected individuals [46]. It has been shown that Oral Candidiasis in people with HIV tends to occur less frequently and does not reoccur as often when a protease inhibitor medication is used. The usage of protease inhibitors was discovered to be connected to a decline in Oral Candidiasis prevalence with the introduction of HAART drugs [30], especially since protease inhibitors are a major component of the HAART cocktail [47]. Given that figure 2 shows a higher prevalence of both forms of Candidiasis in the HAART groups, one must consider the length of time the patients spent on HAART. In research from Baddam, *et al.* [36], patients on HAART showed a significant reduction in both forms of Oral Candidiasis after a period of 3 months, this was reinforced by studies by Taiwo and Hassan [31] and by Umadevi, *et al.* [37] in 2007.

HIV related oral lesions with neoplastic and auto-immune clinical characteristics, such as oral Kaposi's Sarcoma and Melanotic Hyperpigmentation, were found to respond to HAART more slowly which accounts for the high prevalence of Kaposi Sarcoma in the HAART study population. In research from Taiwo and Hassan [31], it was observed that throughout their study period of 5 months none of the Kaposi Sarcoma lesions were completely resolved and they suggested that this could be attributed to the size of the lesions as well as the length of time they were on HAART. Additionally, Shu, *et al.* [22] would have attributed this high prevalence of Kaposi Sarcoma in the HAART seropositive adults to the difference in ethnicity among the study population as well as the size of the lesions observed in participants. They postulated that the larger the size of the lesions observed in Kaposi Sarcoma, the longer the regression period. This reinforces the findings of Taiwo and Hassan [31].

Few authors have demonstrated that patients using HAART have significantly less periodontal problems, with HAART patients showing a prevalence of 2.3% and 2.9% for NUG and NUP respectively, compared to their Non-HAART counterparts who had prevalence rates of 3% and 1.5%. They view this as a crucial predictive and diagnostic element. This decrease in incidence is brought

about by the fact that opportunistic pathogens are often the root cause of periodontal disorders in HIV patients, and that HAART patients' higher CD4+ counts prevent the colonization of these microbes [36].

Figure 5 conveys the prevalence of oral manifestations of HIV among the study population of seropositive adults from the 20 studies in relation to the continent. The prevalence of oral manifestations was calculated to the nearest whole number and the following could be concluded: Asia accounted for the highest prevalence of oral manifestations followed by North America while Africa and South America had the lowest prevalence of oral manifestations reported. In the continent of Asia, Melanotic Hyperpigmentation was the most prevalent lesion followed by Erythematous and Pseudomembranous Candidiasis while the least prevalent lesion was Kaposi's Sarcoma.

North America's most prevalent lesions were Oral Hairy Leukoplakia and Erythematous Candidiasis while the least prevalent were Linear Gingival Erythema and Aphthous Ulcers. In Europe, Pseudomembranous Candidiasis and Oral Hairy Leukoplakia were the most prevalent while Kaposi's Sarcoma and Erythematous Candidiasis were the least prevalent. In the continent of Africa, Pseudomembranous Candidiasis was the most prevalent lesion followed by Aphthous Ulcers while the least prevalent lesion was Kaposi's Sarcoma. Finally, in the continent of South America, Pseudomembranous Candidiasis was the most prevalent and the least prevalent was Oral Hairy Leukoplakia.

The Asian studies recorded a total of 1,299 lesions which is 52.98% of the lesions recorded from all of the studies included in this systematic review. Asia accounted for 3,100 of the participants, a whopping 46.37% of the entire study population, so it is a safe assumption that the large numbers of lesions recorded from that continent is resulting from the large population size.

Variation of oral manifestations

Figure 3 shows the variation of oral manifestations across the study population in percentage. The variation of lesions was calculated and the following could be concluded: Pseudomembranous Candidiasis accounted for 28% of all oral manifestations within the study population, followed by Erythematous Candidiasis (18.7%) and Oral Hairy Leukoplakia (16%).

Figure 7 shows the variation of oral manifestations across the various studies included in this systematic review. 20 studies reported on Pseudomembranous Candidiasis, 12 on Erythematous Candidiasis, Linear Gingival Erythema and Melanotic Hyperpigmentation, 8 on Angular Cheilitis, 14 on Aphthous Ulcers, 6 on Necrotizing Ulcerative Gingivitis, 7 on Necrotizing Ulcerative Periodontitis, 13 on Oral Hairy Leukoplakia and 6 on Kaposi's Sarcoma.

Recommendations

Considering the fact that HIV is a serious public health issue globally coupled with oral health implications, the following recommendations would assist in reducing the impact of HIV on oral health

- **Improving Access to Care for Seropositive Patients:** access to health care for HIV/AIDS patients is a moral obligation that is intimately tied to human rights. The ultimate objective is to ensure universal access to treatment for all HIV/AIDS patients, and geographical differences in the ability to administer medications should be recognized in various parts of the world. As a result, locally devised treatment programs based on epidemiological, economic, and political considerations should be amplified as soon as possible.

The act of granting subsidies can be implemented to help ease the burden of transportation to and from health care facilities. Linkages with social sector programs for accessing social support to patients, recreational and skill development support, transportation subsidy to ensure HAART care, and integrating nutritional support within treatment regimens are some strategies that can be implemented to ensure better care and quality of life for these patients. It is equally critical to emphasize that these programs should not jeopardize optimal clinical practices. Last but not least, concurrent programs aimed at combating stigma and discrimination are required to remove these barriers to accessing care.

- **Increased Public Awareness of the Oral Implications of HIV:** people afflicted with HIV must be educated, motivated, and equipped with knowledge in order to protect themselves from the devastating effects of HIV. The actual scope of the HIV/AIDS pandemic can only be determined if the population gets tested regularly and seek treatment if they have tested positive. However, by the time many individuals seek treatment, their HIV condition would have progressed to AIDS. Therefore, increased public awareness of the disease is required. In this setting, countries should be urged to strengthen HIV/AIDS diagnostic systems.

Voluntary counselling and testing (VCT) services must be expanded urgently in order to reduce high-risk behavior, improve blood transfusion safety, and facilitate timely access to opportunistic infection prophylaxis and the Highly Active Antiretroviral Therapy (HAART). Enhancing Healthcare Team Outcomes and Oral Health Status of Seropositive Adults: Increasing the collaboration and communication among members of the interprofessional team will enable optimal selection of Highly Active Antiretroviral Therapy (HAART) regimens to enhance HIV-positive patient outcomes. Consequently, improving the oral health status of HIV seropositive adults.

- **Oral Health Education and Promotion:** This systematic review revealed that there was a high prevalence of oral manifestations of HIV observed among seropositive adults. As such, more oral health promotion initiatives should be devised and implemented for people diagnosed and living with HIV. Subsequently, many people are ignorant of the need for excellent oral hygiene habits and the serious effects of poor oral health on their overall health. Thus, oral health promotion should be done on a regular basis to enhance public awareness.

To promote oral health sufficiently, government health agencies including the dental health care sector should use print media (e.g., newspapers) and broadcast news (e.g., radio and television), as well as the internet (e.g., social media platforms such as Instagram, Facebook, and Twitter). Oral Health Promotion, Prevention and Education programs should be conducted to increase oral health knowledge among seropositive adults. Additionally, HIV seropositive patients should be motivated to eventually change their personal behavior towards oral health and seek regular professional oral hygiene care from licensed Dental Practitioners.

- **Implementation of Clinical Research of the Oral Health Implications of HIV:** The number of research on oral manifestations undertaken in Asia was considerable but there is unequal distribution with the majority of studies conducted in India and Thailand. Furthermore, evidence on oral symptoms in HIV/AIDS infected populations is confined to the Middle East, China, and Japan. Therefore, additional research investigations must be carried out in these areas.

However, to precisely determine the prevalence of individual oral manifestations, studies must be longitudinal and multicentric, where all of the study participants would be HIV seropositive patients with oral lesions who are then placed on a HAART regi-

men and then monitored over a predetermined period of time. Microbiological components of research, such as the identification of candida species strains, should be prioritized in industrialized countries.

At least two examiners should perform the intraoral examination on patients: A single examiner may be influenced by HIV status, and there is always a danger of bias for overdiagnosis of HIV-related oral lesions, particularly Oral Hairy Leukoplakia (OHL). Therefore, two examiners should perform the intraoral examination with blinding towards the HIV status of patients in order to accurately determine the prevalence of oral manifestations within said study population.

Limitations

Several constraints were encountered throughout data collection, influencing the validity, informativeness, and review process of this research. Firstly, some of the studies could not provide clear definitions for major terminologies used, hence their data for some subtopics could not be included in this systematic review.

As mentioned throughout this systematic review, differences in the sample size of individuals in trials might skew the similar research of this survey. Throughout the research and discussion, an unusual effort was made to refer to this inconsistency. Reference to figure 5 where the prevalence of Oral Manifestations of HIV was represented across continents, shows how the sample size greatly affected the results of this systematic review. The continent of Asia held the largest study population which resulted in Asia having the highest prevalence of Oral Manifestations of HIV.

Another limitation discovered was the researchers' failure to identify confounding factors among subjects. Some studies failed to adequately state the number of participants while others failed to mention the number of oral lesions present in the HAART and non-HAART seropositive population explicitly. Additionally, the studies did not explore age or gender based oral manifestations. Consequently, this lack of representation ultimately restricted the true interpretation of the results. The study search was limited to only English and Spanish languages, journals, and full free access research papers. Thus, limiting the extensiveness of this systematic review.

Lastly, investigators conducted studies in various time periods and research settings. Furthermore, various studies with different study populations were used. Despite the fact that the population were all adults, the included studies focused on different age groups. As a result, the generalizability of the data obtained may be questionable.

Conclusion

This systematic review recognized that the HIV/AIDS pandemic is a serious public health issue globally, one which is coupled with oral health implications. The prevalence and variation of the oral manifestations in HIV seropositive individuals varied across the geographic locations. As it relates to the prevalence of oral manifestations among the different continents, Asia accounted for the highest prevalence of oral manifestations followed by North America while Africa and South America had the lowest prevalence of oral manifestations reported, while Pseudomembranous Candidiasis accounted for the majority of all oral manifestations within the study population, closely followed by Erythematous Candidiasis and Oral Hairy Leukoplakia.

While the evidence does point towards a positive effect, there were not enough longitudinal studies done on this topic to accurately infer the effect of HAART on the oral manifestations of HIV. Thus, more research is needed to investigate and provide more data on the effect of Highly Active Antiretroviral Therapy on the oral manifestations of HIV in seropositive patients. This would greatly assist health professionals and policy makers in planning and implementing strategies for the overall reduction of HIV related oral manifestations and increase the comfort, immune status and quality of life of HIV positive patients both locally and worldwide.

Acknowledgment

The researchers would like to thank God for giving us the strength, wisdom and resources needed to successfully overcome every challenge faced during the entire process of conducting our systematic review.

Acknowledgements and the warmest thanks are given to our supervisor Dr. Dina Harlequin BDS, MPH who made the initiation

and completion of this systematic review possible. Her guidance, commitment and invaluable knowledge helped the researchers through every step of this paper. We would also like to thank the examiners who will be sitting on the panel, for taking their time to read our thesis.

To our family members who supported us throughout the trials and hurdles of this project and the entire journey through dental school, we thank you for your love, encouragement and patience.

And lastly, a debt of gratitude is owed to Mr. Dwayne Renville of the University of Guyana- Department of Mathematics, Physics and Statistics, Ms. Meshonn Persaud and Ms. Shania Noel of the Hugh Wooding Law School, Dr. Darryl Watson, BDS and Dr. Ghansham Samaroo, BDS for their encouragement and advice which positively impacted this research.

Conflict of Interest

The Authors declare that there is no conflict of interest.

Bibliography

1. Ceballos-Salobreña Alejandro., *et al.* "Oral Lesions in HIV/AIDS Patients Undergoing Highly Active Antiretroviral Treatment Including Protease Inhibitors: A New Face of Oral AIDS?" *AIDS Patient Care and STDs* 14.12 (2000): 627-635.
2. Pakfetrat A., *et al.* "Oral Manifestations of Human Immunodeficiency Virus-infected Patients". *Iranian Journal of Otorhinolaryngology* 27.78 (2015): 25745611.
3. Aškinytė D., *et al.* "Oral Manifestations of HIV Disease: A Review". *Stomatologija* 17.1 (2015): 21-28.
4. Eweka OM., *et al.* "Prevalence of Oral Lesions and the Effects of HAART in Adult HIV Patients Attending a Tertiary Hospital in Lagos, Nigeria". *Open Journal of Stomatology* 2.3 (2012): 200-205.
5. Fauci Anthony S. "HIV And AIDS: 20 Years of Science". *Nature Medicine* 9.7 (2003): 839-843.
6. Hernandez-Vargas., *et al.* "Modeling the Three Stages in HIV Infection". *Journal of Theoretical Biology* 320 (2013): 33-40.
7. "About HIV/AIDS: HIV Basics". *Center for Disease Control* 16 (2018).
8. The Stages of HIV Infection | NIH". *National Institute of Health* (2021).
9. Pebody R. "About HIV". *AIDS Map* (2020).
10. "History of HIV/AIDS". *Canadian Foundation for AIDS Research (CANFAR)* (2020).
11. Campo-Trapero Julián., *et al.* "Dental Management of Patients with Human Immunodeficiency Virus". *Quintessence International* 34. 7 (1985): 515-525.
12. Hammer Scott M., *et al.* "A Controlled Trial of Two Nucleoside Analogues Plus Indinavir in Persons with Human Immunodeficiency Virus Infection and CD4 Cell Counts of 200 per Cubic Millimeter or Less". *New England Journal of Medicine* 337.11 (1997): 725-733.
13. Eggleton Julie S and Shivaraj Nagalli. "Highly Active Antiretroviral Therapy (HAART)". *StatPearls* (2022).
14. Morris Alison., *et al.* "Improved Survival with Highly Active Antiretroviral Therapy in HIV-infected Patients with Severe Pneumocystis Carinii Pneumonia". *AIDS, Ovid Technologies (Wolters Kluwer Health)* 17.1 (2003): 73-80.
15. Currier Judith S. "Opportunistic Infections in the Age of Highly Active Antiretroviral Therapy". *AIDS Patient Care and STDs* 12.7 (1998): 521-525.
16. National Institute of Allergy and Infectious Diseases. "Dictionary of Cancer Terms". National Cancer Institute (2011).
17. Larder Bredan A., *et al.* "HIV With Reduced Sensitivity to Zidovudine (AZT) Isolated During Prolonged Therapy". *Science* 243 (1989): 1731-1734.
18. Schooley RT., *et al.* "Virologic and Immunologic Benefits of Initial Combination Therapy with Zidovudine and Zalcitabine or Didanosine Compared with Zidovudine Monotherapy". *Journal of Infectious Diseases* 173.6 (1996): 1354-1366.
19. Gallant Joel E., *et al.* "Early Virologic Nonresponse to Tenofovir, Abacavir, and Lamivudine in HIV-Infected Antiretroviral-Naive Subjects". *The Journal of Infectious Diseases* 192.11 (2005): 1921-1930.

and completion of this systematic review possible. Her guidance, commitment and invaluable knowledge helped the researchers through every step of this paper. We would also like to thank the examiners who will be sitting on the panel, for taking their time to read our thesis.

To our family members who supported us throughout the trials and hurdles of this project and the entire journey through dental school, we thank you for your love, encouragement and patience.

And lastly, a debt of gratitude is owed to Mr. Dwayne Renville of the University of Guyana- Department of Mathematics, Physics and Statistics, Ms. Meshonn Persaud and Ms. Shania Noel of the Hugh Wooding Law School, Dr. Darryl Watson, BDS and Dr. Ghansham Samaroo, BDS for their encouragement and advice which positively impacted this research.

Conflict of Interest

The Authors declare that there is no conflict of interest.

Bibliography

1. Ceballos-Salobreña Alejandro., *et al.* "Oral Lesions in HIV/AIDS Patients Undergoing Highly Active Antiretroviral Treatment Including Protease Inhibitors: A New Face of Oral AIDS?" *AIDS Patient Care and STDs* 14.12 (2000): 627-635.
2. Pakfetrat A., *et al.* "Oral Manifestations of Human Immunodeficiency Virus-infected Patients". *Iranian Journal of Otorhinolaryngology* 27.78 (2015): 25745611.
3. Aškinytė D., *et al.* "Oral Manifestations of HIV Disease: A Review". *Stomatologija* 17.1 (2015): 21-28.
4. Eweka OM., *et al.* "Prevalence of Oral Lesions and the Effects of HAART in Adult HIV Patients Attending a Tertiary Hospital in Lagos, Nigeria". *Open Journal of Stomatology* 2.3 (2012): 200-205.
5. Fauci Anthony S. "HIV And AIDS: 20 Years of Science". *Nature Medicine* 9.7 (2003): 839-843.
6. Hernandez-Vargas., *et al.* "Modeling the Three Stages in HIV Infection". *Journal of Theoretical Biology* 320 (2013): 33-40.
7. "About HIV/AIDS: HIV Basics". *Center for Disease Control* 16 (2018).
8. The Stages of HIV Infection | NIH". *National Institute of Health* (2021).
9. Pebody R. "About HIV". *AIDS Map* (2020).
10. "History of HIV/AIDS". *Canadian Foundation for AIDS Research (CANFAR)* (2020).
11. Campo-Trapero Julián., *et al.* "Dental Management of Patients with Human Immunodeficiency Virus". *Quintessence International* 34. 7 (1985): 515-525.
12. Hammer Scott M., *et al.* "A Controlled Trial of Two Nucleoside Analogues Plus Indinavir in Persons with Human Immunodeficiency Virus Infection and CD4 Cell Counts of 200 per Cubic Millimeter or Less". *New England Journal of Medicine* 337.11 (1997): 725-733.
13. Eggleton Julie S and Shivaraj Nagalli. "Highly Active Antiretroviral Therapy (HAART)". *StatPearls* (2022).
14. Morris Alison., *et al.* "Improved Survival with Highly Active Antiretroviral Therapy in HIV-infected Patients with Severe Pneumocystis Carinii Pneumonia". *AIDS, Ovid Technologies (Wolters Kluwer Health)* 17.1 (2003): 73-80.
15. Currier Judith S. "Opportunistic Infections in the Age of Highly Active Antiretroviral Therapy". *AIDS Patient Care and STDs* 12.7 (1998): 521-525.
16. National Institute of Allergy and Infectious Diseases. "Dictionary of Cancer Terms". National Cancer Institute (2011).
17. Larder Bredan A., *et al.* "HIV With Reduced Sensitivity to Zidovudine (AZT) Isolated During Prolonged Therapy". *Science* 243 (1989): 1731-1734.
18. Schooley RT., *et al.* "Virologic and Immunologic Benefits of Initial Combination Therapy with Zidovudine and Zalcitabine or Didanosine Compared with Zidovudine Monotherapy". *Journal of Infectious Diseases* 173.6 (1996): 1354-1366.
19. Gallant Joel E., *et al.* "Early Virologic Nonresponse to Tenofovir, Abacavir, and Lamivudine in HIV-Infected Antiretroviral-Naive Subjects". *The Journal of Infectious Diseases* 192.11 (2005): 1921-1930.

20. Petersen PE. "Policy for Prevention of Oral Manifestations in HIV/AIDS: The Approach of the WHO Global Oral Health Program". *Advances in Dental Research* 19.1 (2006): 17-20.
21. Challacombe SJ., et al. "Overview of the Fourth International Workshop on the Oral Manifestations of HIV Infection". *Oral Diseases* 8 (2002): 9-14.
22. Shu Wen., et al. "A Real-world, Cross Sectional Study of Oral Lesions and Their Association With CD4 Cell Counts and HIV Viral Load in Yunnan, China". *Medicine* 99.40 (2020). e22416.
23. R Chris Rathbun. "Antiretroviral Therapy for HIV Infection: Overview". FDA-Approved Antivirals and Regimens, Complete Regimen Combination ARTs (2022).
24. Leao JC., et al. "Oral complications of HIV disease". *Clinics* 64.5 (2009).
25. Gaurav Sharma, et al. "Prevalence of Oral Manifestations and Their Association with CD4/CD8 Ratio and HIV Viral Load in South India". *International Journal of Dentistry* (2011): 1-8.
26. Elson CO and Smith PD. "Immunologic disease of the gastrointestinal tract". *Clinical Immunology* (2008): 1099-1114.
27. Vanangamudi M. "Non-nucleoside reverse transcriptase inhibitors (NNRTIs): a brief overview of clinically approved drugs and combination regimens". *Current Opinion in Pharmacology* 54 (2020): 179-187.
28. Shafer R and Vuitton D. "Highly active antiretroviral therapy (Haart) for the treatment of infection with human immunodeficiency virus type 1". *Biomedicine and Pharmacotherapy* 53.2 (1999): 73-86.
29. Page Matthew J., et al. "The PRISMA 2020 Statement: An Updated Guideline for Reporting Systematic Reviews". *BMJ* (2021): n71.
30. Nittayananta, Wipawee, et al. "Effects of Long-term Use of HAART on Oral Health Status of HIV-infected Subjects". *Journal of Oral Pathology and Amp; Medicine* (2010).
31. Taiwo Olaniyi O and Zuwaira Hassan. "The Impact of Highly Active Antiretroviral Therapy (HAART) on the Clinical Features of HIV - Related Oral Lesions in Nigeria". *AIDS Research and Therapy* 7.1 (2010): 19.
32. Mary Eweka Olutola., et al. "Prevalence of HIV Related Oral Lesions in People Living with HIV and on Combined Antiretroviral Therapy: A Nigerian Experience". *Pan African Medical Journal* 31 (2018).
33. Naidu SG., et al. "Oral Lesions and Immune Status of HIV Infected Adults from Eastern Nepal". *Journal of Clinical and Experimental Dentistry, Medicine Oral, S.L* (2013): e1-7.
34. Kerdpon D., et al. "Oral Manifestations of HIV Infection in Relation to Clinical and CD4 Immunological Status in Northern and Southern Thai Patients". *Oral Diseases* 10.3 (2004): 138-144.
35. JD Eyeson., et al. "Oral Manifestations of an HIV Positive Cohort in the Era of Highly Active Anti-retroviral Therapy (HAART) in South London". *Journal of Oral Pathology and Amp; Medicine* 31.3 (2002): 169-174.
36. Chitturi RaviTeja, et al. "Impact of Highly Active Antiretroviral Therapy on Oral Manifestations of Patients with Human Immunodeficiency Virus/Acquired Immuno Deficiency Syndrome in South India". *Indian Journal of Sexually Transmitted Diseases and AIDS* 36.1 (2015): 35.
37. Umadevi KMR., et al. "Oral Lesions Among Persons with HIV Disease With and Without Highly Active Antiretroviral Therapy in Southern India". *Journal of Oral Pathology and Amp; Medicine* 36.3 (2007): 136-141.
38. Ramírez-Amador Velia., et al. "HIV-Related Oral Lesions, Demographic Factors, Clinical Staging and Anti-Retroviral Use". *Archives of Medical Research* 37.5 (2006): 646-654.
39. Ribeiro Ribeiro André Luis., et al. "Oral Carriage of *Candida* Species in HIV-infected Patients During Highly Active Antiretroviral Therapy (HAART) in Belém, Brazil". *Oral Surgery, Oral Medicine, Oral Pathology and Oral Radiology* 120.1 (2015): 29-33.
40. Rocha Graziela de Carvalho Tavares da., et al. "Evaluation of Sociodemographic Factors and Prevalence of Oral Lesions in People Living with HIV From Cacoal, Rondônia, Amazon Region of Brazil". *International Journal of Environmental Research and Public Health* 19.5 (2022): 2614.

41. Jiménez Malagón MC., *et al.* "Manifestaciones Orales En Pacientes VIH/SIDA Asociadas a Tratamiento Antirretroviral Y El Estado Inmunológico En Dos Fundaciones De La Ciudad De Cartagena". *Avances En Odontoestomatología* 28.4 (2012): 181-189.
42. Abe Oluwatoyin Elizabeth., *et al.* "Orofacial Lesions Associated with Long-term Highly Active Antiretroviral Therapy Among HIV-seropositive Adults in Ibadan, Nigeria". *Pan African Medical Journal* 38 (2021).
43. Peppes Cristiane Pedroso., *et al.* "Oral Lesions Frequency in HIV-positive Patients at a Tertiary Hospital, Southern Brazil". *Brazilian Journal of Oral Sciences* 12.3 (2013): 216-222.
44. Selvi UPG., *et al.* "Effect of HAART on the Oral Manifestations in Human Immunodeficiency Virus Positive Patients: A Clinical Study, Tiruchirappalli, Tamil Nadu". *International Journal of Scientific Study* 4.4 (2016).
45. Ramirez-Amador V., *et al.* "Oral Lesions as Clinical Markers of Highly Active Antiretroviral Therapy Failure: A Nested Case-Control Study in Mexico City". *Clinical Infectious Diseases* 45.7 (2007): 925-932.
46. Powderly William G., *et al.* "Recovery of the Immune System with Antiretroviral Therapy". *Journal of the American Medical Association* 280.1 (1998): 72.
47. Race Elizabeth M and Anthony J Japour. "Highly Active Antiretroviral Therapy". *The Lancet* 351 (1998): 1058-1059.