



Maxillary Molar Distalization with Invisalign in Adult Patients: A Case Report

Meriam Nasfi^{1*}, Mounira Rtibi¹, Ines medhioub¹, Hatem Hammouda¹
and Anissa Zinelabidine²

¹Resident in Orthodontics, Department of Orthodontics, Farhat Hached University Hospital, Sousse, Tunisia, Africa

²Professor, Department of Orthodontics, Farhat Hached University Hospital, Sousse, Africa

*Corresponding Author: Meriam Nasfi, Resident in Orthodontics, Department of Orthodontics, Farhat Hached University Hospital, Sousse, Tunisia, Africa.

Received: September 13, 2022;

Published: October 17, 2022

© All rights are reserved by

Meriam Nasfi, et al.

Abstract

Maxillary molar distalization is frequently required in class II non-extraction patients. Resolving class II molar relationships by distalizing maxillary molars may be indicated for patients with minor skeletal discrepancies [1].

Recently, Distalization with the Invisalign* system can be achieved with the sequential movement of the posterior teeth to facilitate treatment of Class II malocclusions [2].

This article describes treatment of a bilateral Class II malocclusion with Invisalign system and elastics.

Keywords: Cl II Malocclusion; Distalization; Invisalign; Reinforced Anchorage

Introduction

In class II cases with minimal to moderate crowding or incisor proclination in the maxilla, the distalization of molars is often indicated in order to avoid premolars extractions.

In these cases, several intra-arch devices have been used to distalize maxillary molars, such as the pendulum, Jones jig, first class appliance, distal jet as well as power chain or nickel-titanium (NiTi) coil connected with buccal alveolar TADs [3,11].

Using conventional distalization appliance, the proclination of anterior may happen due to the forward direction of force on the anterior teeth facing to the distalizing force on the posterior teeth [4].

Another common undesirable side effects of distalization, is the tipping of the maxillary molars along with a tendency to develop crossbite if the sagittal and transverse dimensions are not properly adjusted [5].

Recently, in several cases of distalization, Invisalign aligners is successfully used to correct a class II malocclusion without producing undesirable tipping of the maxillary molars and/or loss of anterior anchorage [6,11].

In this article, we present a clinical case with Class II division 1 patient treated successfully with Invisalign aligners and elastics.

Case Presentation

A 18-year-old patient was referred to the Department of Orthodontics at Farhat HACHED University hospital with a

chief complaint of an increased overjet and proclined upper incisors.

Extraoral examination revealed convex profile with recessive chin and an acute nasolabial sulcus (Figure 1)

Intraoral examinations revealed Class II molar and canine relationship on both sides.

The overjet was around 6.0 mm and the overbite was 5.0mm, the upper left premolars had distal rotation with a cross-bite. He also presented some spacing in the upper left lateral segment (Figure 2).

Cephalometric analysis and tracing showed Class II skeletal relationship with retrognathic mandible (SNA = 83°?SNB = 76 °, ANB = 7°, AoBo = +6), slight proclination of the upper incisors (I/F = 107°), proclined lower incisors (IMPA=106°) and normal facial height (FMA = 24°). (Figure 3 and Table 1)

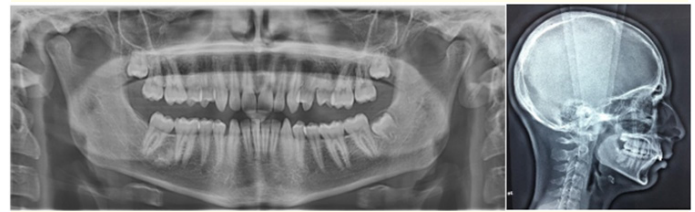

Figure 3: Pre-treatment panoramic and cephalometric radiographs.

Values	Pre-treatment	Post-treatment	Normal
SNA	83°	83°	82° ± 2
SNB	76°	77°	80° ± 2
ANB	7°	6°	2° ± 2
AoBo	6 mm	5 mm	0 ± 2 mm
FMA	24°	21°	25° ± 5
GoGn/Sn	35°	33°	32°
FMIA	50°	55°	68°
IMPA	106°	104°	87°
I/F	107°	108°	107° ± 5
I/i	120°	127°	135° ± 5
Z	57°	66°	78°

Table 1: Cephalometric measurements.

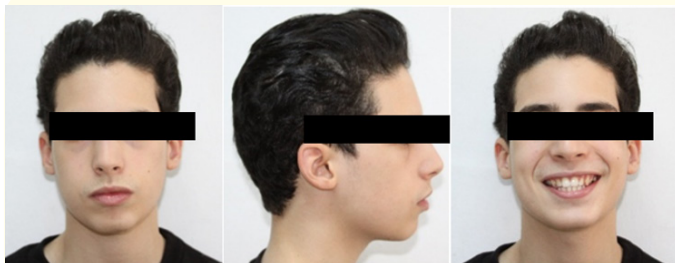


Figure 1: Pre-treatment extra-oral photos.

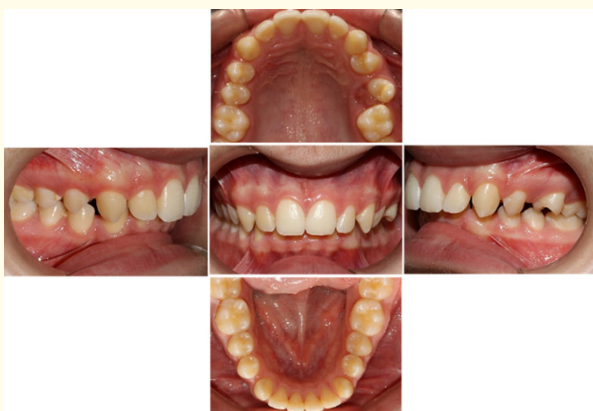

Figure 2: Pre-treatment intra-oral photos.

Different treatment options were discussed with the patient but he strongly desired an esthetic and easy to use system.

Then, we decided to use Invisalign treatment with direct-bonded attachments and elastics.

After measuring and submitting the patient’s data, the three-dimensional simulated orthodontic design was confirmed by ClinCheck (Figure 4 and Figure 5).

The patient was instructed to wear each aligner for 22h a day and change aligners every 14 days. The total number of aligner was 40.

In the first phase of treatment, we started by aligning both arches and correcting the rotations. Then we planned to distalize the upper segments into a full Class I relationship.

At aligner 23/40, the maxillary left and right segment were distalized into a full Class I relationship (Figure 6), as was the maxillary right canine at aligner 36/40 (Figure 7).

For better anchorage, the patient wore Class II elastic on both side throughout distalization. (1/8", medium, 4.8 oz). (Figure 7).

To reduce the overbite, we also planned to intrude the upper anterior teeth as seen in the ClinCheck projection. Direct bonded attachment was then bonded at aligner 23 at the upper incisors (Figure 5).

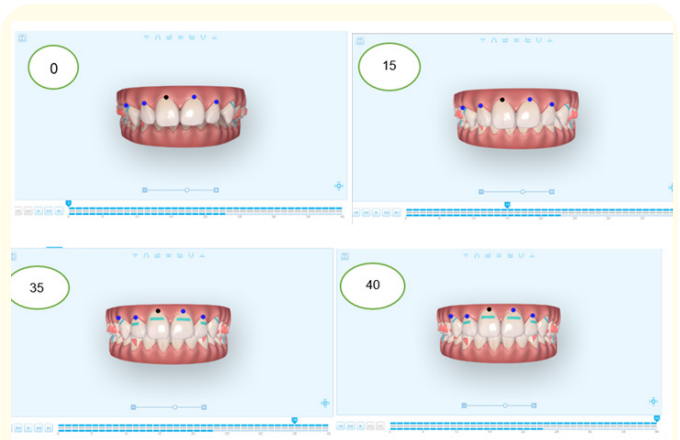


Figure 5: Screenshot of clinCheck at: aligner 0/40, aligner 15/40, aligner 35/40, aligner 40/40.

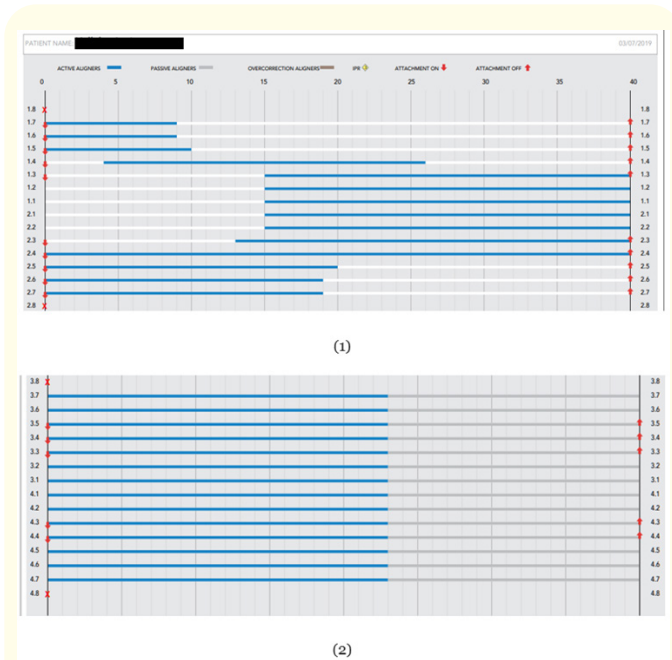


Figure 4: Online staging: (1) maxillary staging, (2) mandibular staging.

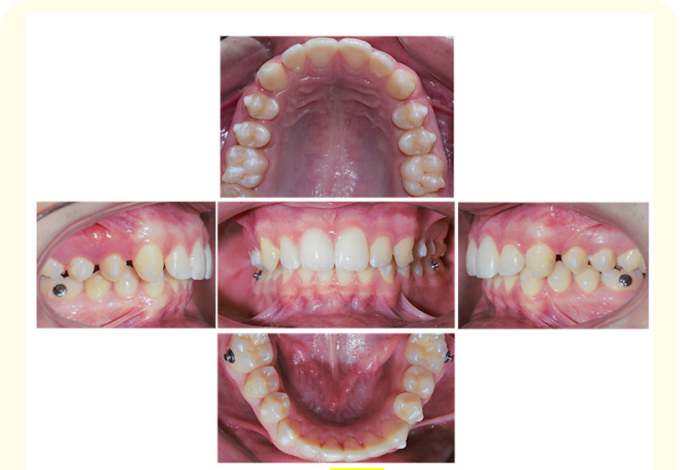

Figure 6: Intraoral photos at aligner 23/40.

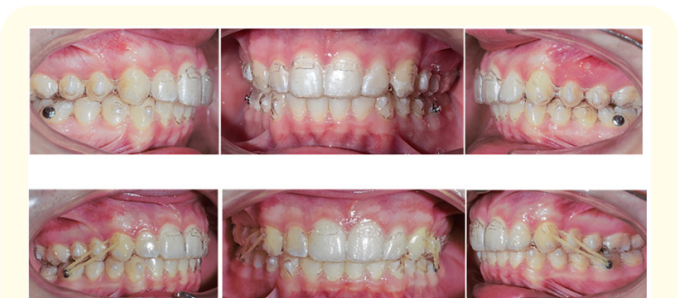

Figure 7: Intraoral photos at aligner 36/40.

- After 20 months, all treatment objectives were fulfilled.
- Fiber fixed retainers were placed in both arches to maintain long-term stability (Figure 8)
- Intraoral examination showed a cl I molar and canine relationship on both side.
- Proper overbite and overjet had been established (Figure 8)
- Extraoral photos showed a good profile and an improved smile (Figure 9)
- No root resorption was observed in the intruded upper incisor region. Root paralleling was therefore achieved, as it's shown in the post treatment panoramic
- Post-treatment cephalometric analysis revealed good vertical control (Figure 10)
- Superimpositions of pre and post-treatment cephalometric radiographs revealed that overjet correction was a combination of mandible advancement and proclination of lower incisors. (Figure 11)

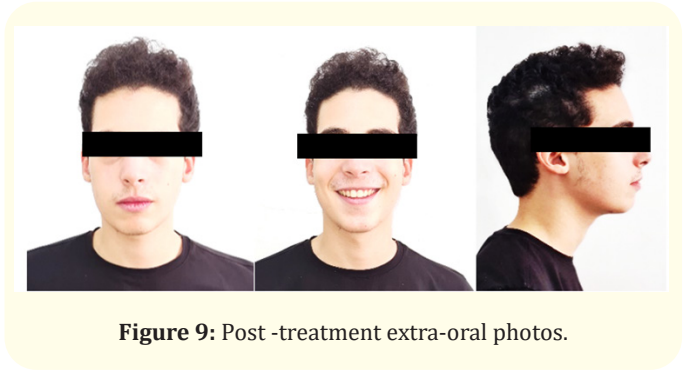

Figure 9: Post -treatment extra-oral photos.

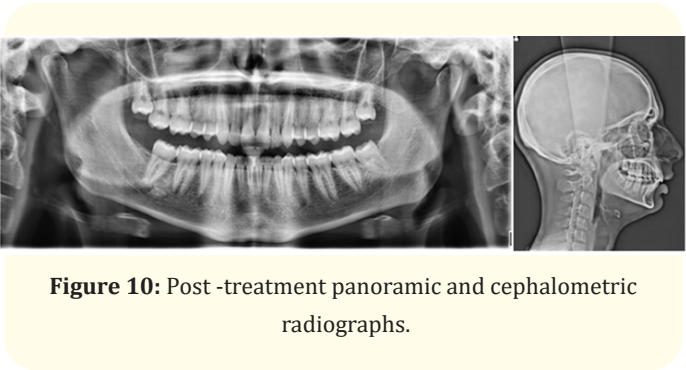


Figure 10: Post -treatment panoramic and cephalometric radiographs.

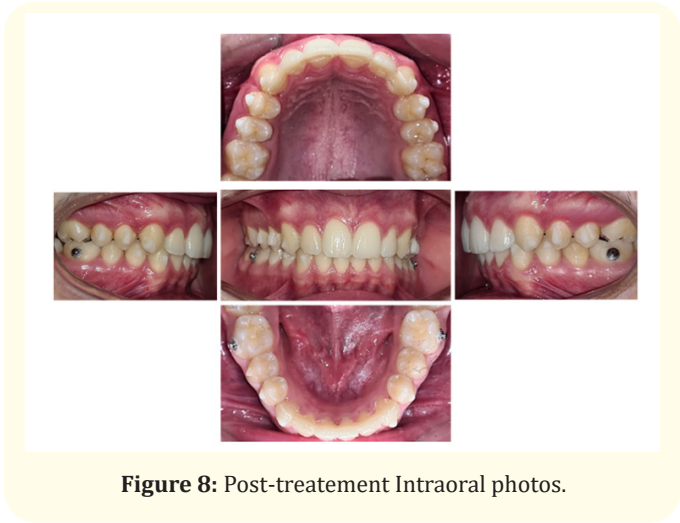


Figure 8: Post-treatment Intraoral photos.

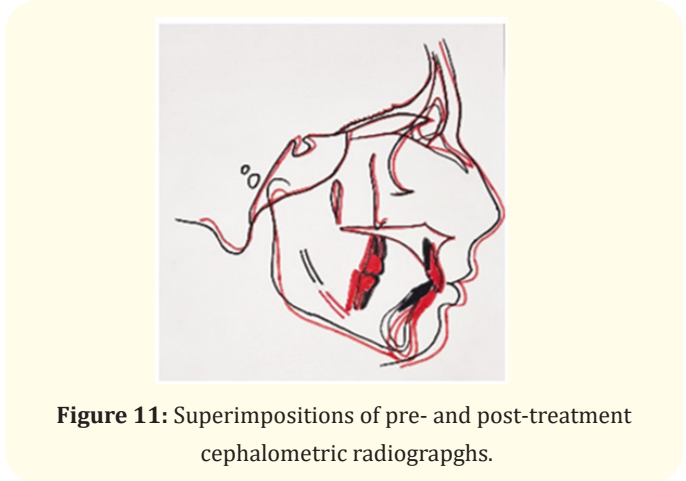


Figure 11: Superimpositions of pre- and post-treatment cephalometric radiographs.

Discussion

Distalizing maxillary molars have been frequently used for Class II malocclusion with minor skeletal discrepancies and maxillary dentoalveolar protrusion to establish a Class I molar and canine relationship and a normal overjet.

Recent advances in the Invisalign system allow predictable distalization of posterior teeth to facilitate treatment of Class II cases.

To this end, Distalization with invisalign aligners can be achieved with the sequential movement of the posterior teeth.

For example, if the second molars are present, then the second molars are distalized first, followed by the first molars, followed by the premolars, and so on [6,11].

Simon., *et al.* [15], reported that the molar distalization with aligners revealed an accuracy of 87% confirming a good performance of the appliance when a maximum distalization of 3 mm was requested [7]. In fact, the best accuracy is obtained when the movement was supported by the presence of an attachment on the tooth surface [8].

In this case, we used Invisalign aligners with bonded attachment to distalize maxillary molars and to establish cl I molar and canine.

- Clear aligners have evolved developing auxiliary elements such as composite attachments to control the quality of tooth movement. It has been suggested that composite attachments can also produce counter moment to achieve bodily movement [8].
- Invisalign system had also improved a reinforced anchorage to avoid side effects like the proclination of anterior teeth due to the distalizing force on the posteriors.
- The concept of reinforced anchorage is that when the second molars are distalized, the first molars and all the teeth anterior to it on both sides act as the anchor unit [9].
- This leads to fewer side effects on the anterior teeth.
- In addition, the wearing of elastics during orthodontic treatment help in reinforcing anchorage. It has been shown that the maxillary first molar can be distalized effectively with aligners in combination with intermaxillary elastics by 2.25 mm, without significant effects on the vertical dimension [10].
- So for better anchorage, the patient wore Class II elastic on both side throughout distalisation in this case. (1/8", medium, 4.8 oz).

Thus, while applying distal force on all the maxillary teeth, proper planning and staging of force application and direc-

tion can help in preserving anchorage and treating Class II malocclusions, with esthetic result.

Conclusion

The post treatment results were highly satisfying with good posterior occlusion and excellent facial soft tissue harmony.

Using molar distalization with elastics helped us to avoid the flapping of maxillary incisors and altering the patient's profile.

Invisalign technique is simple and comfortable. It can expand the arch, align the dentition and correct cl II malocclusion at the same time, thus shortening the treatment time successfully.

Consent and Ethical Approval

An informed consent was obtained from the participant. Approval was obtained from Farhat Hached ethical committee.

Bibliography

1. Ravera., *et al.* "Maxillary molar distalization with aligners in adult patients: a multicenter retrospective study". *Progress in Orthodontics* (2016).
2. Schupp W., *et al.* "Class II correction with the Invisalign system". *Journal of Clinical Orthodontics* 44 (2010): 28-35.
3. Chenshuang Li and Chun-Hsi Chung. "A Simple Technique Using a Modified Nance Appliance as Anchorage for Maxillary Molar Distalization-Two Case Reports". *Applied Sciences* 12 (2002): 768.
4. Angelieri F., *et al.* "Comparison of the effects produced by headgear and pendulum appliances followed by fixed orthodontic treatment". *European Journal of Orthodontics* 30.6 (2008): 572-579.
5. Haydar S and Uner O. "Comparison of Jones jig molar distalization appliance with extraoral traction". *American Journal of Orthodontics and Dentofacial Orthopedics* 117 (2000): 49-53.

6. Mehta., *et al.* "Aligners and Complex Orthodontic Tooth Movement". *Turkish Journal of Orthodontics* 34.3 (2021): 202-206.
7. Simon M., *et al.* "Treatment outcome and efficacy of an aligner technique - regarding incisor torque, premolar derotation and molar distalization". *BMC Oral Health* 14 (2014): 68.
8. Cengiz Ayidağca and Beste Kamiloğlu. "Effects of Variable Composite Attachment Shapes in Controlling Upper Molar Distalization with Aligners: A Nonlinear Finite Element Study". *Journal of Healthcare Engineering* (2021): 8.
9. Simon M., *et al.* "Forces and moments generated by removable thermoplastic aligners: incisor torque, premolar derotation, and molar distalization". *American Journal of Orthodontics and Dentofacial Orthopedics* 145.6 (2014): 728-736.
10. Ravera S., *et al.* "Maxillary molar distalization with aligners in adult patients: a multicenter retrospective study". *Progress in Orthodontics* 17 (2016): 12.
11. Dalle I., *et al.* "Dispositifs intramaxillaires de distalisation des molaires en technique multi-attache et avec aligneurs". *Orthodontie Française* 88 (2017): 355-366.