



## Day Care General Anaesthesia in Pediatric Dental Practice- A Case Report

**Archana Singh\* and Priyanka Soni**

*Department of Pedodontics and Preventive Dentistry, Teerthanker Mahaveer Dental College and Research Centre, India*

**\*Corresponding Author:** Archana Singh, Department of Pedodontics and Preventive Dentistry, Teerthanker Mahaveer Dental College and Research Centre, India.

**Received:** February 24, 2022

**Published:** May 16, 2022

© All rights are reserved by **Archana Singh and Priyanka Soni**.

### Abstract

Caries is the only commonest chronic disease of childhood. The caries is known as infancy caries, if occurred before 71 months of age. The early pulp involvement and gross destruction of the maxillary anterior teeth is seen in rampant caries, leading to reduce mastication efficiency, dysarthria, compromised aesthetics, development of abnormal oral habits, malocclusion and psychological problems. In an uncooperative child, restoration and treatment of such condition becomes a challenge for the pedodontist. The purpose of this case report is to provide a full mouth rehabilitation under anesthesia and replacement therapies that are available.

**Keywords:** General Anaesthesia; Dental Caries; irt

### Introduction

The treatment of young children is a challenging situation for the dental practitioner. Children are often anxious in the dental situation and their level of co-operation is limited. Successful treatment may be possible in hands of an experienced pediatric dentist. Behavior management techniques offer many possibilities, even in very young patients, and sedation may enhance the child co-operation for necessary treatment. The child with multiple carious lesions presents some additional problem. Thus, general anaesthesia may be the treatment modality of choice for the delivery of quality dental care. The purpose of this case report is to provide a service for total dental rehabilitation of children with multiple carious lesions under day care general anaesthesia.

### Case Report

A six year old male patient presented with parents to the department. The parents complained of decayed teeth and pus discharge in lower left back teeth region since 3 days back. Patient was completely asymptomatic 3 days back when he had pus discharge in lower left back region of jaw. He had pain and difficulty in chewing food.

According to Frankl's behavior rating scale, the score was 1 indicating the child's behavior was definitely negative. The patient ignored verbal commands, when asked to take seat in dental chair. Anyhow it was managed to take OPG, and diagnosis was made as multiple carious teeth with irreversible pulpitis in upper anteriors and abscess in lower left molar.

Basic behaviormanagement techniques were tried initially on the child but had to be given up soon as the patient was uncooperative. Considering the age of the patient, complexity of the treatment and the complications that may arise we gave the option of pharmacological means to the parents, i.e., sedation and General anaesthesia (GA). The father who had an idea about GA, told us to proceed with GA. The whole procedure was made to understand to the parents.

In subsequent appointment, the patient got admitted to hospital one day before the scheduled date of operation. Written consent was taken from the parents.

A thorough examination of the mouth revealed multiple decayed teeth altogether four quadrants. Treatment was planned ex-

traction irt 74 followed by band and loop space maintainer. Composite restoration irt 54, 64 followed by stainless steel crowns. Pit and fissure sealant irt 84,85,75,55,16,65. Pulpectomy irt 52 51 61 62 followed by strip crown. Composite Restoration irt 83, 53, 73. The patient was recalled on next day.

Next day, before starting treatment, he was referred to anesthesiologist and a pediatrician, to get clearance for his medical issues for general anesthesia. After clearance the patient was admitted and the anesthesiologist administered the General anesthesia by induced by 2% sevoflurane using a face mask, according to a standard protocol. The patient was intubated nasotracheally in order to obtain access into the patient’s mouth and a mouth prop was used to keep mouth open. A saliva ejector was used to control oral moisture, and aspiration was prevented by placing moist sterile gauze in the pharyngopalatine area.

The local anesthetic agent, articaine with epinephrine, was used and then the dental treatment was started. First, the carious tissue was removed using a high a speed bur and composite restoration was done, followed by stainless steel crown irt 54 and 64. Pit and fissure sealant irt 84,85,75,55,16,65. Pulpectomy followed by strip crown was done irt 52 51 61 62. Finally, composite Restoration irt 83, 53, 73.

After completion of the dental treatments, the patient was transferred to the recovery room, where he recovered uneventfully from the general anesthesia. All dental procedures were completed without any problems, and the dental procedure was completed in 90 minutes. After an oral examination, he was discharged from the hospital the next day.

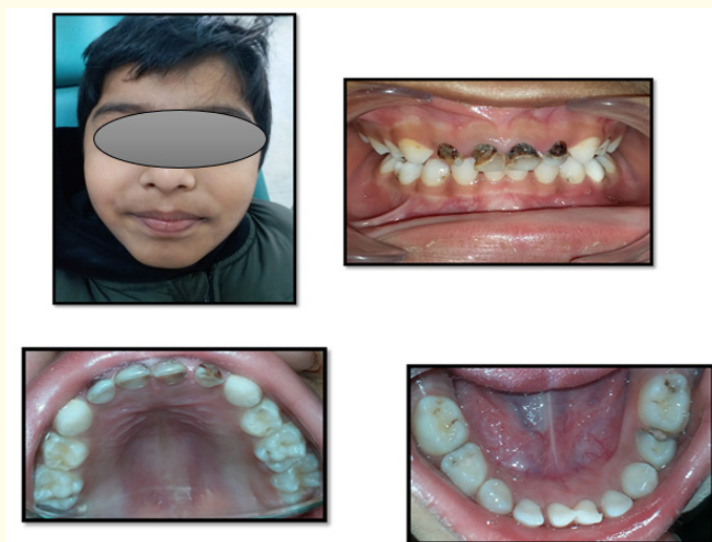

Figure 1: Preoperative view.

**Discussion**

Despite the declining prevalence of dental caries in recent decades, there are still a substantial number of children with early childhood caries. Many of these children are young and have many carious lesions, which may pose a problem with behavior management when prolonged or multiple visits for dental treatment are needed. There are multiple behavioral and therapeutic approaches to the treatment of early childhood caries.

For many young children with extensive dental involvement, however, successful treatment in the conventional care setting is extremely difficult, and comprehensive oral rehabilitation under general anaesthesia (GA) is required in order to provide quality dental care.

As per American Society of Anesthesiologists (ASA) general anesthesia (GA) is defined as “a drug-induced loss of consciousness during which patients are not arousable, even by painful stimula-

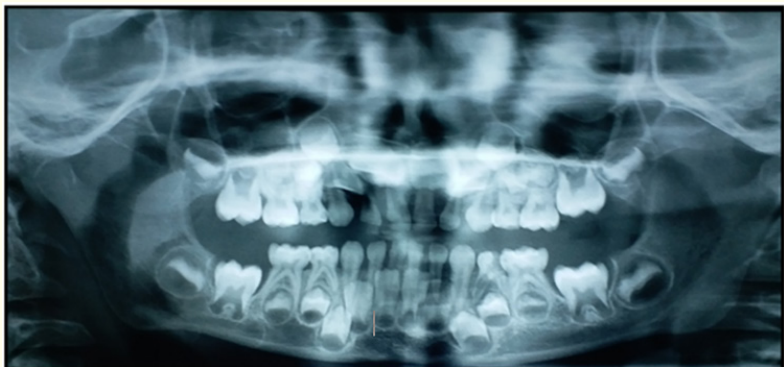

Figure 2: Pre-operative OPG

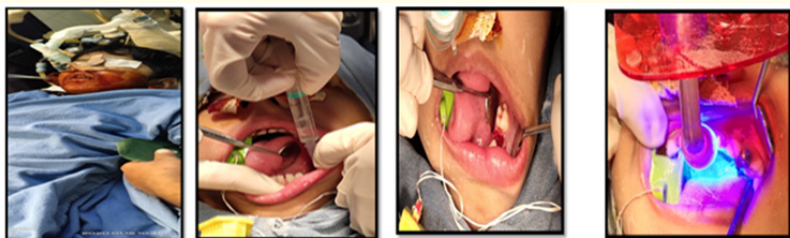


Figure 3: Extraction irt 74.

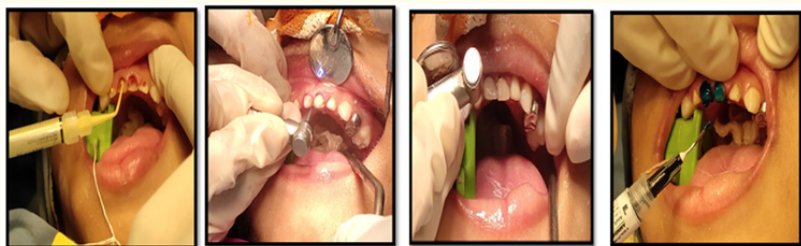

Figure 4: Strip crown irt 51, 52, 61, 62.

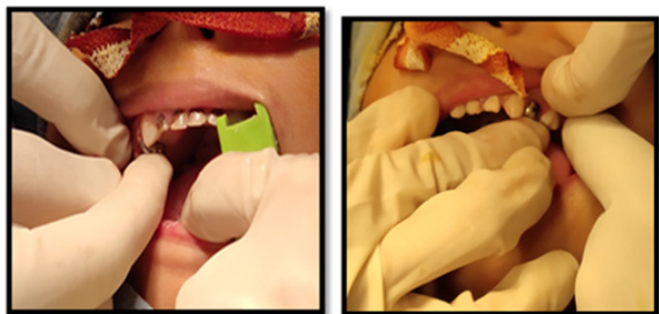

Figure 5: Stainless steel crown irt 54, 64.

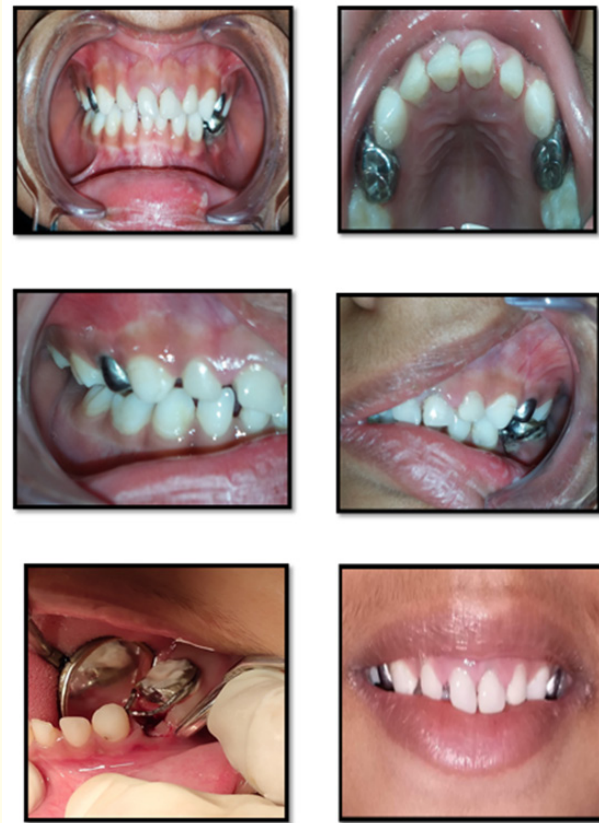

Figure 6: Post-operative view.

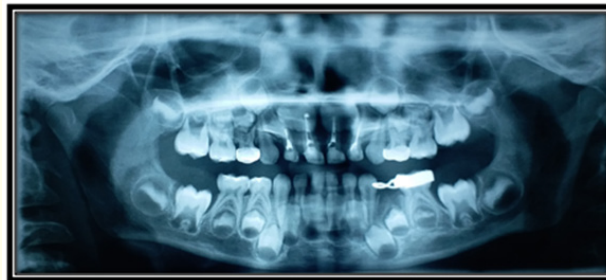

Figure 7: Post-operative view.

tion. The ability to independently maintain ventilatory function is often impaired. Patients often require assistance in maintaining a patent airway, and positive pressure ventilation could also be required due to depressed spontaneous ventilation or drug-induced depression of neuromuscular function. Cardiovascular function may be impaired.”

The American Academy of Pediatric Dentistry (AAPD) has recommended the Guidelines on the elective use of sedation and general anaesthesia for child patients.

The guidelines consisted of a list of indications of GA with the child population. The first indication is for “patients who are un-

able to cooperate due to a lack of psychological or emotional maturity and/or mental, physical or medical disability." The AAPD also states that GA is indicated for patients who are extremely fearful, anxious or not communicative, or in instances where it may protect the "developing psyche." In terms of procedures, the AAPD states that GA is appropriate for significant surgical procedures, for instances when local anesthetic is ineffective due to acute infection, anatomic variation or allergy, or for patients needing immediate comprehensive care. It is also mentioned in the Guideline that alternative behavior management techniques should be considered before the choice to utilize GA [1-6].

### Conclusion

Managing children with greater incidence of dental caries disease, behavioral problems and with special health care needs in a single appointment under GA results in an immediate result in oral health. Therefore, a pediatric dentist must have the knowledge of performing dental procedures under general anesthesia for management of uncooperative children and children with special health care needs, thus, rendering better treatment.

### Bibliography

1. Acharya S and Panigrahi A. "Rehabilitation of carious mutilated teeth under chairside general anesthesia in an attention deficit child". *Nigerian Journal of Experimental and Clinical Biosciences* 4 (2016): 59-61.
2. Vargas Román Mdel P, *et al.* "Dental Treatment under general anesthesia: A useful procedure in the third millennium? (I)". *Oral Medicine* 8 (2003): 129135.
3. Anderson HK, *et al.* "Changes in aspects of children's oral-healthrelated quality of life following dental treatment under general anaesthesia". *International Journal of Paediatric Dentistry* 14 (2004): 317325.
4. "McDonald and Avery's. Dentistry for the Child and Adolescent. 9th edition". Author: Dean, Avery, McDonald.
5. Dougherty N. "The dental patient with special needs: a review of indications for treatment under general anesthesia". *Special Care in Dentistry* 29.1 (2009): 17-20.
6. Malden PE, *et al.* "Changes in parent-assessed oral health-related quality of life among young children following dental treatment under general anaesthetic". *Community Dentistry and Oral Epidemiology* 36 (2008): 108-117.