

Mini-implants for Gummy Smile Management: A Case Report

Meriam Nasfi^{1*}, Hiba Gmati², Mounira Rtibi², Abdelatif Boughzela³ and Anissa Zinelabidine⁴

¹Resident in Orthodontics, Farhat Hached University Hospital, Sousse, Tunisia

²Resident in Orthodontics, Department of Orthodontics, Farhat Hached University Hospital, Sousse, Tunisia

³Professor and Head of Department, Department of Orthodontics, Farhat Hached Hospital, Sousse, Tunisia

⁴Professor, Department of Orthodontics, Farhat Hached University Hospital, Sousse, Tunisia

***Corresponding Author:** Meriam Nasfi, Resident in Orthodontics, Farhat Hached University Hospital, Sousse, Tunisia.

DOI: 10.31080/ASDS.2020.05.1030

Received: December 18, 2020

Published: January 28, 2021

© All rights are reserved by **Meriam Nasfi, et al.**

Abstract

In this case report, treatment of skeletal Class I malocclusion with a convex profile showing a gummy smile with incisive diastema was described.

Intrusion of the upper incisors using mini-screw implants as an orthodontic anchorage was our treatment of choice. The patient's smile was also improved using periodontal procedures.

An adequate overbite and overjet, as well as a satisfactory maxillary gingival exposure in the smile were obtained at the end of the treatment.

The aim of this paper was to highlight the importance of mini-implants for incisors intrusion and gummy smile correction in the anterior area. In order to intrude and procline the retroclined extruded incisors, both upper anterior mini-implants (1.2 x 8.0 mm) and elastic chains were utilized. Mini-implants can successfully be used as orthodontic anchorage for anterior teeth intrusion.

Keywords: Gummy Smile; TADs; Orthodontic Anchorage; Intrusion

Introduction

Excessive gingival display while smiling, referred to as "gummy smile," or "high smile line," is often considered esthetically unpleasant and unattractive [1,2].

A gummy smile can be defined as maxillary gingival exposure of 2.0 mm or more in full smiling.

A variety of combinations, including periodontal, surgical, and orthodontic therapies, are available for the treatment of gummy smile.

Simple gingivectomy or surgical crown lengthening with removal of crestal alveolar bone procedures are indicated in case patients present with excessive gingival margins and short clinical crowns [5-7].

However, periodontal procedures are not sufficient for severe gummy smile correction.

Maxillary superior repositioning by Le Fort I osteotomy is generally the treatment of choice [4-20] in cases of open bite with severe vertical maxillary excess.

Intrusion of maxillary anterior teeth may eliminate, to a certain degree, the gummy smile in cases of deep bite [21-25,26].

Orthodontic tooth movement has always been limited due to insufficient anchorage control. Complex intra-oral or extra-oral appliances are required to reinforce anchorage [9,10] in conventional orthodontic methods. However, effective intrusion of maxillary anterior teeth is not always possible as the intraoral anchorage systems and the extraoral appliances require excellent patient's compliance.

Intraosseous anchorage systems do not require patient's cooperation while receiving pure intrusion [11-25]. Among the various intraosseous anchorage, mini-implants have the advantages of providing simpler insertion and immediate loading [25,26].

This case report involves the use of two mini-screw implants for maxillary incisors intrusion and gummy smile elimination in a young female patient.

Case Presentation

A 15-year-old female patient was referred to the Department of Orthodontics at Farhat HACHED University hospital for orthodontic treatment. She presented with a gummy smile and incisive diastema.

The patient's medical history was noncontributory.

Extra-oral clinical examination showed a symmetric face with a convex profile, acute nasolabial sulcus, and a short upper lip.

While smiling, a 5 mm- maxillary gingival exposure, a "gummy smile", was noted.

A short upper lip and hyperactivity of the upper lip elevator muscles were also noted (Figure 1A-C).

Intra-oral examination revealed Class I molar and canine relationship on both sides, maxillary midline diastema, and little mandibular arch crowding. The overjet was 4mm and the overbite was excessive with complete overlapping of the mandibular incisors by the extruded maxillary incisors.

The upper central incisors had mesial rotations (Figure 2:A-E).

The patient had a short, fibrotic lingual frenum with a bifid tongue.

The maxillary labial frenum was thick and it was inferiorly positioned (papilla penetrating) (Figure 3:A-B).

Functional examination showed that the patient had lingual dysfunction and consequently atypical swallowing.

Temporomandibular joint assessment showed the absence of clicks or crepitation. Moreover, the facial and masticatory muscles were asymptomatic.

A cephalogram (Figure 4, A) and a panoramic radiograph (Figure 4, C) were taken before treatment.




Figure 1: Pre-treatment extra-oral photographs: (A) Front view (B), lateral view, (C) smile view.




Figure 2: Pre-treatment intraoral photographs.

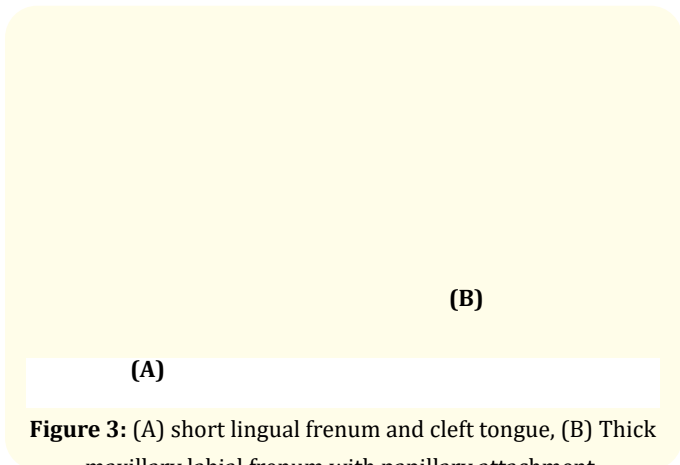


Figure 3: (A) short lingual frenum and cleft tongue, (B) Thick maxillary labial frenum with papillary attachment.

Cephalometric analysis (Table 1) and tracing (Figure 4, B) showed Class I skeletal relationship (ANB=3°, AoBo=3mm), slight proclination of the upper incisor (I/F=115°), and excessive facial height (FMA=35°).

Values	Pre-treatment	Post-treatment	Normal
SNA	81°	83	82° ± 2
SNB	78°	79	80° ± 2
ANB	3°	4	2° ± 2
AoBo	1 mm	2	0 ± 2 mm
FMA	35°	34	25° ± 5
FMIA	64°	66	68°
IMPA	81°	90	87°
I/F	115°	119	107° ± 5
I/i	133°	121	135° ± 5

Table 1: Pre-treatment and post-treatment cephalometric measurements.

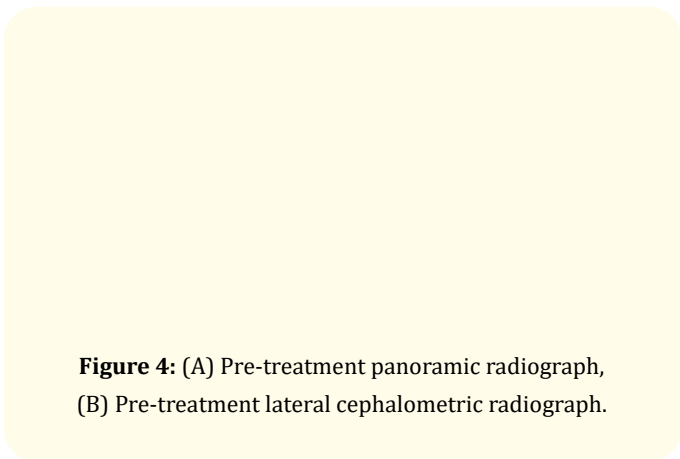


Figure 4: (A) Pre-treatment panoramic radiograph, (B) Pre-treatment lateral cephalometric radiograph.

Treatment objectives

The treatment objectives were:

- To create adequate arch length in the upper and lower arches to de-crowd and align the teeth.
- To improve the patient’s gummy smile
- To achieve optimal overjet and overbite
- To maintain class I canine and molar relationships

Treatment objectives

A non-extraction orthodontic treatment with intrusion of the maxillary anterior region using mini-implant anchorage to correct the gingival smile was our treatment of choice.

Before starting orthodontic treatment, upper labial frenectomy was performed due to the persistence of diastema between the central incisors, associated with an anomalous frenum inserted in the palate.

Mandibular lingual frenectomy and myofunctional therapy were therefore performed to correct the low position of the tongue due to a short lingual frenum. As a result, atypical swallowing was corrected.

Then, orthodontic treatment, consisting in banding and bonding the upper and lower arches, was initiated using (022”x028”) Roth prescription, and straight wire bracket systems.

In the first 6 months, initial leveling and alignment using a nickel-titanium arch wire was achieved.

Next, a 0.017”x 0.025”-stainless steel arch wire with chain elastics was placed to close the diastema (Figure 5, Figure 6).

Once bilateral class I cuspid relationship and diastema closure were achieved, surgical lip repositioning combined with anterior gingivectomy were performed to decrease the amount of gingival display (Figure 7).

Then, two mini- implants were bilaterally placed in the alveolar bone between the roots of the lateral incisors and the canine under local anesthesia. At the same appointment, intrusion of the maxillary incisors was started by applying an elastic chain, tied from the head of the mini-screw to the archwire. Nevertheless, the intrusive




Figure 5: Intraoral and extraoral photographs showing the treatment progress: after leveling, alignment and diastema closure.

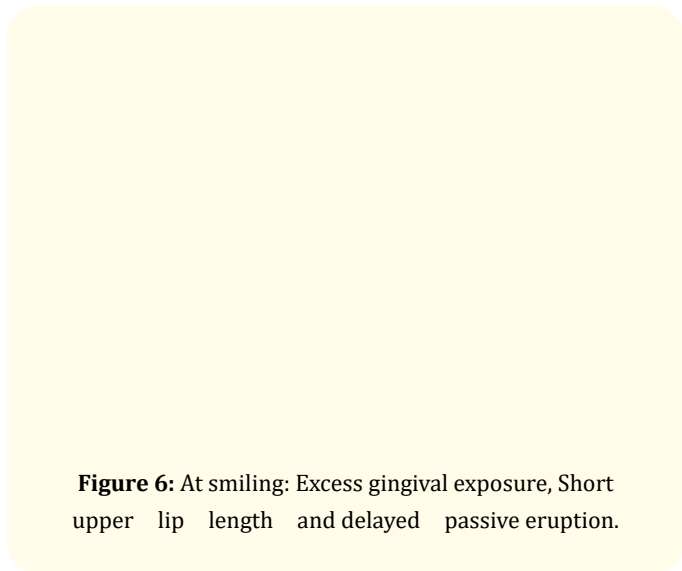


Figure 6: At smiling: Excess gingival exposure, Short upper lip length and delayed passive eruption.

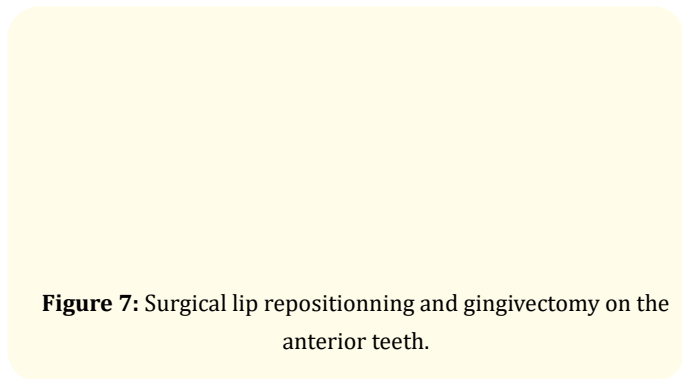


Figure 7: Surgical lip repositioning and gingivectomy on the anterior teeth.

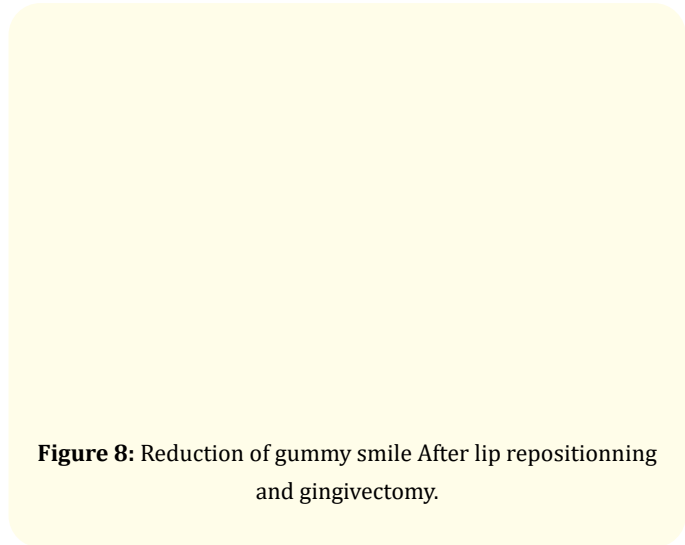


Figure 8: Reduction of gummy smile After lip repositioning and gingivectomy.

force was asymmetric because gingival exposure display was more important in the right side than in the left side (Figure 9).

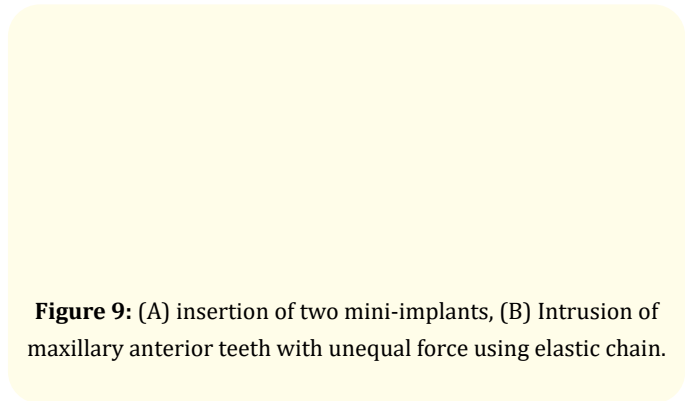


Figure 9: (A) insertion of two mini-implants, (B) Intrusion of maxillary anterior teeth with unequal force using elastic chain.

After 18 months and following an adequate intrusion to eliminate the gummy smile, the mini implants were removed. In the finishing stage, inter-maxillary elastics were applied to achieve anteroposterior correction and to obtain a better occlusal interdigitation (figure 10).

After debonding and debanding, a canine-to-canine lingual retainer was bonded in the mandibular and maxillary arches. The Total treatment time was 28 months.

Results

The upper incisors were successfully intruded. Moreover, an improvement in the gummy smile was observed in a posed smile

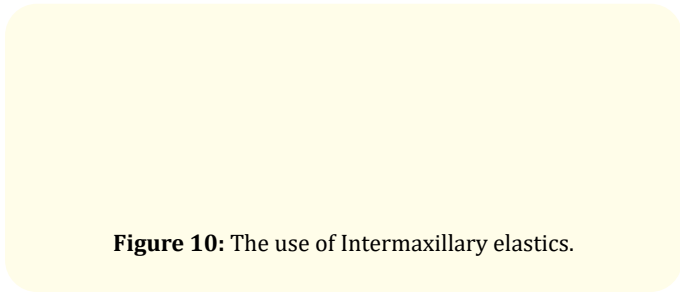


Figure 10: The use of Intermaxillary elastics.

(Figure 11). Class I molar and canine relationships with adequate amounts of overbite and overjet were obtained (Figure 12).

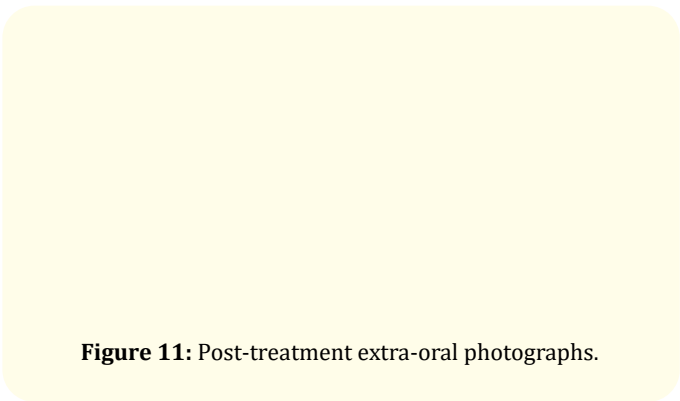


Figure 11: Post-treatment extra-oral photographs.


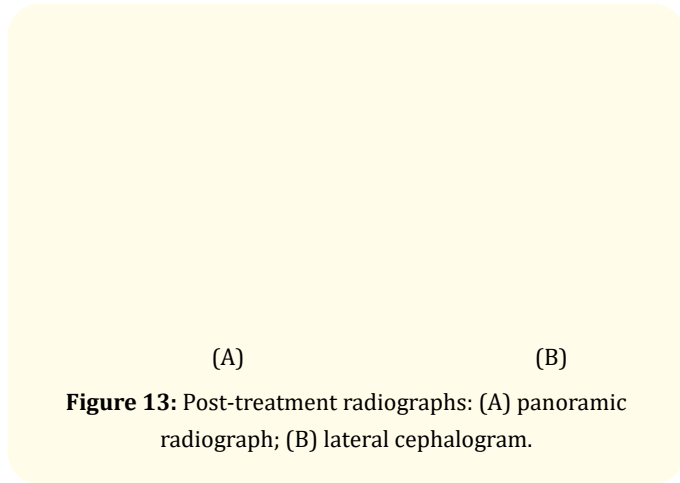


Figure 12: Post-treatment intraoral photographs.

No root resorption was observed in the intruded upper incisor region. Root paralleling was therefore achieved (Figure 13 A).

Post-treatment lateral cephalometric analysis showed no skeletal changes. However, it revealed changes in the incisor inclinations and the lip positions.



(A) (B)
Figure 13: Post-treatment radiographs: (A) panoramic radiograph; (B) lateral cephalogram.

The maxillary and the mandibular incisor inclinations were slightly increased.

A 5 mm- deep overbite and a 3 mm- overjet were corrected to 2 mm (Figure 13 -B). Due to the changes in the incisor positions, the upper and lower lips were slightly protracted.

Superimpositions of pre- and post-treatment cephalometric radiographs revealed a significant intrusion of the upper incisors (Figure 14).

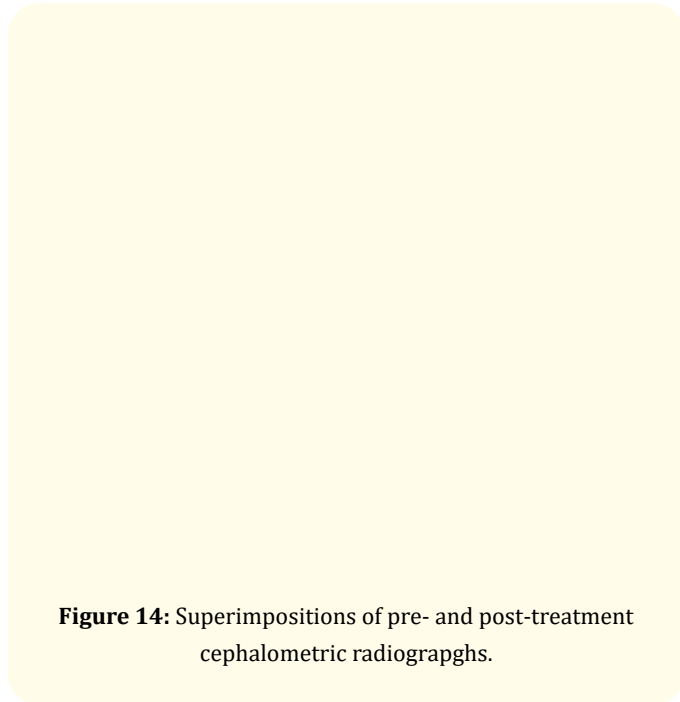


Figure 14: Superimpositions of pre- and post-treatment cephalometric radiographs.

Discussion

Gummy smiles can be divided into several categories according to their etiology. A dento-alveolar gummy smile occurs as a result of overeruption of the maxillary incisors related to the upper lip.

The dento-gingival type, caused by abnormal dental eruption, gingival hyperplasia, or lack of gingival recession is evidenced by short crown height [9].

A gummy smile having a skeletal origin occurs due to excessive maxillary vertical height. Orthognathic surgery is required for this type of smile [14,15].

A gummy smile is also frequently caused by a short upper lip [14].

The muscular type is caused by hyperactivity of the upper lip elevator muscles [16-21].

However, a gummy smile might be caused by the interaction of several factors [20-22].

In our patient, excessive eruption of the maxillary incisors seemed to be the principal factor for the gummy smile. Only the maxillary central incisors were extruded. The other posterior teeth were in normal vertical positions. The patient also presented with a short upper lip.

Thus, it was believed that the gummy smile would be improved following lip repositioning and anterior teeth gingivectomy if the extruded maxillary incisors were intruded.

Intrusion using conventional orthodontic methods, such as segmental or continuous techniques, usually accompanies extrusion of the anchored teeth. Some arch wire systems, such as the utility arch [23] or intrusion base arch [24] systems are generally used for incisor intrusion.

However, based on the law of action and reaction, these methods create a force for molars elongation.

Extrusion of the anchored molar can result in mandibular clockwise rotation, thus possibly leading to chin retrusion. The J-hook headgear depends on head anchorage. It is used for incisor intrusion. However, it requires excellent patients' cooperation [17].

Our purpose of using mini-implants as skeletal anchorage was to totally eliminate the need for patients' compliance and to minimize the side effects with regard to anchorage.

Regarding the intrusion optimum force, Burstone [18] suggested 20 g of force for intruding an anterior tooth. However, Gianelly and Goldman [22] recommended 15 to 50 g of force for small teeth.

In this case, elastic chains were used to exert 50–60 g of intrusive force on the right side and 30-40 g of force on the left side because the gingival exposure display was unequal.

The maxillary incisors were successfully intruded and the gummy smile improved with neither notable root resorption nor vitality problems during the active treatment period.

Wearing Class II elastics to correct Class II canine relationship on the left side and inter-maxillary elastics for better occlusal interdigitation was used in this case.

Conclusion

Correction of the patient's gummy smile was successfully achieved with neither orthognathic surgery nor the need for the patient's compliance thanks to the use of a combination of mini-implants and alveoloplasty. No side effects were present.

Consent and Ethical Approval

An informed consent was obtained from the participant. Approval was obtained from Farhat Hached ethical committee.

Bibliography

1. Ricketts R. "Esthetics, environment and the law of lip relation". *American Journal of Orthodontics* 54 (1968): 272-289.
2. Janzen E. "A balanced smile d a most important treatment objective". *American Journal of Orthodontics* 72 (1977): 359-372.
3. Peck S., et al. "The gingival smile line". *Angle of Orthodontics* 62 (1992): 91-100.
4. Turkich Kokich VG. "Esthetics: The orthodontic-periodontic-restorative connection". *Seminar on Orthodontics* 2 (1996): 21-30.
5. Garber DA and Salama MA. "The aesthetic smile: Diagnosis and treatment". *Periodontology* 11 (2000): 18-28.

6. Brägger U., et al. "Surgical lengthening of the clinical crown". *Journal of Clinical Periodontology* 19 (1992): 58-63.
7. Ohnishi H., et al. "A mini-implant for orthodontic anchorage in a deep overbite case". *Angle of Orthodontics* 75 (2005): 444-452.
8. Bonetti GA and Giunta D. "Molar intrusion with a removable appliance". *Journal of Clinical Orthodontics* 30 (1996): 434-437.
9. Chun YS., et al. "Maxillary molar intrusion with the molar intrusion arch". *Journal of Clinical Orthodontics* 34 (2000): 90-93.
10. Costa A., et al. "Mini screws as orthodontic anchorage: a preliminary report". *International Journal of Adult Orthodontics and Orthognathic Surgery* 13 (1998): 201-209.
11. Tae-Woo Kim., et al. "Correction of deep overbite and gummy smile by using a mini-implant with a segmented wire in a growing Class II Division 2 patient". *American Journal of Orthodontics and Dentofacial Orthopedics* 130.5 (2006): 676-685.
12. Monaco A., et al. "Gummysmile: clinical parameters useful for diagnosis and therapeutic approach". *Journal of Clinical Pediatric Dentistry* 29 (2004): 19-25.
13. Burstone CJ. "Deepoverbite correction by intrusion". *American Journal of Orthodontics* 72 (1977): 1-22.
14. Proffit WR., et al. "Contemporary treatment of dentofacial deformity". St Louis: Mosby 111 (2003): 500-506.
15. Ataoglu H., et al. "Bimaxillary orthognathic surgery in a patient with long face: a case report". *International Journal of Adult Orthodontics and Orthognathic Surgery* 14 (1999): 304-309.
16. Miskinyar SA. "A new method for correcting a gummysmile". *Plastic and Reconstructive Surgery* 72 (1983): 397-400.
17. Melsen B., et al. "Intrusion of incisors in adult patients with marginal bone loss". *American Journal of Orthodontics and Dentofacial Orthopedics* 96 (1989): 232-241.
18. Burstone CR. "Deep overbite correction by intrusion". *American Journal of Orthodontics* 72 (1977): 1-22
19. Gianelly AA and Goldman HM. "Biologic basis of orthodontics". Philadelphia: Lea and Febiger (1971).
20. E IZRAELEWICZ-DJEBALI and C CHABRE. "Gummysmile: orthodontic or surgical treatment?" *Journal of Dentofacial Anomalies and Orthodontics* 18 (2015): 102.
21. Mueller Storrer., et al. "Treatment of Gingival Smile". *Journal of the International Academy of Periodontology* 19/2 (2017): 51-56
22. James Cheng-Yi Lin., et al. "Treatment of skeletal origin gummy smiles with miniscrew implant-supported biomechanics". (2015): 196-203.
23. Ricketts RM., et al. "Bioprogressive Therapy". Denver, Co: Rocky Mountain Orthodontics (1979): 111-126.
24. Burstone CR. "Deep overbite correction by intrusion". *American Journal of Orthodontics* 72 (1977): 1-22.
25. Ines AYADI., et al. "Ingression orthodontique sur mini-vis d'ancrage". *Orthodontie Française* 89 (2018): 397-410.
26. CA Estevanell Tavares., et al. "Mini-implants for the management of a gummysmile". *Journal of the World Federation of Orthodontists* 2 (2013): e99-e106.

Assets from publication with us

- Prompt Acknowledgement after receiving the article
- Thorough Double blinded peer review
- Rapid Publication
- Issue of Publication Certificate
- High visibility of your Published work

Website: www.actascientific.com/

Submit Article: www.actascientific.com/submission.php

Email us: editor@actascientific.com

Contact us: +91 9182824667