



Apical Surgery: New Concepts

Younes Kalakhy*

Oral Surgery Department, Targa Dental Clinic, Marrakech City, Kingdom of Morocco

***Corresponding Author:** Younes Kalakhy, Oral Surgery Department, Targa Dental Clinic, Marrakech City, Kingdom of Morocco.

Received: September 25, 2020

Published: October 29, 2020

© All rights are reserved by **Younes Kalakhy**.

Abstract

Apical surgery is a technique developed for the surgical treatment of apical lesions of pulpal origin, some authors speak of surgical endodontics or endodontic surgery.

The surgical protocol consists of the surgical approach of the periapical region, tissue debridement and removal of granulation or cystic tissue and then proceed to the resection of the root apex and finish by filling the apex with a material ensuring apical hermeticity, we speak of retrograde filling.

This technique has seen a lot of improvement especially with a new generation of materials such as MTA (Mineral trioxide aggregate) and bioceramics as well as the advent of piezosurgery and the operating microscope. In this paper, we will focus on the definition, indications, contraindications as well as the principle and the surgical protocol.

Keywords: Apical Surgery; Periapical Pathology; Retrograde Filling; Flap Design; Resection Angle; MTA

Introduction

Apical surgery is a technique developed for the surgical treatment of apical lesions of pulpal origin, some authors speak of surgical endodontics or endodontic surgery.

The surgical protocol consists of the surgical approach of the periapical region, tissue debridement and removal of granulation or cystic tissue and then proceed to the resection of the root apex and finish by filling the apex with a material ensuring apical hermeticity, we speak of retrograde filling [26].

This protocol is currently well codified with a success rate that has been significantly improved by the evolution of root end filling materials such as Mineral trioxide aggregate (MTA) and the use of piezo surgery. The success rate has increased from at least 60% to currently 90% [3,40]. However, apical surgery is not considered as an alternative to conventional root canal treatment, which should always be considered as the first-line treatment.

Periapical pathology [1-20]

Periapical pathologies are of endodontic origin in a large majority of cases, where pulpal necrosis will provoke a passage of the bacterial flora to the periapical space which will trigger a cascade of immunopathological reactions favored by a rich periapical vascularization as opposed to the pulpal space.

The apical lesions go through different phases from a slightly symptomatic primary inflammation to a more important clinical manifestation with a consequent bone resorption. Studies have shown that the periapical immune response involves different non-specific and specific immunological mechanisms to contain and neutralize pathogens orchestrated by numerous chemical mediators such as: neuropeptides, fibrinolytic agents, kinins, complement, kallikrein, mast cells and specific mediators such as immunoglobulins, B and T lymphocytes, macrophages.

According to stages, Physiopathological, clinical and histological characteristics, Morse in 1977 [1] propose a classification of periapical pathologies:

Stage	Etiology	Clinical signs and radiological	Histology	Treatment
<p>Periodontitis apical symptomatic: PAS first extension of the inflammation in the Periapical space</p>	<p>. Bacteria: pulp necrosis . Mechanical irritation: instruments</p> <p>• endodontics Filling paste overflow Occlusal trauma</p>	<p>. Discomfort Induced pain By percussion or dental contact . No Radiological sign</p>	<p>Leukocytes The PMNs</p>	<p>Elimination of the agent etiological pulp cavity filling</p>
<p>Periodontitis apical asymptomatic: PAA</p>	<p>Pulp necrosis Sequel to PAS.</p>	<p>.negative thermal test . Percussion is not painful or slightly . Palpation can be slightly sensitive . X-ray signs positive: break in the lamina dura in bone resorption</p>	<p>Stage Granuloma: Mastocytes, of macrophages, of lymphocytes, cells plasma cells and sometimes PMN leukocytes. The cells multinucleated giant, of foam cells, of crystals of cholesterol and the epithelium are often observed. Cyst stage: A granuloma that contains a cavity or cavities encapsulated in a epithelium.</p>	<p>. Elimination of the Etiological agent - pulp cavity filling Extraction, surgery</p>
<p>Osteitis condensing</p>	<p>Variants of apical periodontitis asymptomatic, results in a increase in bone density trabecular in response to irritation persistent</p>	<p>. Asymptomatic or pains Radiographics presence of a diffuse arrangement and radio- concentric opacity around the apex is pathognomonic of the lesion</p>	<p>Increase of the bone trabecular bone irregularly arranged and the inflammation</p>	<p>Elimination of the Etiological agent pulp cavity filling</p>
<p>Acute apical abscess AAA</p>	<p>Localized liquefaction lesion or diffuse of pulpal origin which destroys periradicular tissue, accompanied by severe inflammation in response to microbial irritants or not Microbials from the necrotic pulp.</p>	<p>. Rapid attack and a spontaneous pain . Pain on palpation and percussion. . Eventually manifestation of a systemic infectious process general .negative thermal test</p>	<p>. Lesion necrotic of liquefaction . Leucocytes PMN disintegrators, of debris, of residues cellular and a accumulation exudate purulent</p>	<p>. Elimination of the Etiological agent . Drainage - pulp cavity filling</p>
<p>Apical abscess chronic</p>	<p>Inflammatory lesion of pulpal origin characterized by the presence of a lesion ancient transformed into an abscess that has drained into the mucous membrane or on the surface of the skin by a fistula</p>	<p>Asymptomatic Unless the fistula route is clogged from time to time causing a pain</p>	<p>Similar to those of the periodontitis acute apical</p>	<p>. Elimination of Etiological agent . Drainage - pulp cavity filling</p>

Figure 1: Table of Morse code classification of periapical pathologies 1977.

Indications and contraindications of apical surgery [3,16,26]

The indications

Anatomical factors

- Unfavorable endodontic anatomy
- Area inaccessible to endodontic instruments
- External root resorptions
- Uncompleted apical development.

Iatrogenic factors

- Non-absorbable apical filling materials

- Instrumental fracture
- Failure of endodontic treatment or retreatment
- Root canal perforation.

Other factors

- Time savings
- Crowned tooth with satisfactory aesthetic and functional results.

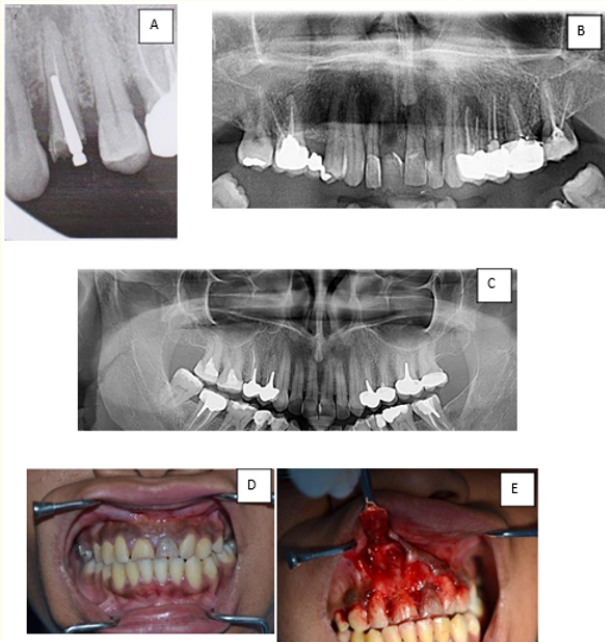


Figure 2: Clinical case of apical lesion on A: 24 with a false stump. B: 24 crowned. C: 14 crowned with lack of root canal treatment. D and E: cases of 21 necrosis evolving towards an apical lesion.

Strategic factors

The case of indication for extraction and implantation, apical surgery is performed for bone regeneration before the dental implant.

Counter-indications

Absolute counter-indications:

- Reduced periodontal support with mobility.
- Field: presence of certain diseases: valvular heart disease, patient under radiotherapy.

Relative counter-indications

Anatomical factors: the posterior upper and lower premolar molar sectors due to the presence of the maxillary sinus and alveolar canal and the chin foramen.

Decision criteria

According to the framework of indications and contraindications, the clinical approach is based on:

- The medical history for an evaluation of the general state of health and to rule out possible disease.

- The clinical examination will be directed towards the history of the disease, the evaluation of the pain, the presence of facial swelling, a filling of the vestibule, presence of fixed restoration, evaluation of the periodontium.
- The radiographic examination: the long cone x ray examination is the first intention examination which will give us information on the periapical space, off-center incidences will be taken to explore the endodontic anatomy, panoramic views will be prescribed to have a global vision of the arches and also if an apical image is greater than 5 mm.
- Useful for net exploration of the periapex, a cone beam in these cases will be indicated for a complete lesion assessment [6].

Lieblich in 2002 [28] established a decision tree of apical lesion cases based on clinical and radiological data.

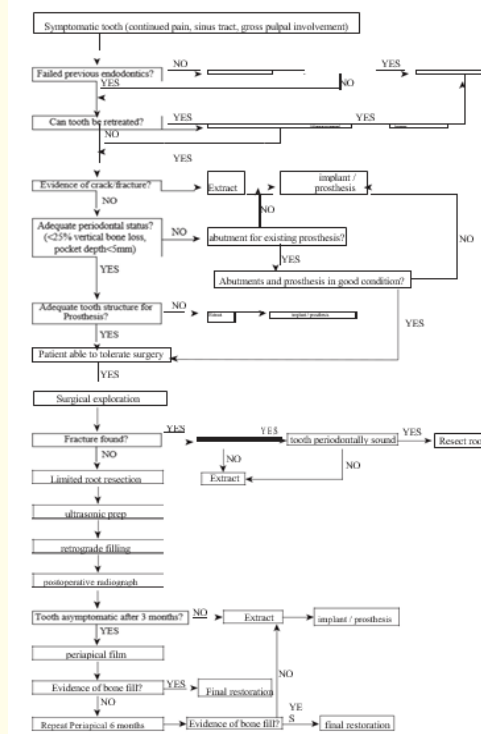


Figure 3: Showing the decision algorithm according to Lieblich in 2002 [28].

The principles of apical surgery [27,28]

Apical surgery is based on the following principles:

- The preservation of the tooth and the periodontium

- Trimming the apical region
- Resection of the apex
- Apical hermeticity.

The surgical protocol

General principles:

- Access to the periapical zone
- The respect of the periodontal tissues by an adequate incision tracing in order to avoid postoperative recessions.
- Root apex resection
- Curettage and apical cleaning
- Retrograde filling with material to ensure apical hermeticity

The flap design [3,13,14]

The selection criteria

The apical surgery has the particularity of using at the same time the principles of endodontics (Sanitation, root canal trimming and hermetic filling) and the principles of surgery: incision, flap, sutures ... the surgical approach is different in each case and meets several criteria, in addition, authors such as Grandé [13] and Von Arx [3] have worked mainly on this subject and have determined several clinical and radiological criteria for the choice of the flap design:

- The gingival biotype
- The presence of marginal restoration
- The location and degree of extension of the lesion
- The number of teeth involved in apical surgery
- The presence and depth of periodontal pockets
- The height of the attached gingiva
- Frenal and ligamentous insertions
- The vestibule depth
- The proximity of anatomical structures such as: nerves, sinuses....
- The amount of bone surrounding the surgical site
- The aesthetic value of the operated site
- The vascularization of the flap
- The absence of postoperative recession
- The absence of papillary retraction
- Easy replacement.

Flap design classification

Grande has published a literature review of the different flaps used in apical surgery: see figure 4 [13].










Flap design	Technique
intrasulcular	
➤ Intrasulcular scalloped	
➤ triangular	
➤ rectangular or trapezoidal	
semilunar	
submarginalscalloped (Ochsenbein-Luebke)	
vertical	
papilla base	
Lubow	
Vreeland	

Figure 4

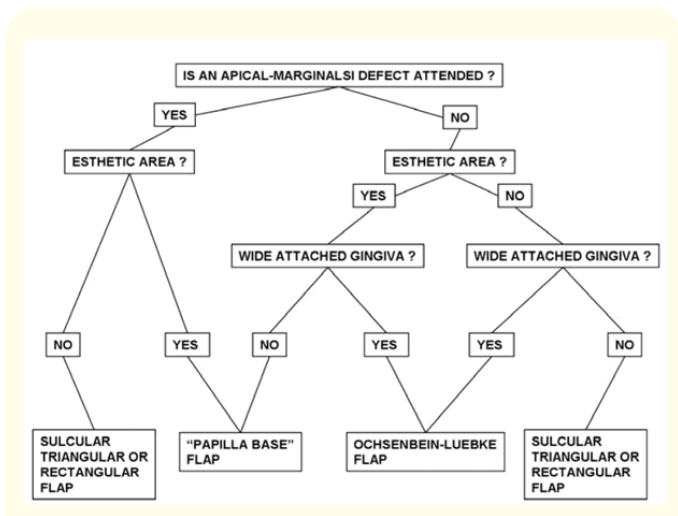


Figure 5: Decision logarithm of flap design selection in apical surgery according to Grande [13].

According to the criteria mentioned above, it can be said that for apical surgery we prefer the intrasulcular flaps, the submarginal scalloped flap and the papilla base flap, which cover the major indications and with a good benefit-risk ratio.

Osteotomy

This surgical step consists of creating a bone flap to access the root apex, except in certain cases where the lesion to blow the cortical in this case the enucleation and curettage of the cavity is undertaken first.

The osteotomy should meet certain criteria for the success of the case and therefore its long-term stability:

- The osteotomy should be as minimally invasive as possible to allow rapid healing.
- It must allow sufficient visual access to the root apex.
- Maintain a bone bridge at the bottom to prevent post-operative bone collapse.

The use of adapted instrumentation: Either using a steel ball burr mounted on a handpiece under abundant saline irrigation or better still using a piezotome.

The advantages of piezosurgery (Figure 6):

- Less surgical trauma, moreover recovery of the bone and its replacement to optimize bone regeneration.

- Do not damage the soft tissues especially in certain anatomical areas such as the premolar region in the presence of the mental foramen.
- It provides a clear operating field.
- It cuts without generating an increase in temperature.
- It can be used in different stages of apical surgery.

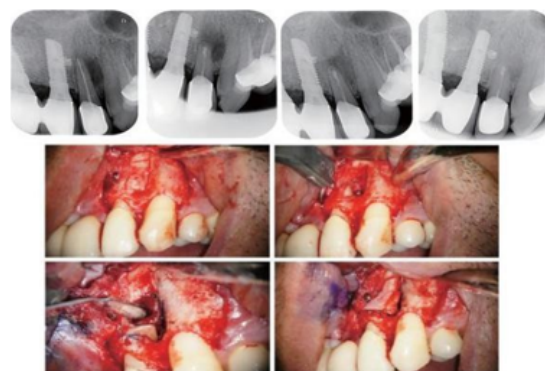


Figure 6: Apicoectomy of maxillary anterior teeth through a piezoelectric bony-window osteotomy: two case reports introducing a new technique to preserve cortical bone [24] Viola Hirsch Meetu R. Kohli, Syngcuk Kim.

Another important element during this phase of the osteotomy is the location of the osteotomy site, which must correspond to the root apex. The preoperative long cone x ray measurement or at best on a cone beam will give us information on the trepanning point, it is recommended to use a rotating micro-instrument (Figure 7) with decreasing diameter until the apex is reached. However, the advent of technology has made it possible to design a digital surgical guide (Figure 8) or even navigation systems (Figure 9) to precisely reach the surgical target and also the use of the operating microscope (Figure 10).

Will undoubtedly improve visibility and intraoperative surgical exploration.

The apical resection

Its objective is: To eliminate the canal delta at 3 mm because studies on the anatomy of the root apex (Morfis 1994 and Estrela Carlos 2016 [30] have shown that the canal branches are in the last 3 millimeters. And the position of the foramen according to the Carlos Estrela study is central in 48.95% for the maxilla and 42% for the mandible (Figure 11) [16].

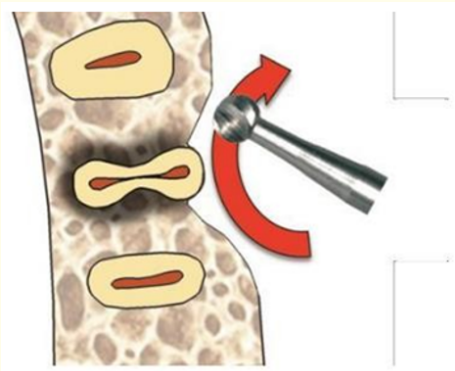


Figure 7: Drawing showing access with a steel ball cutter according to the Brush technique described by T Von Arx.

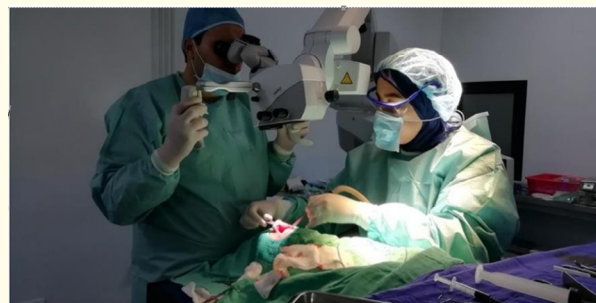

Figure 10: Photos showing the performance of cystic surgery with apical resection under an operating microscope.

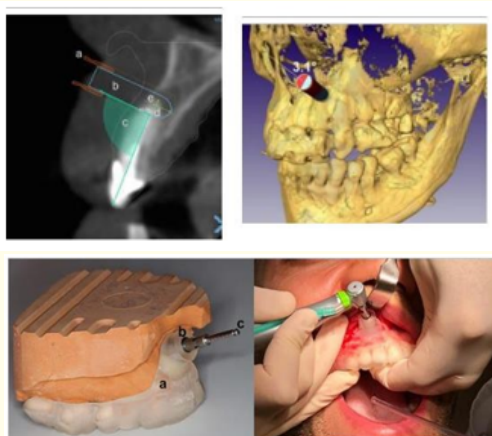


Figure 8: Photos showing the location of the apex using a surgical guide [8].

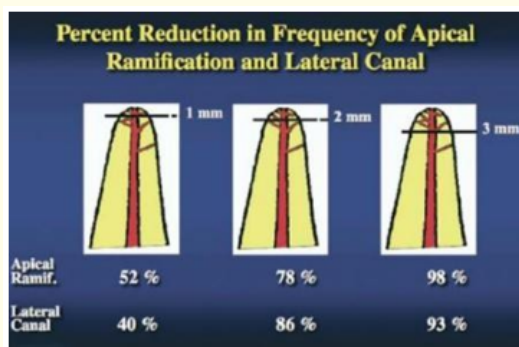


Figure 11: Reduction (in %) of the frequency of apical ramifications and lateral canals according to the resected apical portion (according to Kim and Kratchman, 2006) [16].

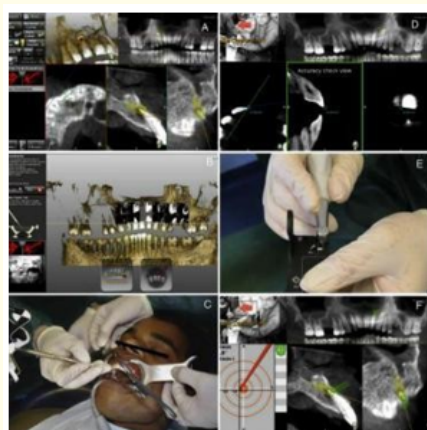


Figure 9: Photo showing the location made by a navigation system [29].

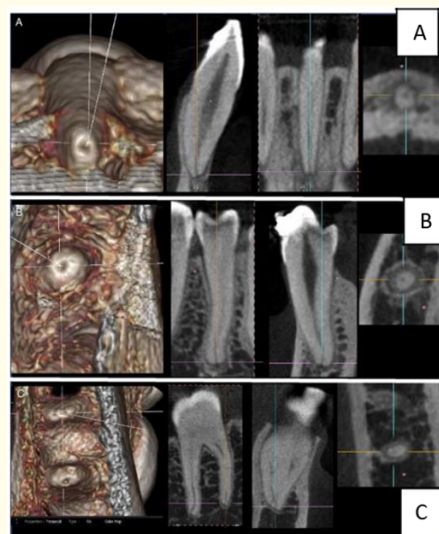


Figure 12: [9] 3D Reconstruction of a cone-beam examination of the apical region showing the situation of the apical foramina: A: Upper central incisor. B: First superior premolar. C: 1st superior molar.

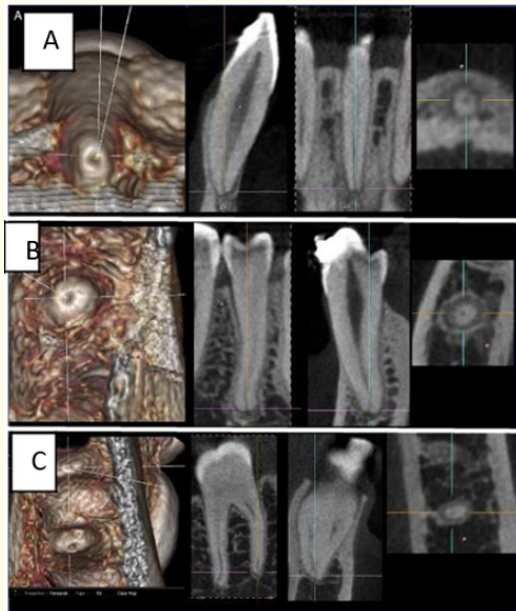


Figure 13: [9] 3D reconstruction of a cone-beam examination of the apical region showing the situation of the apical foramina: A: Lower central incisor. B: Lower first premolars. C: 1st lower molar.

To create a cutting surface allowing retrograde preparation of the root apex.

The instrumentation

The resection is performed either with a rotary instrument (steel fissure burr or surgical zekrya), ultrasonic, piezoelectric or an Erbium or CO₂ laser.

Several studies [2,5,31] have tried to compare these different instruments:

- The burs: Used at reduced speed produces a regular and smoother surface with less debris and the resection time is relatively short.
- Piezoelectric and ultrasonic inserts: The surface has grooves.
- The laser: Reduces the patient’s discomfort (vibrations), reduces the risk of contamination and damage to adjacent tissues, the surface is smoother.

However, the laser eliminates more dentine and can alter the morphology of the dentine which interferes with cell attachment and therefore decreases cell repair. Furthermore, the lack of tactile effect of the laser could possibly be responsible for iatrogenic trauma.

In conclusion, there is no scientific evidence for the superiority of one instrument over the other, the use of fissure and zekrya burs at low speed remains a reliable benchmark for apical resection.

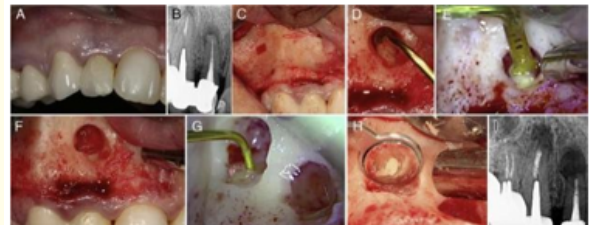


Figure 14: Uses of piezoelectric inserts in apical surgery [2].

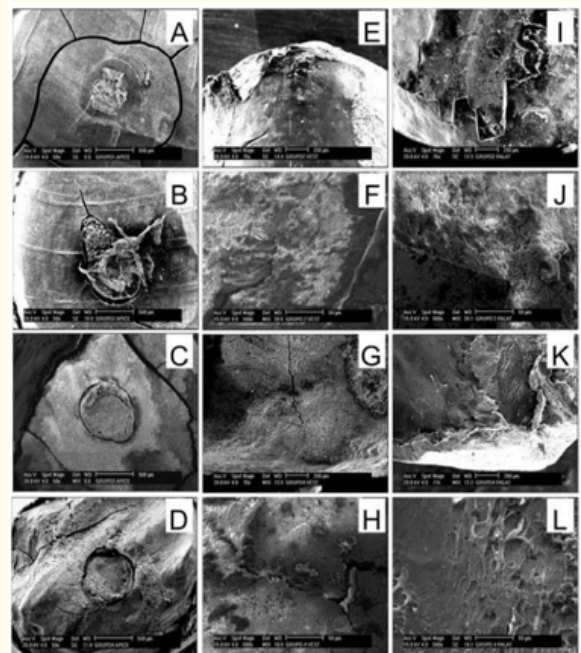


Figure 15: Photos showing the study of the apical cutting surface with a zekrya burr and Erbium Yag, Nd YAG lasers [33].

Scanning electron micrographs. A Zekrya bur, apical surface, 50; B, Zekrya bur - direct Nd:YAG, apical surface, 50; C, Er:YAG laser, apical surface, 50; D, Er:YAG laser - direct Nd:YAG, apical surface, 50; E, Zekrya bur - direct Nd:YAG, oral surface, ‘75; F, Zekrya bur - direct Nd:YAG, oral surface, 500 euros; G, Er:YAG laser - direct Nd:YAG, oral surface, 75; H, Er:YAG laser - direct Nd:YAG, oral surface, 500; I, Zekrya bur - indirect Nd:YAG, palatal surface, ‘75; J, Zekrya bur - indirect Nd:YAG, palatal surface, 500; K, Er:YAG laser - indirect Nd:YAG, palatal surface, ‘77; L, Er:YAG laser - indirect Nd:YAG, palatal surface.

Resection angle

Current endodontic surgery is a minimally invasive surgery using piezosurgery, micro instrumentation and visual aids such as the operating microscope. This was also valid for the angle of resection of the apex which was previously about 45° to allow good access for retrograde filling. Currently the authors recommend a section of the apex at 0°.

Thomas Vo Arx published in 2015 [34] (Figure 15) and (Figure 16) a prospective study to evaluate the influence of the cutting angle on the outcome of apical surgery, the nature of the tooth concerned by the surgery, the depth of the surgical site and the level of retrograde filling. He concluded That:

- The majority (62.9%) of treated roots had a shallow resection angle $\leq 20^\circ$.
- Cases with a shallow resection angle had a higher cure rate than cases with an acute resection angle, but the difference was not statistically significant.
- No linear dependence of the resection angle and surgical depth has been observed.
- Particularly in the mandibular molars, the length of the obturated root was considered short in 29.2%, especially in the area of the isthmus of the mesial roots.

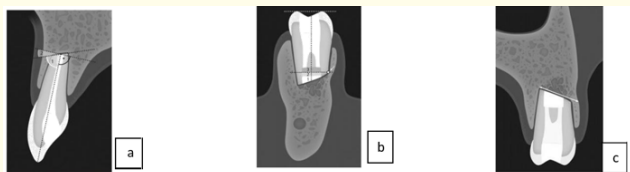


Figure 16: Illustration showing the measurements made by Thomas Von Arx in 2015 for the evaluation of the apical section angle [34]. a: Measurement of angles in relation to the major axis of the tooth. b: The levels of retrograde obturation in relation to a reference line: 1 insufficient depth 2 the depth limit is at the same level as the reference line 3 the depth is adequate. c: Measurement of the vestibular palatal depth of the surgical site.

After the apex resection, the operator must ensure good haemostasis to improve visibility and prepare the apex for retrograde obturation, local haemostasis means will be used such as: compression with biogas, hydrogen peroxide or also bone wax. In addition, another means is recommended for good visibility of the

apical anatomy and to detect possible root cracks and to locate the boundary between the apical foramen and the dentinal wall is methylene blue applied with a brush.

Retrograde filling

Retrograde preparation

Conventional preparation with rotary instruments poses several problems for the operator:

- Difficult access
- Preparation along a parallel axis is very difficult to achieve, which increases the risk of root perforation

However, the use of ultrasonic instruments has several advantages:

- The adapted shape of the inserts allows easy and precise access
- Better preservation of the dentin substance with the preservation of root morphology

Retrograde filling

Several materials have been described in the scientific literature [15-39] to achieve Retrograde filling and should meet a number of criteria:

- Biocompatibility
- Bioactivity: Stimulates cementogenesis
- No mutation
- Dimensional stability over time
- Not soluble
- Easy and ergonomic preparation

While amalgam and Egenol restorative material (IRM) have given satisfactory results, Mineral trioxide aggregate (MTA) remains the material of choice: Developed at Loma Linda University in California, USA Several randomised clinical trials and prospective studies with a follow-up of 1 to 10 years (von Arx 2019 [43]) have shown a high success rate in the use of MTA as a Retrograde filling material but no significant difference with other materials.

At present, another material has been described as bioceramics: First published by Damascus in 2011, Composed of zirconium oxide, calcium silicates, tantalum oxide, calcium phosphate as well as fillers and thickening agents.

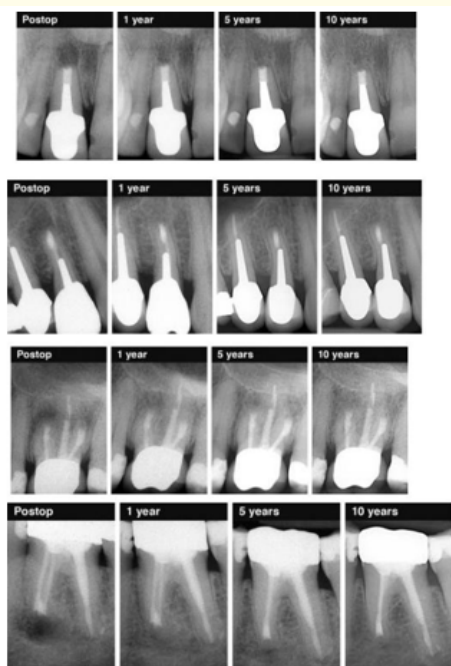


Figure 17: 1-year, 5-year, 10-year x ray control of the treatment with the von Arx 2019 MTA [43].

It is produced by Brasseler, Savannah, Georgia, USA.

Studies have shown positive results such as biocompatibility, impermeability and dimensional stability (von Arx 2020 [12]) however additional studies with a 5-year and 10-year follow-up are needed.

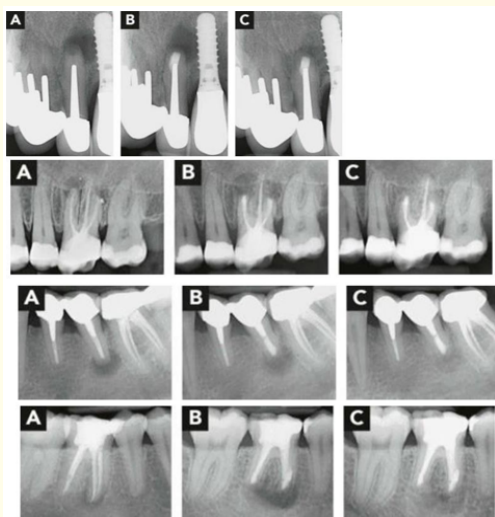


Figure 18: X-ray control after 1 year of retrograde bioceramic filling cases according to Von Arx 2020 [12]. A: Radiography before. B: Postoperative check-up J0. C: x-ray control after 1 year.

Bone regeneration in apical surgery (Figure 19) [35-37]

Some authors (Thomas VON ARX2018, Vivek Chaturvedy 2012 and others) have proposed the use of bone regeneration techniques in clinical cases, in particular bone filling with a bone substitute, the use of platelet concentrates or amelar matrix in order to optimise and guide bone regeneration of the apico-marginal bone deficit caused by apical surgery, in particular in the presence of a granuloma or a large cyst, where a postoperative bone defect is inevitable. However, further studies with a high level of evidence should be undertaken to draw conclusions on the process.

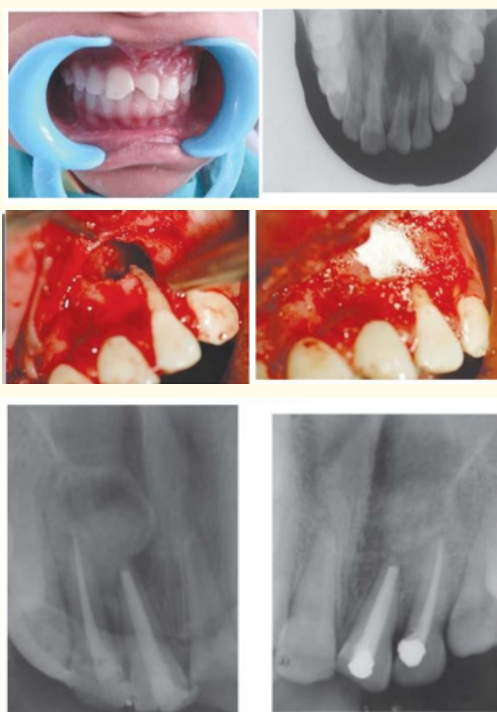


Figure 19: Photos showing bone regeneration by bone substitute after apical surgery and x-ray control at 6 months: Vivek Chaturvedy, Shefali Chaturvedy 2018 [37].

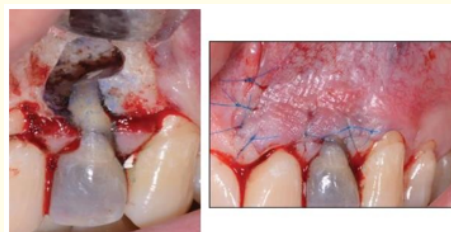

Figure 20: Photos showing the use of an amelar matrix for the treatment of an apico marginal defect apical surgery: Thomas Von Arx 2018 [38].

Clinical cases

The upper premolar region

Apical surgery on the first upper left premolar.

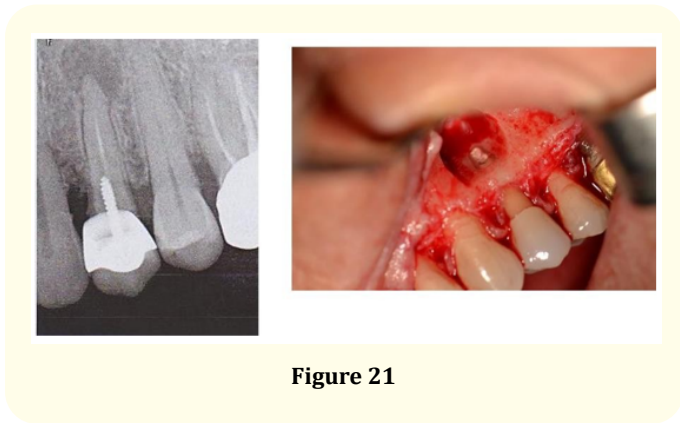


Figure 21

Presence of a fixed restoration that is stable over time and respects aesthetic and functional criteria.

Presence of a radio clear image in periapical with episodes of infection.

The apical surgery was undertaken by an intrasulcular flap from 22 to 26.

Curettage of the lesion and preparation and retrograde obturation with MTA.

Case of apical surgery on the first upper right premolar.

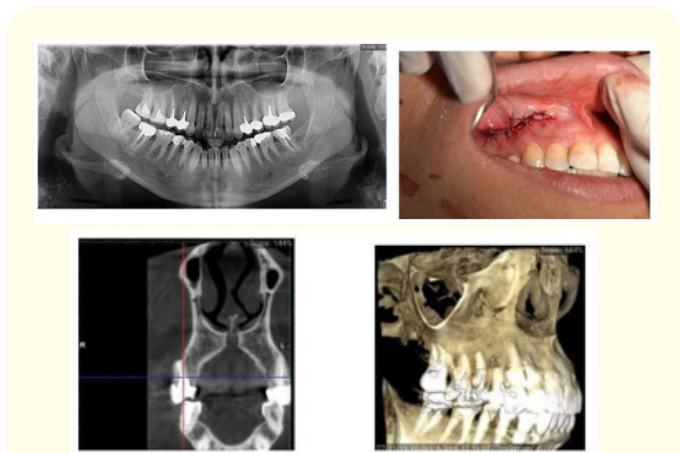


Figure 22: Incision on the mucogingival line without releasing incision.

The lower incisor region

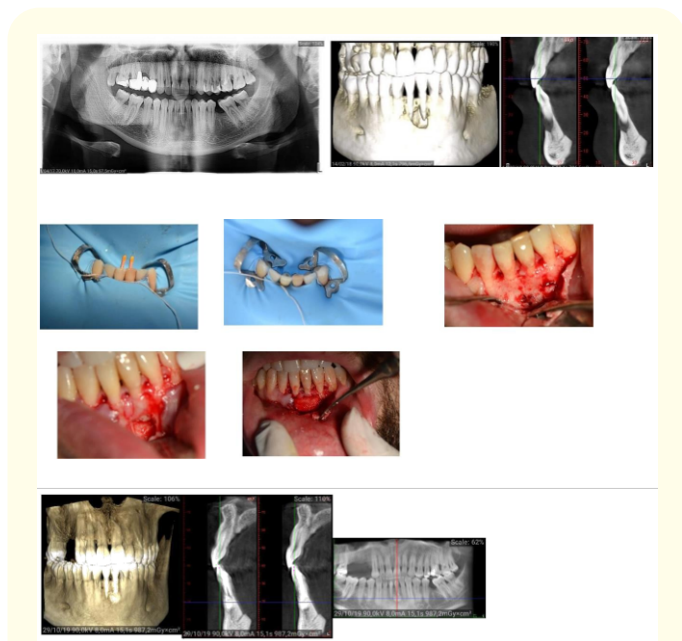


Figure 23: Case of an apical granuloma treated by apical surgery and MTA : mineral trioxide aggregate obturation on 31 with bone regeneration in a case of localised aggressive periodontitis, an intrasulcular flap was made for access to the apical area and also for scaling this sector.

Case of the upper incisor sector

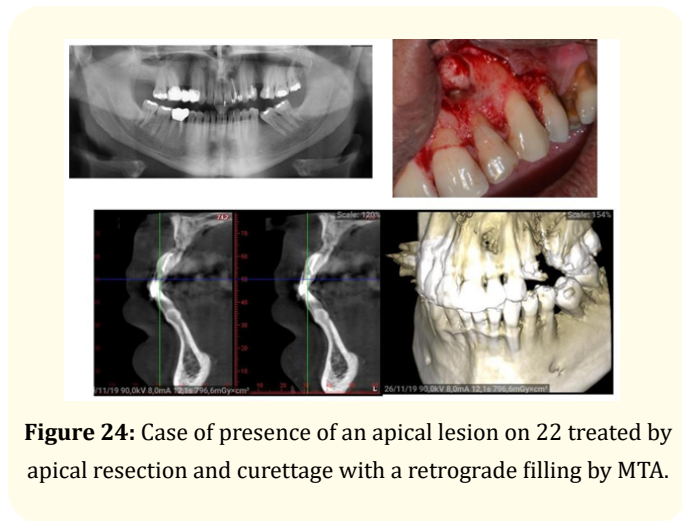


Figure 24: Case of presence of an apical lesion on 22 treated by apical resection and curettage with a retrograde filling by MTA.

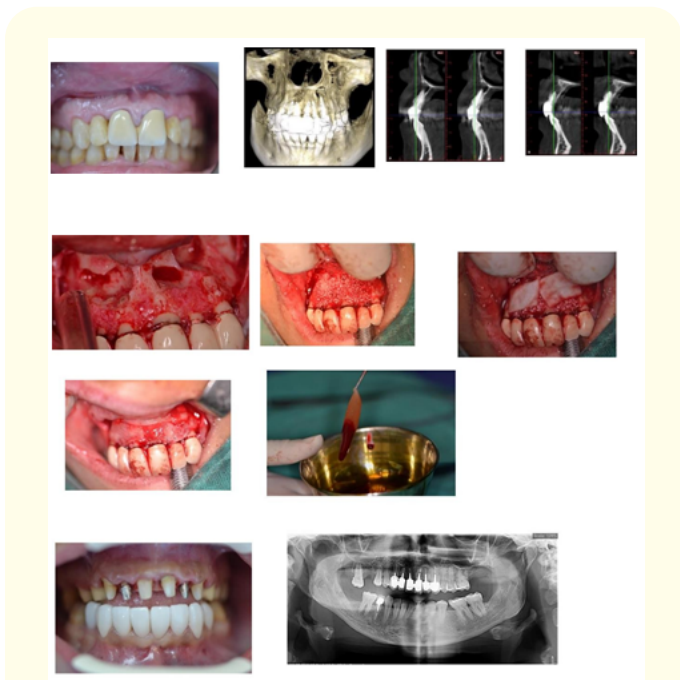


Figure 25: Case of apical surgery (curettage + apical resection + retrograde MTA : mineral trioxide aggregate obturation) with bone regeneration and use of a platelet concentrate (PRF) on the upper incisal sector from 13 to 23.all under general anesthesia.

Case of the upper molar sector

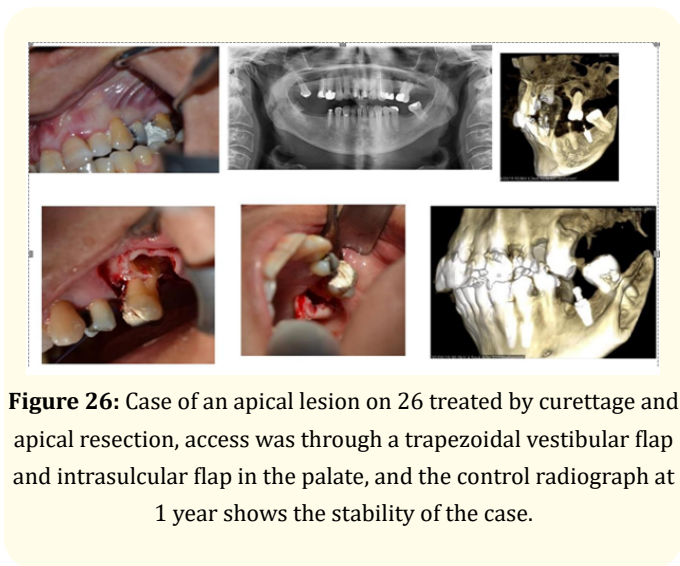


Figure 26: Case of an apical lesion on 26 treated by curettage and apical resection, access was through a trapezoidal vestibular flap and intrasulcular flap in the palate, and the control radiograph at 1 year shows the stability of the case.

Case of the lower molar sector

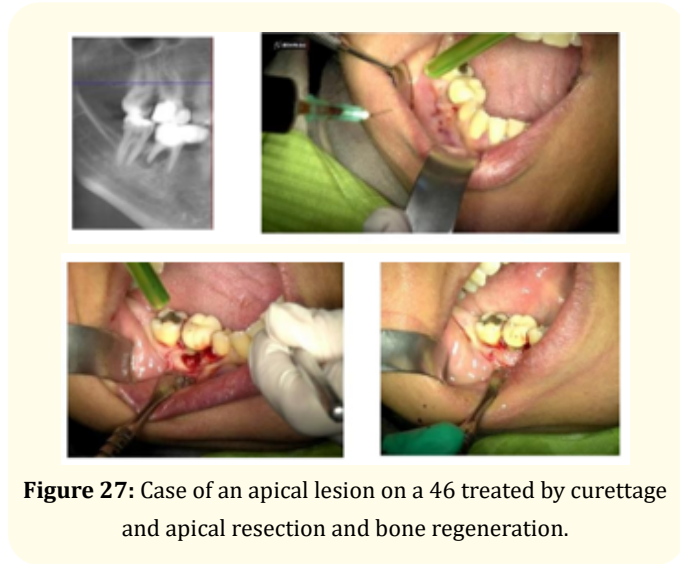


Figure 27: Case of an apical lesion on a 46 treated by curettage and apical resection and bone regeneration.

Conclusion

Apical surgery is currently a well codified technique, the use of new technology including 3D radiographic exploration, visual aids as well as the new generation of biomaterials for Root end sealing makes it possible to have a stable result over time.

Bibliography

1. Donald R Morse., *et al.* "Endodontic classification". *Journal of the American Dental Association* 94 (1977).
2. Francesc Abella., *et al.* "Applications of Piezoelectric Surgery in Endodontic Surgery: A Literature Review Piezoelectric Surgery in Endodontic Surgery". *Journal of Endodontics* 40.3 (2014).
3. Thomas von Arx. "Apical surgery: A review of current techniques and outcome". *Journal of Endodontics* 40.3 (2014).
4. Paul Chalakkal., *et al.* "Apicoectomy Versus Apexification". *Journal of Clinical and Diagnostic Research* 9.2 (2015): ZD01-ZD03.
5. Theodore A Nedderman., *et al.* "A Comparison of Root Surfaces following Apical Root Resection with Various Burs: Scanning Electron Microscopic Evaluation". *Journal of Endodontics* 14.9 (1988).

6. Xiao Zhang, *et al.* "A Cone-beam Computed Tomographic Study of Apical Surgery-related Morphological Characteristics of the Distolingual Root in 3-rooted Mandibular First Molars in a Chinese Population". *Journal of Endodontics* 43.12 (2017): 2020-2024.
7. Yuehong Fan, *et al.* "A Novel Prefabricated Grid for Guided Endodontic Microsurgery". *Journal of Endodontics* 45.05 (2019).
8. Márk Antal, *et al.* "Accuracy and clinical safety of guided root end resection with a trephine: a case series". *Head and Face Medicine* (2019).
9. Carlos Estrela and Gabriela Soares Couto. "Apical Foramen Position in Relation to Proximal Root Surfaces of Human Permanent Teeth Determined by Using a New Cone-beam Computed Tomographic Software". *Journal of Endodontics* 44.11 (2018): 1741-1748.
10. Ahmed Al-Kahtani. "Evaluation of root-end microcrack formation following retropreparation using different ultrasonic instruments". *Saudi Dental Journal* 21.1 (2009).
11. Thomas von Arx, *et al.* "5-year Results Comparing Mineral Trioxide Aggregate and Adhesive Resin Composite for Root-end Sealing in Apical Surgery". *Journal of Endodontics* 40.8 (2014).
12. Thomas von Arx, *et al.* "Bioceramic root repair material (BCRRM) for root-end obturation in apical surgery". *Swiss Dental Journal* 130 (2020).
13. C GRANDI and L PACIFICI. "Ratio in choosing access flap for surgical endodontics: a review". *Oral and Implantology* 2.1 (2009): 37-52.
14. Maria Peñarrocha Diago, *et al.* "Flap design: New perspectives in periapical surgery". *Journal of Oral Science and Rehabilitation* 56.3 (2017).
15. Ma X, *et al.* "Materials for retrograde filling in root canal therapy". *Cochrane Database of Systematic Reviews* 12 (2016): CD005517.
16. Vertommen Christelle. "Thèse: La Chirurgie Apicale: Les Données Acquises De La Science" (2013).
17. Cristian de Chevigny and Thuan T Dao. "Treatment Outcome in Endodontics: The Toronto Study-Phases 3 and 4: Orthograde Retreatment". *Journal of Endodontics* 34.2 (2008).
18. B S Chang and T R PITT FORD. "A prospective clinical study of mineral trioxide aggregate and IRM when used as root filling materials in endodontic surgery". *International Endodontic Journal* 36 (2003): 520-526.
19. Miguel Peñarrocha-Diago, *et al.* "State of the art and clinical recommendations in periapical implant lesions. 9th Mozo-Grau Ticare Conference in Quintanilla, Spain". *Journal of Clinical and Experimental Dentistry* 9.3 (2017): e471-473.
20. Domenico Ricucci, *et al.* "Histologic Response of Human Pulp and Periapical Tissues to Tricalcium Silicate-based Materials: A Series of Successfully Treated Cases". *Journal of Endodontics* 46.2 (2019)
21. Sinan Yasin-Ertem, *et al.* "The evaluation of apicectomy without retrograde filling in terms of lesion size localization and approximation to the anatomic structures". *Medicina Oral, Patología Oral y Cirugía Bucal* 24 (2016): e265-270.
22. Thomas von Arx, *et al.* "Treatment Decisions in 330 Cases Referred for Apical Surgery". *Journal of Endodontics* 40.2 (2014): 187-191.
23. Joško Grgurević, *et al.* "Frequency of Bacterial Content Finding in Persistent Periapical Lesions". *Acta Stomatologica Croatica* 51.3 (2017): 217-226.
24. Viola Hirsch, *et al.* "Apicoectomy of maxillary anterior teeth through a piezoelectric bony-window osteotomy: two case reports introducing a new technique to preserve cortical bone". www.rde.ac The Korean Academy of Conservative Dentistry.
25. Thomas von Arx, *et al.* "Changes of Root Length and Root-to-Crown Ratio after Apical Surgery: An Analysis by Using Cone-beam Computed Tomography". *Journal of Endodontics* 41.9 (2015).
26. Astrid Truschnegg, *et al.* "Long-term Follow-up for Apical Microsurgery of Teeth with Core and Post Restorations". *Journal of Endodontics* 46.2 (2019): 178-193.
27. Del Fabbro M, *et al.* "Endodontic procedures for retreatment of periapical lesions (Review)". *Cochrane Database of Systematic Reviews* 10 (2016): CD005511.
28. Stuart E. "Lieblich Endodontic Surgery". *Dental Clinics of North America* 56 (2012): 121-132.
29. Gianluca Gambarini, *et al.* "Endodontic Microsurgery Using Dynamic Navigation System: A Case Report". *Journal of Endodontics* 45.11 (2019): 1397-1402.
30. A Morfis, *et al.* "Study of the apices of human permanent teeth with the use of a scanning electron microscope". *Oral Surgery Oral Medicine Oral Pathology* 77.2 (1994): 172-176.
31. von Arx T and Walker WA. "Microsurgical instruments for root-end cavity preparation following apicoectomy: a literature review". *Endodontics and Dental Traumatology* 16 (2000): 47-62.

32. Syngcuk Kim and Samuel Kratchman. "Modern Endodontic Surgery Concepts and Practice: A Review". *Journal of Endodontics* 32.7 (2006): 601-623.
33. Abilio Albuquerque Maranhão de Moura., et al. "Morphological assessment of dentine and cementum following apicectomy with Zekrya burs and Er:YAG laser associated with direct and indirect Nd:YAG laser irradiation". *Oral Surgery, Oral Medicine, Oral Pathology, Oral Radiology, and Endodontology* 109.4 (2010): e77-e82.
34. Thomas von Arx., et al. "The resection angle in apical surgery: a CBCT assessment". *Clinical Oral Investigations* 20.8 (2016).
35. Thomas von Arx and Mohammed AlSaeed. "The use of regenerative techniques in apical surgery: A literature review". *The Saudi Dental Journal* 23 (2011): 113-127.
36. S Taschieri., et al. "Régénération tissulaire guidée en chirurgie endodontique (Guided-tissue regeneration in endodontic surgery)". *Revue de Stomatologie et de Chirurgie Maxillo-faciale* 109 (2008): 213-217.
37. Vivek Chaturvedy and Shefali Chaturvedy. "Regenerative Therapy as an Adjunct to Periapical Surgery: A Case Report". *International Journal of Clinical Pediatric Dentistry* 5.1 (2012): 75-77.
38. Thomas VON ARX and Dieter BOSSHARDT. "The use of Enamel Matrix Derivative (Emd) for Treatment of Combined Apico-marginal Lesions in Apical Surgery: A Retrospective Analysis". *European Endodontics Journal* 3 (2018): 146-152.
39. Ma X., et al. "Materials for retrograde filling in root canal therapy (Review)". *Cochrane Database of Systematic Reviews* 12 (2016): CD005517.
40. Astrid Truschnegg., et al. "Long-term Follow-up for Apical Microsurgery of Teeth with Core and Post Restorations". *Journal of Endodontics* 46.2 (2019): 178-193.
41. Thomas von Arx., et al. "A 10-year Follow-up Study of 119 Teeth Treated with Apical Surgery and Root-end Filling with Mineral Trioxide Aggregate". *Journal of Endodontics* 5.4 (2019): 394-401.

Assets from publication with us

- Prompt Acknowledgement after receiving the article
- Thorough Double blinded peer review
- Rapid Publication
- Issue of Publication Certificate
- High visibility of your Published work

Website: www.actascientific.com/

Submit Article: www.actascientific.com/submission.php

Email us: editor@actascientific.com

Contact us: +91 9182824667