



## Neutrocentric A Forgotten Concept-A Case Report

**Anand V and Manoharan PS\***

*Department of Prosthodontics, Indira Gandhi Institute of Dental Sciences,  
Crown and Bridge, India*

**\*Corresponding Author:** Manoharan PS, Department of Prosthodontics,  
Indira Gandhi Institute of Dental Sciences, Crown and Bridge, India.

**DOI:** 10.31080/ASDS.2020.04.751

**Received:** October 21, 2019

**Published:** January 07, 2020

© All rights are reserved by **Anand V and  
Manoharan PS.**

### Abstract

Residual ridge resorption is an inevitable and natural physiologic process which creates a challenging clinical scenario for the prosthodontist in fabrication of complete denture. It significantly affects the retention and stability of the complete denture. Numerous efforts were made over the years in the effective management of resorbed ridges by modification of the impression technique, occlusal scheme and arrangement of teeth in the neutral zone. This case report describes the management of a patient with severely resorbed mandibular ridge using neutrocentric occlusion to obtain adequate stability.

**Keywords:** Resorbed Ridge; Neutral Zone; Neutrocentric Occlusion; Stability

### Introduction

Denture stability is an important factor in determining the success of completed denture prosthesis. Stability of the denture is defined as that quality of complete denture to be firm, steady, or constant, to resist displacement by functional horizontal or rotational stresses. It is a tooth to bone relation which is sometimes confused with retention which is a tooth to mucosa relationship [1]. Obtaining stability in complete denture is challenging because of the differences between natural and artificial teeth like thickness, rigidity and site of the attaching membranes, especially in resorbed ridges where the remaining denture bearing area is inadequate.

M.M. De Van in 1954 proposed the concept "Neutrocentric Occlusion" in order to obtain maximum stability for the complete denture prosthesis. This concept revolves around the neutralization of the cuspal inclines and centralization of forces which acts on the denture bearing area during centric relation by incorporating various factors that aid in better stability in the complete denture and can therefore be used in cases with severe ridge resorption [2].

### Case Report

A 48 year old female patient reported to the department of prosthodontics and crown and bridge, Indira Gandhi institute of

dental science, Pondicherry with the chief complaint of missing teeth. The patient was completely edentulous over a period of 5 years and reported difficulty in chewing and speech. There was no relevant medical history. On examination the patient had severely resorbed mandibular ridge corresponding to Atwood's Class IV ridge resorption [3]. Wical and Swoope analysis was performed to estimate the amount of ridge resorption which indicated that two third or more of the mandibular height was lost (Class III) [4]. According to the American college of Prosthodontics the edentulous condition was observed to Class 3 [5]. A flabby tissue was also found in the anterior maxillary extending from canine region on one side to the other; blanching of these tissues was also seen on applying pressure. Surgical excision of the flabby tissue was indicated.

After adequate healing, maxillary and mandibular primary impression was made with irreversible hydrocolloid material and primary cast were immediately poured with Dental plaster (Type II gypsum). A custom tray was fabricated using autopolymerizing resin. Border molding was done with low fusing compound and a wash impression was made with zinc oxide eugenol paste for the maxillary arch. Secondary impression of the atrophic mandibular

ridge was done using admix which constituted seven parts of low fusing compound and three parts of high fusing compound, a wash impression was made with zinc oxide eugenol paste.

Beading and boxing of the secondary impression was done to secure the anatomic areas and the cast were poured in dental stone (type II Gypsum). Denture bases were fabricated using autopolymerising resin and occlusion rims were made. Jaw relation procedure was performed with a freeway space of 3 mm. Face bow transfer was done using a spring bow and the cast were articulated to a Hanau wide vue articulator in centric relation. The mandibular occlusion rim was carefully removed and a vertical stop was made using 19 gauge stainless steel wire. It was attached to denture base using auto polymerizing resin.

Neutral zone of the patient was recorded with admix which was placed around the stainless steel wire and the patient was asked to perform mandibular movements including swallowing, sucking of the lips and protrusion and side to side movement of the tongue. Putty index of the Neutral zone was made and new occlusion rim was fabricated based on the neutral zone. Cuspless teeth were arranged and trial denture insertion was done. Esthetics, phonetics and occlusion were verified and denture was processed using heat activated acrylic resin. Selective grinding was done and the denture was inserted. Denture training ball rest was made in the lingual inclines of the mandibular denture to train the patient to maintain the tongue position.

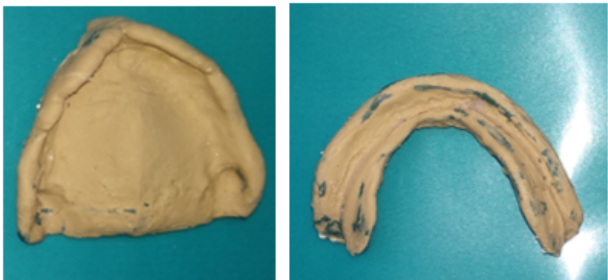


Figure 1: Secondary impression.

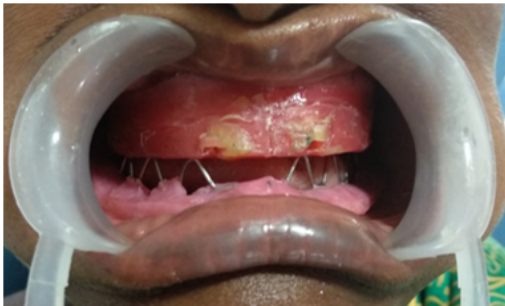

Figure 2: Vertical Stop.

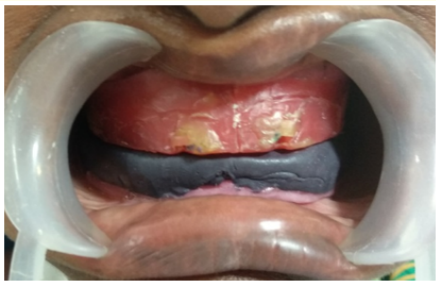

Figure 3: Recording the neutral zone with admix.




Figure 4: Occlusion rims articulated on a semi adjustable articulator.

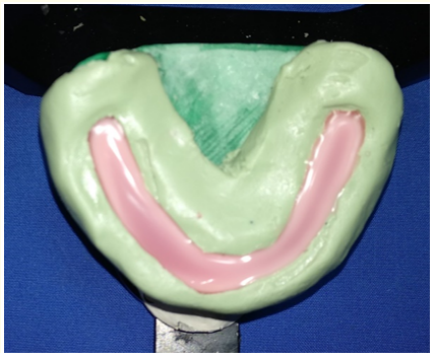

Figure 5: Index of the Neutral Zone.

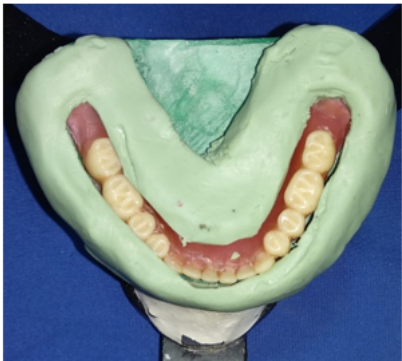
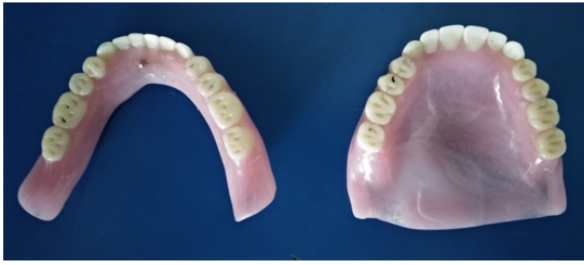
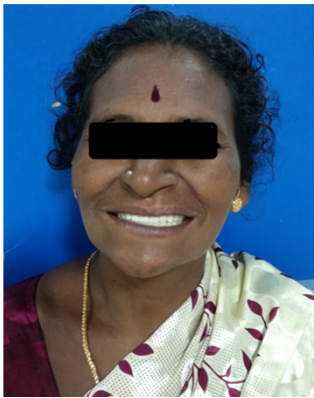Figure 6: Teeth arrangement in Neutral Zone.



**Figure 7:** Finished denture with tongue positioning ball.



**Figure 8:** Post Operative.

## Discussion

A number of factors contribute to the overall performance of the complete denture prosthesis. Achieving stability in a resorbed mandibular ridge is a challenge due to the decrease in the available surface area. Some modifications in treatment modalities were introduced in order to achieve stability of the dentures in resorbed ridges.

Neutral zone concept was coined by Beresin and Schiesser in 1976. It advocated the arrangement of teeth in the Neutral zone which is the area between cheeks and the tongue where the forces generated by the tongue will be neutralized by the forces generated by the lips and cheeks. The forces generated by the musculature will not unseat the denture there by increasing the stability of the denture [6]. Different types of occlusal schemes like

monoplane occlusion and lingualized occlusion were introduced to manage the resorbed mandibular ridges [7,8]. In the present case Neurocentric concept of occlusion was used to enhance the stability of the denture. The Neurocentric concept was proposed by M.M. De Van who proposed five factors which are involved in the relation of the teeth to the denture foundation. They are position, proportion, pitch, form and number.

**Position:** The posterior teeth are positioned in as central a position in reference to the residual ridge as far lingually as the tongue would allow, so that forces would be perpendicular to the support areas.

**Proportion:** Reduction of tooth width upto 40%. The vertical stress on the ridge is reduced by narrowing the occlusal table. Forces are centralized without encroachment on the tongue space.

**Pitch:** It is the inclination or tilt. The neurocentric concept aims to reduce inclination as found in the natural dentition and to parallel the pitch of the occlusal plane with that of the maxillary and mandibular base planes. Hence the plane of occlusion should be oriented so that it is parallel with the foundational base planes and thus by-passes the condylar incline. In addition, the compensating curve should be neutralized so that the posterior teeth are set on a plane rather than on a spherical surface.

**Form:** Flat teeth with no deflecting inclines are incorporated to avoid interference from the TMJ. The absence of cusp will also result in an unbroken occlusal plane.

**Number:** The posterior teeth are reduced in number from eight to six. This decreases the magnitude of the occlusal force and centralize it to the second premolar and first molar area. These factors were incorporated in the present case.

The functional assessment of the denture was obtained using a questioner which included assessment of freeway space, occlusion, retention and stability. The stability of the lower denture was assessed by observing the presence or absence of movement of the denture during functional movements and wide opening of the mouth. The masticatory efficiency of the patient was also analyzed. The assessment was performed immediately after the insertion, after one month and after six months of insertion [9].

### Incorporation of the five factors

Position	Established Using Neutral Zone Technique
Proportion	Selection of teeth with reduced buccolingual width
Pitch	*Establishing the occlusal plane parallel to the foundation *Neutralization of the compensating curves during teeth setting.
Form	Monoplane teeth used
Number	Reducing the mesio distal width of the teeth to centralize the forces in the second premolar and 1st molar region.

**Table 1**

### Conclusion

A Functional and esthetic rehabilitation of patients with resorbed mandibular ridge is an valuable service provided to the patient. In the present case, the Neurocentric occlusal scheme provided good stability to the denture which will further improved the function and esthetics of the patient. Further clinical trials must be conducted has to be to validate the effect of this treatment modality.

### Bibliography

1. Jacobson TE and Krol AJ. "A contemporary review of the factors involved in complete dentures. Part II: stability". *Journal of Prosthetic Dentistry* 49 (1983): 165-172.
2. De Van MM. "The concept of neurocentric occlusion as related to denture stability". *Journal of the American Dental Association* 48 (1954):165-169.
3. Atwood DA. "Reduction of residual ridges:a major oral disease entity". *Journal of Prosthetic Dentistry* 26 (1971): 266-279.
4. Wical KE and Swoope CC. "Studies of residual ridge resorption. Part I. Use of panoramic radiographs for evaluation and classification of mandibular resorption". *Journal of Prosthetic Dentistry* 32.1 (1974): 7-12.
5. McGarry TJ., *et al.* "Classification system for complete edentulism". *Journal of Prosthodontics* 8 (1999): 27-39.
6. Beresin VE and Schiesser FJ. "The neutral zone in complete dentures". *Journal of Prosthetic Dentistry* 36 (1976): 356-367.
7. Brudvik JS and Wormley JH. "A method of developing monoplane occlusions". *Journal of Prosthetic Dentistry* 19 (1968): 573-580.
8. Becker CM., *et al.* "Lingualized occlusion for removable prosthodontics". *Journal of Prosthetic Dentistry* 38 (1977): 601-608.

9. Corrigan PJ., *et al.* "The development of a method for functional assessment of dentures". *Gerodontology* 19 (2002): 41-45.

### Assets from publication with us

- Prompt Acknowledgement after receiving the article
- Thorough Double blinded peer review
- Rapid Publication
- Issue of Publication Certificate
- High visibility of your Published work

**Website:** [www.actascientific.com/](http://www.actascientific.com/)

**Submit Article:** [www.actascientific.com/submission.php](http://www.actascientific.com/submission.php)

**Email us:** [editor@actascientific.com](mailto:editor@actascientific.com)

**Contact us:** +91 9182824667