



Efficacy of Dual Venous Anastomosis in Microvascular Free Flap Surgery – A Comparative Study

Sagnik Sarkar, Senthil Murugan*, Velavan K, Komagan Prabhu and VB Krishna Kumar Raja

Department of Oral and Maxillo Facial Surgeon, India

*Corresponding Author: Senthil Murugan, Department of Oral and Maxillo Facial Surgeon, India.

Received: April 24, 2019; Published: May 28, 2019

DOI: 10.31080/ASDS.2019.03.0552

Abstract

Background: Various reports suggest the augmentation of venous drainage through performing two venous anastomoses as a means of reducing the rate of thrombosis in free flap surgery. In our study, we have evaluated the efficacy of dual venous anastomosis in micro vascular free flap surgery in head & neck region and establishing its feasibility as routine performance.

Methods: We evaluated 10 patients for the study, among the 10 patients, 7 were males and the rest of the 3 females with the age ranging from 20 to 51 years (mean: 30years). Patients were divided into 2 groups. In Group I (n=5) anastomosis, the donor and recipient vessels as a single artery and a single vein were anastomosed. In Group II (n=5) anastomosis, a single artery with two donor and recipient veins were anastomosed.

Results: In group I, out of 5 patients, 3 patients have obtained good functional and aesthetic outcome. However, 2 patients resulted with flap loss due to venous congestion on the fourth day and one week respectively. Whereas in group II, all 5 patients showed successful result.

Conclusion: Though it is time consuming, the study has shown the procedure is amicable and the outcome is predictable.

Keywords: Free flap Surgery; Venous Anastomosis; Single; Dual

Reconstructive microsurgery has tremendously progressed during the recent decades, as established proven techniques to address all kind of reconstructive defects [1,2]. Such defects are comprehensively treated with free tissue transfer that ensures the restoration of esthetics and basic functions in one stage. The success of free flap surgery is thus fully depending up on the anastomosis of arteries and veins of the flap and the orofacial region respectively. Despite many advantages, anastomosis of the vessels is the key factor for the successful outcome as the nourishment of the flap is relying on the anastomosis. Among the various factors involving in the flap failure, venous congestion is the commonest problem encountered during the early post anastomotic period [3,4]. Reduced suction pressures in the smaller veins, veins of the irradiated tissues are at increased risk. When such venous return from the flap is compromised, it leads to reduced arterial flow and eventually resulting in flap failure. In order to ensure the venous return from the flap, especially in large span flaps, dual venous anastomosis is considered as better option for the flap survival [5,6].

In our study, we have evaluated the efficacy of dual venous anastomosis in micro vascular free flap surgery in head & neck region and establishing its feasibility as routine performance.

Materials and Method

The prospective study on efficacy of dual venous anastomosis in micro vascular free flaps was performed in the Department of Oral and Maxillofacial Surgery, SRM Dental College, Ramapuram, Chennai, during a 3 year period between December 2013 and June 2015. Clearance was given by Institutional Review Board to perform the study. 10 patients were subjected to the study, among the 10 patients, 7 are males and the rest of the 3 are females with the age ranging from 20 to 51 years (mean: 30years). Inclusion criteria were fulfilled for all the patients taken up. All the 10 patients underwent primary reconstruction in which, 2 patients with oral submucous fibrosis were treated with radial forearm free flap and the 8 patients (4 patients with ameloblastoma, 4 patients with odontogenic keratocyst) were treated with vascularised free fibular flap.

Patients were divided into 2 groups. In Group I (n=5) anastomosis, the donor and recipient vessels as a single artery and a single vein were anastomosed. In Group II (n=5) anastomosis, a single artery with two donor and recipient veins were anastomosed. Conventional sutures like 8.0 and 9.0 prolene were used for arterial anastomosis while for vein conventional sutures (n=2 in Group I, n=5 in Group II) as well as micro vascular

couplers (n=2 in group I) and micro vascular staple clips (n=1 in group I) were used. In patients with free fibula flap, the fibula flap was harvested from the donor site via lateral approach (Figure 1). For all the patients right fibula was harvested. For patients with radial forearm free flap (Figure 2), one flap was harvested from left arm and one flap from right arm. All the vessels were anastomosed in an end to end manner for arterial anastomosis while for veins end-to-end or end-to-side for single (Figure 3) as well as dual anastomosis (Figure 4). Intra operative confirmation was done for patency of the anastomosed vessel, leakage, tissue perfusion and both surgical sites were sutured, drains placed and dressing done. Post operatively the viability of the grafted site was checked using Doppler and bone scan wherever hard tissue graft was placed.

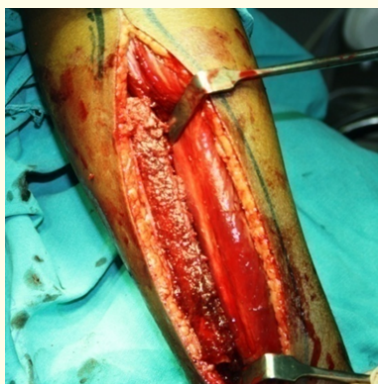

Figure 1: Fibula flap.

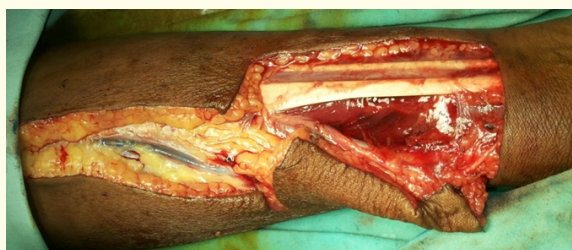

Figure 2: Radial forearm free flap.



Figure 3: Single venous anastomosis.

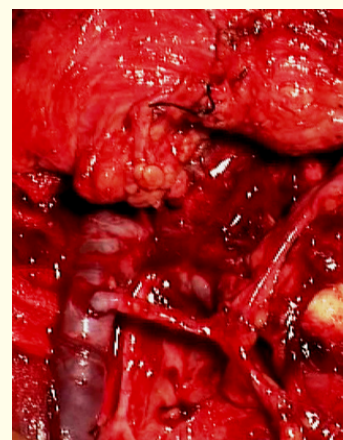


Figure 4: Dual venous anastomosis.

Results

The prospective study on efficacy of dual venous anastomosis in micro vascular free flap surgery for reconstruction of maxillo-mandibular defects was conducted in the Department of Oral and Maxillofacial Surgery, SRM Dental College, Ramapuram, Chennai, between December 2013 and June 2015. 10 patients were subjected to this study, among the 10 patients, 7 are males and the rest of the 3 are females with the age ranging from 20 to 51 years (Table 1). 10 patients underwent primary reconstruction in which, 2 patients were treated with radial forearm free flap for oral submucous fibrosis and the 8 patients were treated with vascularised free fibular flap for benign tumours (4 patients with ameloblastoma, 4 patients with odontogenic keratocyst) (Table 2,3). 10 patients were evenly divided into two groups for the comparative study on single and dual venous anastomosis. In group I, all the five patients were subjected for single venous anastomosis whereas in group II, the rest of the five patients were treated with dual venous anastomosis. The clinical parameters for evaluating the outcome of the procedure were, leakage in the site of anastomosis (Table 4,5), patency of the vessel, tissue perfusion and postoperative flap status (Table 6). Leakage of blood at the anastomotic site of veins for group I (Table 4) and group II (Table 5) were assessed and graded for each sutured vessel. In group I, grade I leakage (immediate bleeding that stops without intervention) was seen in case 2 and case 3. While in group II, grade I leakage was seen in case 2 and case 4. Immediate patency was observed for all the veins in group I as well as group II anastomosis. Milking test was done to confirm the patency. Tissue perfusion was checked for all the flaps. Pin prick test showed bleeding from the flap that confirmed the tissue perfusion was healthy in intra operative period.

MALE	7 Patients
FEMALE	3 Patients
AGE	20-51 years
MEDIAN AGE	30 years

Table 1: Patient details.

S. No	Age/Sex	Diagnosis of Disease	Flap	Recipient Vein
1	20/F	Odontogenic Keratocyst	Fibula	Facial
2	31/F	Ameloblastoma	Fibula	Facial
3	22/F	Odontogenic keratocyst	Fibula	Facial
4	24/M	Ameloblastoma	Fibula	Facial
5	28/M	Oral Submucous Fibrosis	Radial Forearm	External jugular

Table 2: Group I - Single Venous Anastomosis.

S. No	Age/Sex	Diagnosis of Disease	Flap	Recipient Vein
1	20/M	Ameloblastoma	Fibula	Facial, Internal jugular
2	35/M	Ameloblastoma	Fibula	Facial, External jugular
3	32/M	Odontogenic keratocyst	Fibula	Facial, Internal jugular
4	51/M	Odontogenic keratocyst	Fibula	Facial, Internal jugular
5	33/M	Oral Submucous Fibrosis	Radial Forearm	Facial, External jugular

Table 3: Group II – Dual Venous Anastomosis.

CASE 1	Nil
CASE 2	Grade I*
CASE 3	Grade I*
CASE 4	Nil
CASE 5	Nil

Table 4: Anastamotic leakage after venous anastomosis: Group I.

In group I, out of 5 patients, 3 patients have obtained good functional and aesthetic outcome. However, 2 patients resulted with flap loss due to venous congestion on the fourth day and one week respectively. Whereas in group II, all the 5 patients showed successful results. Flap perfusion was assessed immediately after anastomosis and was maintained throughout the follow-up period except for two cases in group I, perfusion was absent in post operative period where the flaps failed. The donor site was closed primarily and there was no donor-site morbidity seen.

	First vein	Second vein
CASE 1	Nil	Nil
CASE 2	Grade I*	Nil
CASE 3	Nil	Nil
CASE 4	Grade I*	Nil
CASE 5	Nil	Nil

Table 5: Anastamotic leakage after venous anastomosis: Group II.

*:-

Grade I – Oozing that stops without intervention.

Grade II - mild bleeding that can be stopped by gentle pressure.

Grade III - Profuse bleeding that requires re-clamping and additional suturing.

GROUP I	CASE 1	CASE 2	CASE 3	CASE 4	CASE 5
	-	+	+	-	-
GROUP II	CASE 1	CASE 2	CASE 3	CASE 4	CASE 5
	-	-	-	-	-

Table 6: Flap loss.

Discussion

Reconstruction of Maxillo Facial defects using free flaps have been practiced since few decades [7]. In the recent times, due to advent of technical as well as the developments in the gadgets, the applications of microsurgery have become wider in the field of reconstruction for addressing any kind of defects [8]. Reconstructing all kinds of defects in the orofacial region for regaining the form and basic functions primarily depending upon two factors namely, proper anastomosis of blood vessels and reduced flap ischemic time [9]. However, the successful outcome is predominantly depends upon the precise anastomosis for enhancing the circulation in the newly grafted tissues. The anatomical architecture and function of drainage in the vein are interrelated to carry out the proper flap physiology for the success of any flap surgery. When the veins are prone for congestion after anastomosis, the question of survival of the flap arises although most of the time the redress of the complication is carried out in the golden hour [10]. Such possible complications can either be prevented during surgery or corrected in the golden hour by re anastomosis of the vessels. In addition, incorporating the method of dual anastomosis (i.e. anastomosing one more vein) can bring down the level of flap failure to a greater extent [6]. Mean while, in our study, dual venous anastomosis has greatly helped in obtaining the thrombus free blood flow as the caliber of the veins eliminated thrombus by its pressure exertion. As the probability of venous thrombus is higher in incidence due to various factors like kinking, radiation fibrosis etc [11], dual anastomosis will be

on the safer side in sparing the flap to the maximum extent. This is due to the compensation of the venous drainage that is taken care by the second vein. The most common cause of failure in free tissue transfer flaps is venous occlusion [12,13]. Small vessel anastomosis results in an injury to the endothelium and media of vessel walls. Technical factors that accentuate the vessel damage at micro anastomosis include prolonged vasospasm induced by even gentle vessel dissection, use of large needles, obliquely placed sutures, unequal suture distance and excessive suture tension, excessive pressure on vessel walls from faulty approximating clamps, excessive bleeding from anastomotic sites, and prolonged stasis due to kinking at or near micro vascular anastomosis [10,14]. Technical expertise in the performance of anastomosis is more relevant for a favourable outcome than the method used to achieve vessel union. When the span of the flap increases and the surface area of the flap requiring more microcirculation, the dual venous anastomosis solves the problem by means of adequate venous drainage [15,16]. It is common for free flap to have 2 veins, and with the large number of vessels in the neck, it is often possible to perform a second venous anastomosis without compromising the first venous anastomosis. If one vein undergoes congestion or thrombosis, the other takes up the drainage thus preventing the flap to proceed towards loss. In ablative surgeries, where the flaps are bulky, they always require dual venous anastomosis to provide adequate venous drainage [12]. Given that the performing of an additional venous anastomosis confers a lower risk of complication and is technically feasible, where possible dual venous anastomosis should be performed in free flap procedures. Though there is no definitive study of single venous anastomosis failing only due to venous congestion, dual venous anastomosis still comes out as a saviour in cases prone to flap loss.

Conclusion

Based on this study, the following facts have come into light:

1. The advantage of using the second vein helps in compensation of venous drainage when the first vein gets congestion.
2. Though additional time is utilized for performing the second venous anastomosis, the successful outcome of the flap surgery is guaranteed.
3. As a result of venous pressure exertion in the flap is higher, the drainage is better and thus survival of the flap is ensured. Though it is time consuming, the study has shown the procedure is amicable and the outcome is predictable.

Bibliography

1. Eugene David Vaughan. "The Radial Forearm Free Flap in Orofacial Reconstruction - Personal Experience in 120 Consecutive Cases". *Journal of Cranio-Maxillofacial Surgery* 18.1 (1990): 2-7.
2. Torstein Lyberg and Olav Anders Olstad. "The Vascularized Fibular Flap for Mandibular Reconstruction". *Journal of Cranio-Maxillofacial Surgery* 19.3 (1991): 113-118.
3. Ian J. Beckingham., et al. "Free Flap Failure due to Venous Occlusion Secondary to Previous Intravenous Cannulation: a Case Report". *Microsurgery* 13.6 (1992): 348-349.
4. Jurgen Hoffmann., et al. "Complications after microsurgical tissue transfer in the head and neck region". *Journal of Cranio-Maxillofacial Surgery* 26.4 (1998): 255-259.
5. Akihiro Ichinose., et al. "Do Multiple Venous Anastomoses Reduce Risk of Thrombosis in Free-Flap Transfer? Efficacy of Dual Anastomoses of Separate Venous Systems". *Annals of Plastic Surgery* 52.1 (2004): 61-63.
6. Gary L., et al. "Ten Year Experience of Free Flaps in Head and Neck Surgery. How Necessary is a Second Venous Anastomosis?" *Head Neck* 30.8 (2008): 1086-1089.
7. Gregory R D., et al. "The Radial Forearm Free Flap for Head and Neck Reconstruction: A Review". *The American Journal of Surgery* 168.5 (1994): 446-450.
8. Douglas A., et al. "Use of the Operating Microscope and Loupes for Head and Neck Free Microvascular Tissue Transfer-A Retrospective Comparison". *Archives of Otolaryngology- Head and Neck Surgery* 129.2 (2003): 189-193.
9. Jurgen Hoffmann., et al. "Complications after microsurgical tissue transfer in the head and neck region". *Journal of Cranio-Maxillofacial Surgery* 26.4 (1998): 255-259.
10. Juan F., et al. "Operative Techniques in Otolaryngology". *Head and Neck Surgery* 4.2 (1993): 169-171.
11. Steve Mullholland., et al. "Recipient Vessel in Head and Neck Microsurgery: Radiation Effect and Vessel Access". *Plastic and Reconstructive Surgery* 92.4 (1993): 628-632.
12. Achilleas Thoma., et al. "Surgical Patterns of Venous Drainage of the Free Forearm Flap in Head and Neck Reconstruction". *Plastic and Reconstructive Surgery* 93.1 (1994): 54-59.

13. Ian J Beckingham., *et al.* "Free Flap Failure due to Venous Occlusion Secondary to Previous Intravenous Cannulation: a Case Report". *Microsurgery* 13 (1992): 348-349.
14. Nicholas P and McIvor. "How to Manage Failed Free Flaps. Operative Techniques in Otolaryngology". *Head and Neck Surgery* 4.2 (1993): 165-168.
15. Brian T., *et al.* "Does One or Two Vein Outflow Effect Outcomes in Head and Neck Microsurgery? Revisiting an Old Argument by Analyzing 317 Consecutive Free Tissue Transfers". *Supplement to Plastic and Reconstructive Surgery* 134(4S-1 Supplement) (2014): 11-12.
16. Wei F Chen., *et al.* "An Old Controversy Revisited- One Versus Two Venous Anastomoses in Microvascular Head and Neck Reconstruction using Anterolateral Thigh Flap". *Microsurgery* 34.5 (2014): 377-383.

Volume 3 Issue 6 June 2019

© All rights are reserved by Senthil Murugan., et al.