



CAD-CAM Supported Prosthetic Rehabilitation Using the Smart –Fix Implant Concept System

Emre Mumcu^{1*}, Sadeq Mohammed Taqi Fadhil² and Nesrin Saruhan³

¹Associate Professor Department of Prosthodontics, Faculty Of Dentistry Eskişehir Osmangazi University, Turkey

²Research Assistant, Department of Prosthodontics, Faculty Of Dentistry Eskişehir Osmangazi University, Turkey

³Assistant Profesor Department of Oral and Maxillofacial Surgery, Eskisehir Osmangazi University Faculty of Dentistry, Eskisehir, Turkey

***Corresponding Author:** Mumcu E, Associate Professor Department of Prosthodontics, Faculty Of Dentistry Eskişehir Osmangazi University, Turkey.

Received: March 01, 2019; **Published:** April 13, 2019

Abstract

Loss of teeth may lead to reshaping of the gravitational field, resorption around the alveolar bone and eventually atrophic alveolar ridge. There are several prosthetic treatment options available for this particular condition: complete dentures, implant-supported overdentures or implant-supported fixed prostheses. In terms of patient satisfaction, implant-supported fixed prostheses provide higher satisfaction than overdenture prostheses. The principle of the 'all on four' concept is the use of four implants at the front of the full toothless jaws to support a temporary, fixed and immediate prosthesis. While the anterior two implants are positioned at the normal angle, two implants placed in the posterior are placed at an angle to the distal to minimize the length of the elbow and allow the dentures to be applied to up to 12.

Case report describe us rehabilitation of a 68-year-old female patient with CAD-CAM Supported Prosthetic Rehabilitation Using the Smart –Fix Implant Concept.

Placing the implants in a more dense bone tissue region allows for less total treatment time, lower cost, and avoidance of multiple surgeries.

Keywords: Dental Implant; Implant Supported Fixed Prosthesis; Smart –Fix Concept

Introduction

Loss of teeth is a case that determines prosthetic planning and rehabilitation, which weakens chewing and speech from the most important functions of stomatognathic system. Loss of teeth may lead to reshaping of the gravitational field, resorption around the alveolar bone and at the end atrophic alveolar crest. Bone loss in maxilla and mandibula is not limited to alveolar bone, but also some of the basal bone can be resorbed. Progression of atrophy; The height of vertical dimension of bone and the width of horizontal dimension decrease [1].

Acute atrophy of the alveolar ridge in edentulous patients often improve following tooth loss. There are different prosthetic treatment alternative available for this certain condition: complete dentures, implant-supported overdentures or implant-supported

fixed prostheses. In point of patient satisfaction, implant-supported fixed prostheses provide higher satisfaction than overdenture prostheses [2-4].

Implant placement and positioning in the extremely resorbed crest makes the anatomical contiguity difficult. In the case of severe alveolar bone loss in the posterior region, the procedure for increasing the volume of surgical bone is necessary to obtain sufficient bone volume support for the placement of standard implants [5]. Regardless of prosthetic planning and prosthetic rehabilitation, Augmentation surgery carries higher risks such as unhealthy condition and complications of the patient (eg Infection, loss of graft material), in addition to the high costs required to complete the treatment and longer time periods [6]. Therefore, it has been demonstrated that there is no clinically significant

difference in success rates of distal implants compared to standard implants in order to avoid graft application in toothless jaws and to provide a more predictable implant protocol [7]. Brånemark and his colleagues have come up with a similar treatment with a similar approach and a special treatment option called the All-on-4 concept [8-10].

The principle of this concept is the use of four implants at the front of the full edentulous jaws to support a temporary, fixed and immediate prosthesis. While the anterior two implants are positioned at the normal angle, two implants placed in the posterior are placed at an angle to the distal to minimize the length of the abutment and allow the dentures to be applied to up to 12 teeth [11]. The all-on-4 (Nobel Biocare) technique has been widely used in the 10 years after it has been defined, and it is still being used successfully in cases where the jaws cannot be treated by conventional methods [12,13].

The Ankylos implant developed in 1985 by Moser and Nentwig [14]. It is designed with considering the following conditions: it must be globally applicable as post-implant or immediate implant prosthesis, maximum primary stability in inappropriate bone structures, it should allow ideal load distribution for permanent bone stability during functional loading, it should facilitate soft tissue stability due to tapered anchor connection with mechanical stability as much as possible, provide a simple prosthetic option with implant treatment along with the remaining natural teeth in the mouth and should be economical.

SmartFix, it is a treatment concept in which can provide almost complete, full arch prostheses supported by only four implants immediately to edentulous patients. The SmartFix concept is engineered to include an angular abutment with a short and flexible abutment holder for convenience. The easy access of the screw in the duct along the prosthesis provides an optimal aesthetic and functional design. This concept is a useful and low-cost treatment designed to provide the necessary treatment satisfaction for patients who are not satisfied with the use of mobile prostheses due to the lack of adequate bone. SmartFix is available for the Astra Tech Implant System EV product line, including Profile EV [15].

Case Report

A 68-year-old female patient presented to our clinic with complaints of loose and disturbing removable prosthesis. Intraoral

examination revealed maxillary and mandibular arch resorption. The orthopantomograph and cone beam were referred for computed tomography imaging (Figure 1 and 2).

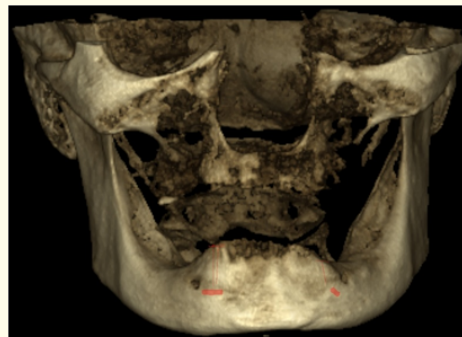


Figure 1

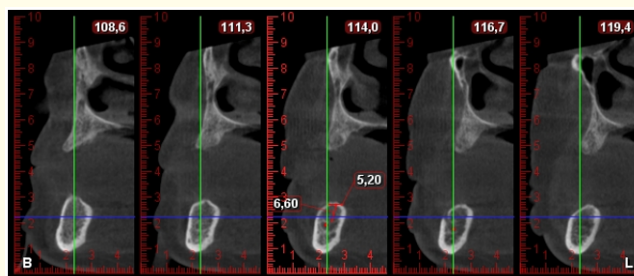


Figure 2

After the necessary evaluations were made, the patient was informed about the different prosthesis options and referred to the surgery department. At the request of the implant-supported fixed prosthesis, 4 implants were placed in the mandible (SmartFix concept). The standard 6 implant (Ankylos) was inserted into the maxilla (Figure 3).

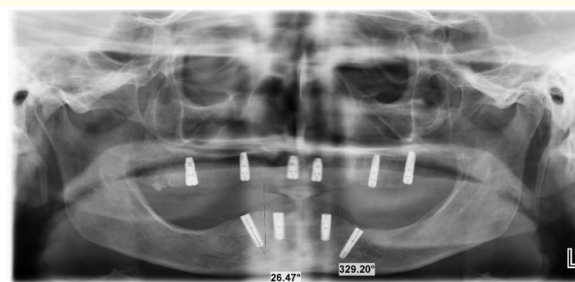


Figure 3

After three-month follow-up period, the measurement of first step of prosthetic stage was measured by open spoon method using silicone polysiloxane measurement material (Dentsply Aquasil light body consistency) and the models were obtained. The vertical dimension was determined by the Niswonger method. Type of

occlusion, cantilever length, technique and materials to be used in prosthetic prosthesis were evaluated. Then, the metal substructure of the implant-supported fixed prosthesis was designed in a short time without error (Figure 4).

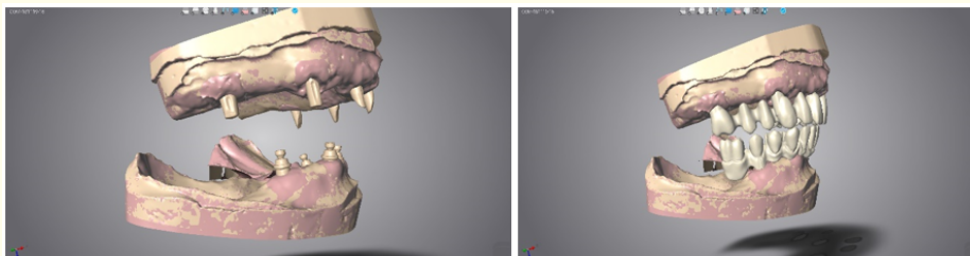


Figure 4

After controlling the vertical dimension, midline, smile line and occlusion, the metal substructure was checked. Porcelain superstructure was processed in the laboratory after color selection. Completed the prostheses, all the implant elements

according to the manufacturer's instructions after fixing the torque values, soft tissue alignment, vertical size and ideal occlusion were evaluated in terms of necessary corrections were made (Figure 5).

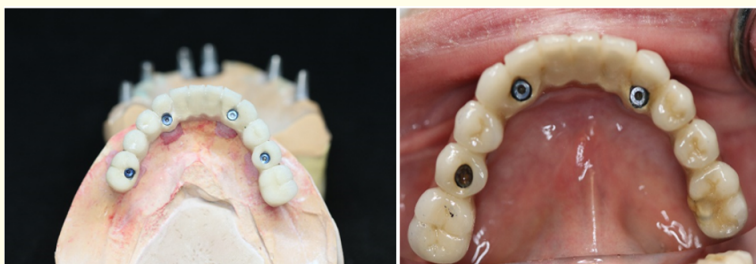

Figure 5

For the polishing process, while removing the prostheses, the opposite torque values were taken into consideration. After polishing, the prostheses were fixed to the lower and upper jaws. To reach the abutment screw, it was covered with composite resin after teflon reaction on the screws present in the occlusal.

Periodic controls of patient were performed once a month for first three months and their occlusal movements and oral hygiene were evaluated. No loss was observed around the implants in panoramic radiography taken. For oral hygiene, mouth shower was also used as an aid to the toothbrush, and no periodontal disease was encountered.

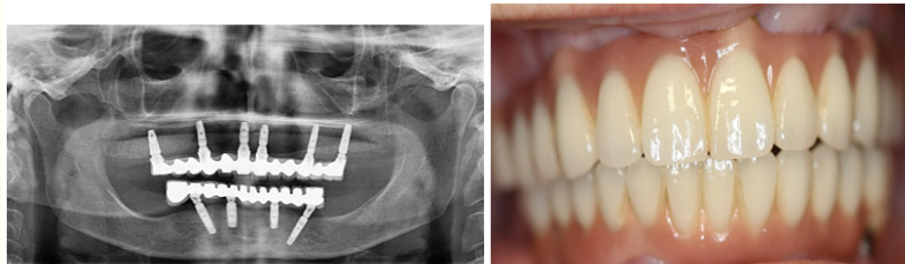


Figure 4

Discussion

The aesthetic and function lost by the patient can be recovered at an acceptable level through implant-supported restorations, a strong prosthetic rehabilitation can be provided to the patient in terms of restraint and support [16].

Dental implant-supported fixed dentures are made of porcelain machined teeth on a metal infrastructure. The prosthesis is fixed on the implants or abutments by the physician by the screw. In this way, while there is no problem with retention during use, the denture can be easily removed by the dentist due to different reasons. Studies have shown that this type of prosthesis provides a higher quality of life psychosocially than implant supported overdenture and conventional removable prostheses. Providing a quality of life close to the natural teeth and an acceptable recovery of lost function brings a significant psychological advantage to patients [11].

The concept of all four cannot be considered a traditional treatment by some clinicians. However, this treatment concept uses four implants to support a fixed prosthesis without advanced surgical techniques, and is extremely interesting for most patients in terms of cost and comfort [17]. The current treatment concept appropriately utilizes the bearing capacity of the maxillary bone. Due to their curvature permissiveness, the implants can be attached to intense bone structures (high-density anterior bone) and are effectively spread to the anterior succession by providing an useful prosthetic base. by reducing the number of implants [18].

In a ten-year retrospective study, 156 patients with prosthesis rehabilitated on 4 and 6 implants evaluated the survival index of prosthesis/implants. The results showed that, after ten years, the survival index of implants and prostheses was the same for both groups [10]. In this concept, the angular placement of the implant has many advantages: including apical cortical fixation, increased implant length, and, increased anteroposterior spread and decreased length of cantilevers [19].

In this case report, it was concluded that the application of fixed prosthesis on maxilla 6 and mandibula 4 gave the patient a psychological advantage in recovery of function, phonation and esthetics.

Conclusion

Based on many studies, it is recommended to use angled implants in cases of extreme atrophy in the posterior region. The main advantages of this technique compared with bone graft or zygomatic implant techniques are less surgical morbidity and optimal use of residual alveolar crest. Placing the implants in a more dense bone tissue region allows for less total treatment time, lower cost, and avoidance of multiple surgeries.

Bibliography

1. Blum IR and JFJCoir McCord. "A clinical investigation of the morphological changes in the posterior mandible when implant-retained overdentures are used". 15.6 (2004): 700-708.
2. Fortin Y., *et al.* "The Marius implant bridge: surgical and prosthetic rehabilitation for the completely edentulous upper jaw with moderate to severe resorption: a 5-year retrospective clinical study". 4 (2002): 69-77.
3. Selim K., *et al.* "Implant supported fixed restorations versus implant supported removable overdentures: A systematic review". 4 (2016): 726.
4. Oh SH., *et al.* "Comparison of fixed implant-supported prostheses, removable implant-supported prostheses, and complete dentures: patient satisfaction and oral health-related quality of life". 27 (2016): e31-e37.
5. Ali SA., *et al.* "Implant rehabilitation for atrophic maxilla: a review". 14 (2014): 196-207.
6. Jensen A.T., *et al.* "Complications related to bone augmentation procedures of localized defects in the alveolar ridge. A retrospective clinical study". 20 (2016): 115-122.
7. Maló P., *et al.* "All-on-4 immediate-function concept with Brånemark System® implants for completely edentulous maxillae: a 1-year retrospective clinical study". 7 (2005): s88-s94.
8. Maló P., *et al.* "All-on-Four" immediate-function concept with Brånemark System® implants for completely edentulous mandibles: a retrospective clinical study". 5 (2003): 2-9.

9. Maló, *et al.* "The rehabilitation of completely edentulous maxillae with different degrees of resorption with four or more immediately loaded implants: a 5-year retrospective study and a new classification". 4 (2011).
10. Brånemark, *et al.* "Ten-year survival rates of fixed prostheses on four or six implants ad modum Brånemark in full edentulism". 6 (1995): 227-231.
11. Patzelt SB, *et al.* "The all-on-four treatment concept: a systematic review". 16 (2014): 836-855.
12. Maló P, *et al.* "A ll-on-4® Treatment Concept for the Rehabilitation of the Completely Edentulous Mandible: A 7-Year Clinical and 5-Year Radiographic Retrospective Case Series with Risk Assessment for Implant Failure and Marginal Bone Level". 17 (2015): e531-e541.
13. Taruna M, *et al.* "Prosthodontic perspective to all-on-4® concept for dental implants". 8 (2014): ZE16.
14. Unterkiefertotalprothesen I, Zeitschrift für Zahnärztliche Implantologie 1/2004 JDI Journal of Dental Implantology. (2004).
15. Fangmann R, Wie wird die Implantatprothetik in Bezug auf die zahngetragene Prothetik wahrgenommen und reflektiert? (2017).
16. Maló P, *et al.* "Retrievable metal ceramic implant-supported fixed prostheses with milled titanium frameworks and all-ceramic crowns: retrospective clinical study with up to 10 years of follow-u 2012". 21 (2012): 256-264.
17. Khatami AH and C.R.J.o. Smith. "'All-on-Four" immediate function concept and clinical report of treatment of an edentulous mandible with a fixed complete denture and milled titanium framework". 17 (2008): 47-51.
18. Krekmanov L, *et al.* "Tilting of posterior mandibular and maxillary implants for improved prosthesis support". 15 (2000).
19. Jensen OT, *et al.* "Paranasal bone: the prime factor affecting the decision to use transsinus vs zygomatic implants for biomechanical support for immediate function in maxillary dental implant reconstruction". 2 (2012).

Volume 3 Issue 5 May 2019

© All rights are reserved by Emre Mumcu, *et al.*