

## Prosthetic Management of Dental Fluorosis

**Zeineb Riahi<sup>1</sup>, Anissa Ben Moussa<sup>1</sup>, Mayssa Jbeniany<sup>1</sup>, Belhassen Harzallah<sup>3</sup>, Mounir Cherif<sup>4</sup>, Dalenda Hadyaoui<sup>2\*</sup>**

<sup>1</sup>Fixed Prosthodontic Monastic, Faculty of Dental Medicine, Tunisia

<sup>2</sup>Professor, Fixed Prosthodontic Monastic, Faculty of Dental Medicine, Tunisia

<sup>3</sup>Director of the Research Laboratory, Fixed Prosthodontic Monastic, Faculty of Dental Medicine, Tunisia

<sup>4</sup>Head of the Department, Fixed Prosthodontic Monastic, Faculty of Dental Medicine, Tunisia

**\*Corresponding Author:** Dalenda Hadyaoui, Professor, Fixed Prosthodontic Monastic, Faculty of Dental Medicine, Tunisia.

**Received:** February 15, 2019; **Published:** April 08, 2019

### Abstract

Dental fluorosis is one of the most common colour disorders to be observed. It results in discoloured teeth, with white or brown spots. The aspect may be different depending on the severity of the fluorosis and the degree of the damage of the enamel. This article describes two prosthetic approaches to treat a severe and mild dental fluorosis, based on full coverage crowns. This option allows us to totally remake the patient's unpleasant smile.

**Keywords:** Dental Fluorosis; Veneers; Crowns; Index; Dentistry Management

### Introduction

Excessive exposure to a high amount of fluoride during enamel development is the main cause of enamel demineralization and porosity, causing dental fluorosis. The prevalence of fluorosis within a population is from 2.1% to 74.7% [3]. Dental fluorosis is a major problem in Tunisia, particularly in the endemic areas (where phosphate fields are concentrated) [7]. This disorder was first described by McKay and GV Black back in 1916 [9]. It appears as a range of visual changes in teeth's enamel, whether by intrinsic discolorations or even physical damages in enamel's structure. Researches in several areas with or without added fluoride in drinking water were able to identify four sources involved in increasing the risk of dental fluorosis which are: fluoridated drinking water, fluoride supplements, topical fluoride (toothpaste), and formula prescribed for children. In the 1940s, Dean et al could establish a strong relationship between fluoride concentration in drinking water and the prevalence and severity of dental fluorosis [6]. The fluoride concentration in drinking water in Tunisia is between 0.1 and 7 ppm<sup>2</sup> [7]. This disturbance, affecting the enamel while its development, is caused by an excessive exposure to fluoride within the first years. The period of risk is identified as 21 to 30 months of age for females and 15 to 24 months of age for males [6].

To establish an adequate fluorosis diagnosis, teeth should be examined after cleaning and drying their surfaces under a good source of light [6]. Based on the severity of enamel damage, many classifications of dental fluorosis were proposed [10]. The first index was proposed by Dean in 1934, and still used until now, to establish an appropriate diagnosis for this disorder.

#### Dean's index

- Questionable: occasional white fleckings and spottings of enamel
- Mild: white opaque areas involving more of the tooth surface
- Moderate and severe: pitting and brownish staining of tooth surface
- Corroded appearance of tooth

Many other indexes are also available, but the most commonly used is TF score, proposed by Thylstrup and Fejerskov in 1978, which is:

1. Normal translucency of the glossy creamy white enamel remains after wiping and drying of the surface
2. Thin white lines are seen across the tooth surface
3. Opaque white lines are more pronounced and frequently merge to form small cloudy areas scattered over the whole surface of the tooth

4. Merging of white lines occurs, and cloudy areas of opacity occurs spread over many parts of the surface. In between the cloudy areas, white lines also can be seen
5. The entire surface exhibits a marked opacity or appears chalky white
6. The entire surface is opaque and there are round pits
7. The small pits frequently merge in the opaque enamel and forms bands
8. There is loss of outer surface of enamel in irregular areas and less than half the surface is involved
9. The loss of outer most enamel surface is more than half the enamel
10. The loss of major part of the outer enamel results in change of anatomical shape of the tooth [1]

Nowadays, the differential diagnosis between fluorosis and non-fluoride-induced opacities needs to establish differences between symmetrical and asymmetrical and/or discrete patterns of opaque defects [5].

The practitioner faced with this problem, have different treatment options: bleaching, microabrasion, veneers, or full crowns. The choice between these different options depends on the severity of the enamel damage. Two different approaches are presented by the following clinical situations:

#### First case presentation

A 46-year-old-male-patient presented to our department with a chief complaint "unpleasant aesthetics due to teeth discoloration".

The clinical examination showed a satisfactory oral hygiene. A discoloured enamel with yellow and brown stains spread on almost all his teeth was observed. Chalky thin white lines were also noticed across the teeth surfaces. The occlusion was favourable and no particular gingiva problems were detected (Figure 1).

**Figure 1:** Intra-oral view at the first session.

The patient reported that he had already undergone many bleaching and microabrasion sessions, but still not satisfied with the results. He wanted to have new white teeth.

The radiography examination showed no caries or bone loss. Moderate dental fluorosis was diagnosed. The decision was to perform porcelain veneers from tooth #15 to tooth #25.

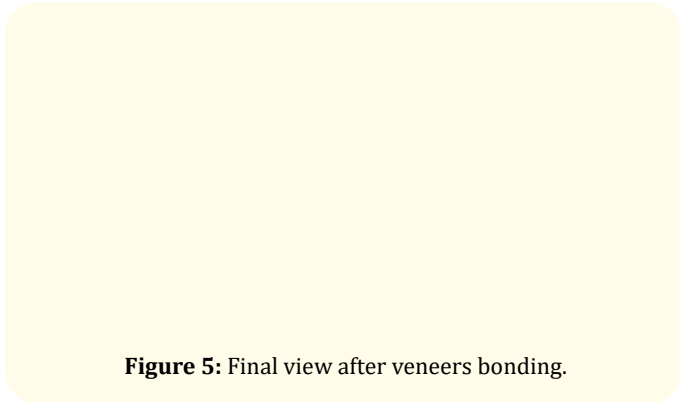
We began by photographs, smile analysis, shade selection and study cast waxing. After that, teeth preparations were performed, a final shade selection was confirmed (Figure 2) The master impression was taken and sent to the laboratory technician. The master cast was then scanned and used for the design and fabrication of IPS e.max veneers (Figure 3-5).

**Figure 2:** Teeth preparations.

**Figure 3:** A :Facial view of ceramic veneers on the cast, B : Palatal view of the ceramic veneers on the cast

The try-in was then made. And after checking the veneers fit and the patient acceptance of the final aesthetic result, veneers were bonded.

**Figure 4:** Teeth etching.

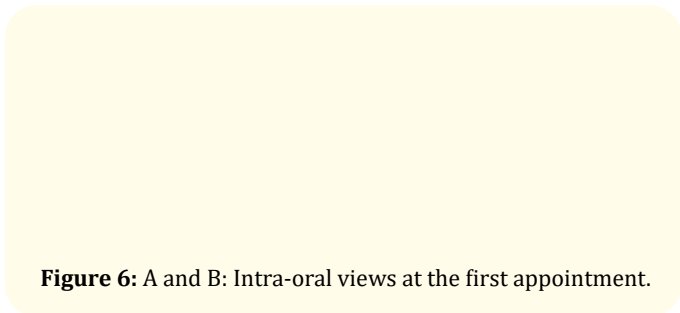


**Figure 5:** Final view after veneers bonding.

**Second Case presentation**

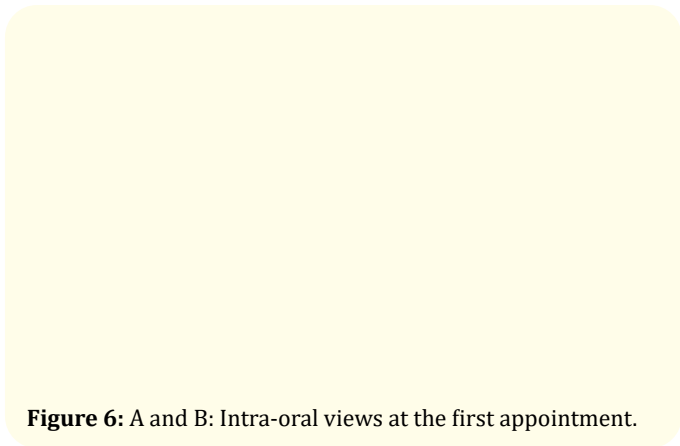
A 32 year-old-female-patient consulted our department to rehabilitate her smile, that she found unpleasant due to teeth discoloration. The patient had non contributory medical history and was very motivated to a highly aesthetic treatment.

A clinical examination was conducted at the first session. It revealed a non-satisfactory oral hygiene but a healthy gingiva. The teeth examination showed a discoloured and pitted enamel with symmetrical patterns of opaque defects and wide spread yellow to brown stains, added to several vertical cracks (Figure 6A). A deep vertical bite and a class 1 relationship occlusion were remarked (Figure 6B). A big resin composite restauration was detected in tooth #12, that was already prepared but not crowned.



**Figure 6:** A and B: Intra-oral views at the first appointment.

The radiographic examination showed no particular anomalies. A periapical radiography of tooth #12 was conducted, and it showed a satisfactory root canal treatment, and a cervical limit of the tooth decay near to the bone edge (Figure 7).

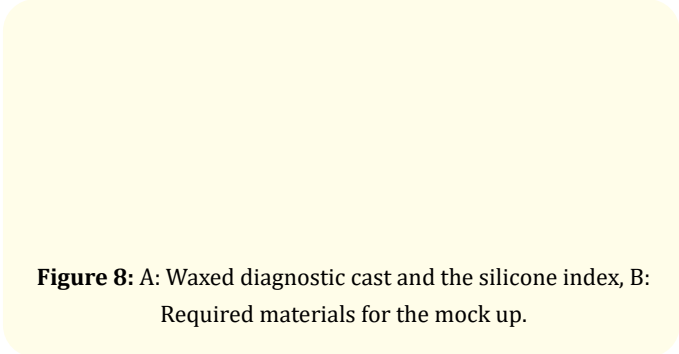


**Figure 6:** A and B: Intra-oral views at the first appointment.

A severe dental fluorosis was diagnosed, based on the clinical data and the Dean’s index. The suitable treatment option was to make full coverage Zirconia based crowns from tooth #15 to tooth #25, with a metallic post and core on tooth 12.

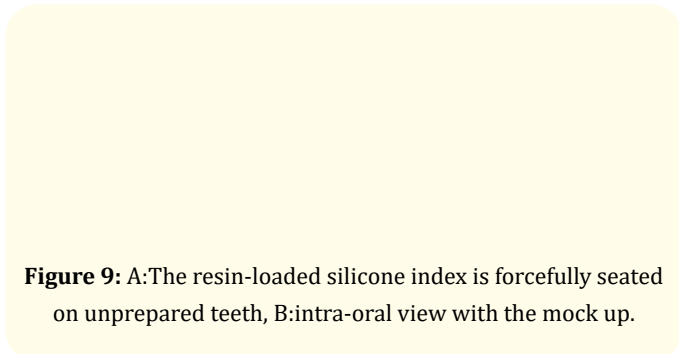
We first started with a teeth planning and scaling, recommending oral hygiene instructions for the patient, to guaranty a favourable environment for the intended prosthetic treatment. After that, we proceeded to the reconstruction for tooth #12, using a post and core made from a casted resin pattern, after canal preparation.

The diagnostic cast was then waxed, and used to fabricate a silicone index for mock up (Figure 8A and B).



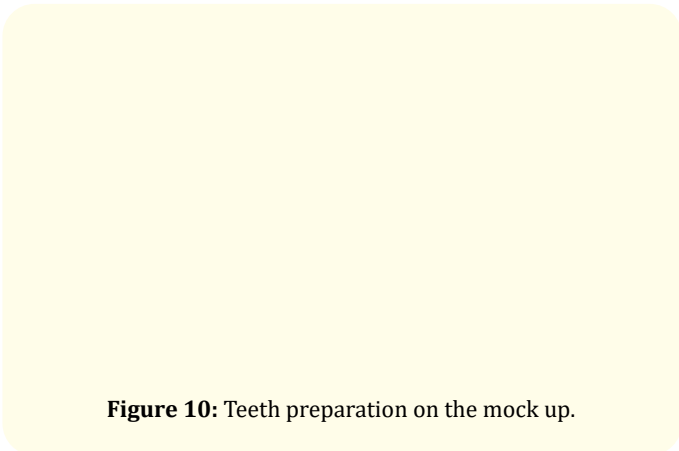
**Figure 8:** A: Waxed diagnostic cast and the silicone index, B: Required materials for the mock up.

The mock up was made to give the patient an overview of the final result we could reach and to facilitate the control of the preparations in favour of a minimally invasive procedure (Figure 9).



**Figure 9:** A: The resin-loaded silicone index is forcefully seated on unprepared teeth, B: intra-oral view with the mock up.

The preparation was then made, on the mock up (Figure 10).



**Figure 10:** Teeth preparation on the mock up.

After teeth preparations (Figure 11), the master impression was made. The shade was also selected at the same session. The master cast was then scanned and used to fabricate the zirconia frameworks of the crowns.

**Figure 11:** Teeth preparations.

In the next two sessions, Zirconia frameworks (Figure 12 A and B), and final full crowns were tried and checked (Figure 13). The patient was satisfied with the form, shape and shade of the crowns. Therefore, the final cementation was made with CVI MAR. the patient was given several hygiene instruction, and called for a control session in 3 months (Figure 14).

**Figure 12:** A : Zirconia frameworks,  
B : Zirconia frameworks try-in.

**Figure 13:** Final try-in.

**Figure 14:** The patient smile after crowns cementation.

## Discussion

Aesthetic changes in dental fluorosis are the biggest concerns of our patients. Controlling the amount of fluoride intake is the best preventive measure to fluorosis. However, when it is already installed, causing aesthetic problems, many treatment options are described. It depends on how advanced the fluorosis is. It has been shown that bleaching procedure can be considered as a treatment for dental fluorosis as it is non-invasive [8]. Researches agreed that the bleaching effect would be noticed only on moderate cases [12]. Other researches have shown that patients with mild to moderate fluorosis can be treated with microabrasion technique [3]. This technique allows excellent short term results. But it can be very invasive, since removing so much dental tissue with rotary instruments. It also can't be effective on severe cases, it should be used, particularly, for discolorations presented as single lines or patchy discolorations.

The most recent studies have shown that patients with severe dental fluorosis and loss of vertical dimension of occlusion might be good candidates for porcelain veneer or ceramic crowns [4].

The porcelain veneers for the first case, were chosen for their highly aesthetic income, biocompatibility, durability and high translucency [11]. The concept of veneering was always described in literature with effective bonding. To achieve an effective bonding a good enamel etching should be performed. However, the hypermineralized fluorotic enamel, where hydroxyapatite are replaced with fluoroapatite, is expected to be more resistant to etching. Therefore, for moderate to severe fluorosis, it's recommended to double the time of enamel etching with the phosphoric 37% acid [2].

For the second case, veneers could not be indicated, because of the deep bite of the patient. And since it was diagnosed as severe dental fluorosis, the prosthetic decision was full zirconia based crowns.

Zirconia based crowns were chosen for the ability of zirconia framework to mask the residual effect of discoloration after preparation. We should also not forget that we needed to totally cover the post and core (metallic reconstruction) on tooth #12. Only zirconia would offer that thanks to its opacity. The idea was to use the same ceramics on all teeth, to avoid any color discrepancy that could occur with different materials.

Each of the treatments described has its cons and pros. The practitioner should be aware of all treatment options he might choose. The choice should be basically depending on the particularities of the clinical case.

## Conclusion

Dental fluorosis is a major problem due to the unpleasant aesthetics it causes. The choice of the treatment option should respect the therapeutic gradient and depends on the severity. Minimally invasive options should be preferred. However, in some cases, we have no choice but to be conventional. In these cases, the practitioner must carefully consider his indications.

## Bibliography

1. Abiodun-SolankeIyabo M., *et al.* "Dental Fluorosis and its Indices, what's new?". *IOSR Journal of Dental and Medical Sciences (IOSR-JDMS)* 13 (2004): 55-60.
2. Akpata ES. "Therapeutic management of dental fluorosis: A critical review of literature". *Saudi Journal of Oral Sciences* 1 (2014): 3-13.
3. Ardu., *et al.* "A minimally invasive treatment of severe dental fluorosis". *Quintessence International* 38.6 (2007): 455-458.
4. Barbara Slaska., *et al.* "Restoration of Fluorosis Stained Teeth: A Case Study". *Dental Clinics* 62.3 (2015): 341-510.
5. I Anand Sherwood. "Fluorosis varied treatment options". *Journal of Conservative Dentistry* 13 (2010): 47-53.
6. Jenny abanto alvarez., *et al.* "Dental fluorosis: exposure, prevention and management". *Journal of Clinical and Experimental Dentistry* 1 (2009): e14-18.
7. Maatouk F., *et al.* "Dental fluorosis in Kairouan, Tunisia". *Dental News* 1 (1998): 17-19.
8. Narendra Varma Penumatsa and Rajashekhara Bhari Sharanesha. "Bleaching of fluorosis stains using sodium hypochlorite". *Journal of Pharmacy and Bioallied Sciences* 7 (2015): S766-S768.
9. Nitin Habbu., *et al.* "Esthetic management of Dental Fluorosis". *International Journal Of Dental Clinics* 3 (2011): 80-81.
10. PJ Riordan. "Perceptions of Dental Fluorosis". *Journal of Dental Research* 72.9 (1993).
11. Rodd HD and Davidson LE. "The aesthetic management of severe dental fluorosis in the young patient". 24 (10): 408-411.
12. SLASKA., *et al.* "Restoration of fluorosis stained teeth: a case study". *Dental Clinics* 59 (2015): 583-591.

**Volume 3 Issue 5 May 2019**

© All rights are reserved by Dalenda Hadyaoui, *et al.*