



## Short Implant Vs Sinus Elevation from Surgical and Prosthetic View

**Hassan H Koshak\***

Head of the Dental Department and Dental Educator, Director of Academic and Education Affairs at Comprehensive Specialized Polyclinic, Ministry of Interior Security Forces Medical Services, Jeddah, Kingdom of Saudi Arabia

**\*Corresponding Author:** Hassan H Koshak, Head of the Dental Department and Dental Educator, Director of Academic and Education Affairs at Comprehensive Specialized Polyclinic, Ministry of Interior Security Forces Medical Services, Jeddah, Kingdom of Saudi Arabia.

**Received:** January 04, 2019; **Published:** February 20, 2019

### Abstract

Clinical choice of the most appropriate implant therapy modality should be based on assessment of the residual alveolar bone height, width, and sinus morphology with a cone beam computed tomography (CBCT) scan, current scientific evidence, surgical skills and experience of the surgeon, and the patient's preferences. Following a good surgical protocol and excellent oral hygiene maintenance program are fundamental elements in achieving a successful and predictable outcome. The available evidence on short dental implants in early research was not significant comparing with the longer dental implants; the surface treatment is improving now than before for this reason. The use of short implants allows treatment of patients who are unable to undergo complex surgical techniques for medical, anatomic or financial reasons. By reducing the need for complex surgeries short implants reduce morbidity, cost and treatment time. Recently short implants offer a less invasive treatment alternative in resorbed ridge cases.

**Keywords:** Sinus; Surgical; Therapy

### Introduction

A natural sequela of the loss of maxillary molars is the loss of crestal bone height. Once teeth are removed, the remaining ridge can lose 30% to 60% of its height and width within the first 3 years. The maxillary sinus can pneumatize and become larger, and this too will result in a decrease in the remaining osseous ridge height [1].

Implant treatment options for rehabilitation of the posterior maxilla are dictated by the available alveolar bone height, type of bone, and interarch space [2].

Definition of short implant according to the literatures:

Depend on the Implant length variation.

- o A dental implant with length of 7 mm or less [3].
- o Any implant under 10 mm in length referred to as a short implant [4].
- o A device with an intra-bony length of 8 mm or less [5].

Depend on the Implant width variation.

- o Wide implant defined as a fixture with 4.5 mm or more in diameter, and a "narrow" implant as one in which this was less than 3.5 mm in diameter [5].

### Literature Review

#### Early research

Review of short implants in clinical studies between 1981 and 1997 a higher failure rate and implant loss with short implants than with long implants [6].

Higher failure rate with poor bone quality and short implant placement in the atrophic maxilla or following bone-grafting procedures [7].

Buser, *et al.* 1997 reported 91.4% cumulative survival rate for 8 mm long implants with a plasma-sprayed surface [8].

Friberg, *et al.* 1997 also found a high success rate for short implants, with a 95.5% five-year survival rate [9].

### Recent research

Rocchietta, *et al* 2008 did a systematic review on a short implant versus long implant or short implants versus adjunctive surgical procedures that required to place a longer implant and he found survival rates of implant placed in augmented sites over 1-7 years was 92.1% to 100% for GBR and 76% to 100% for onlay bone grafts [10].

Cumulative survival rate of implants placed in the augmented maxillary sinus was 95% (follow-up, 6-144 months) and that in the guided bone regeneration technique protocols ranged from 92% to 100% (follow-up, 6-133 months) [11].

Telleman, *et al* 2011 did a systematic review of the prognosis of short 10 mm dental implants placed in the partially edentulous patient and he found:

- Growing evidence that short implants can be placed successfully in the partially edentulous patients.
- Increasing survival rate per implant length.
- Short dental implant in the mandible has a better prognosis over maxilla.
- The results of studies excluding smokers revealed higher implant survival rates [12].

Monje, *et al* 2012 concluded in his meta-analysis on prospective clinical trials study, short dental implants had an estimated survival rate of 88.1% at 168 months while standard of dental implants has a similar estimated survival rate of 86.7%, the peak failure rate of short dental implants was found to occur between 4-6 years of function compared to 6-8 years for standard implants.

Monje, *et al* 2012 concluded that in the long-term implants less than 10mm were as predictable as longer implants [13].

Esposito, *et al* 2014 did experimental comparison study between two groups on posterior atrophic jaws rehabilitated with prostheses supported by group 1) 6mm long, 4mm wide implants, and group 2) by longer implants in augmented bone.

Esposito found on short-term data (5 months after loading) indicate that 6mm long implants with a conventional diameter of 4mm achieved similar result to longer implants placed in augmented bone.

Short implants might be a preferable choice to bone augmentation, since the treatment is faster, cheaper and associated with less morbidity [14].

Francesco, *et al* 2012 did a randomized clinical trial (RCT) study on rehabilitation of the atrophic posterior maxilla using short implants or sinus augmentation with simultaneous standard-length implant placement and followed for 3 years after loading.

Francesco concluded related to implants failures, complication, operation time, postoperative pain and swelling, soft tissue parameters, marginal bone levels, and implant stability values:

- Both treatment approaches achieved successful and similar outcomes after 3 years of function.
- Short implants take considerably lower operation time with decreased surgical complication and postoperative patient discomfort.
- More RCTs with longer follow-up times and larger sample sizes are necessary to validate the current findings.
- Implants length engaged in alveolar bone dose not appear to influence the degree of peri-implant bone resorption after a medium-time period of 3 years [15].

Gulje, *et al* 2014 did a Multicenter trial on (six study centers) 95 subjects were included, his subjects were randomly allocated to receiving implants in posterior maxilla or mandible with lengths of ether 6 to 11mm both with a diameter of 4mm (Osseo Speed TM 4.0 S, Astra).

Sufficient bone height for placement of at least 11mm in length, 2 or 3 implants were placed per subject using one-stage surgery.

They were restored with a screw-retained splinted fixed prosthesis.

Clinical and radiographic examinations were performed preoperatively, post surgery, at loading, 6 and 12 months after prosthesis placement.

A total of 208 implants were inserted in 49 subjects receiving 6 mm implants and 46 subjects receiving 11 mm implants.

Two 6 mm implants failed before loading, one 6 mm and one 11 mm implants failed before 1 year evaluation.

From loading to the 12 months follow-up, a mean marginal bone gain of 0.06 mm in the 6 mm group and 0.02 mm in the 11 mm group was found ( $p = 0.487$ ).

Soft tissue behavior was equal in both groups.

Clinical and one year data indicated that treatment with the 6mm implants is as reliable as treatment with the 11mm implants.

Future randomized controlled clinical trials required to validate predictability of the findings [16].

Thomas DS., *et al.* 2015 did a multicenter randomized controlled clinical trial on short dental implants (6mm) versus long dental implants (11–15mm) in combination with sinus floor elevation procedures for 3-year follow up. Thomas concluded that implants with a length of 6 mm as well as longer implants in combination with a lateral sinus lift may be considered as a treatment option provided a residual ridge height of 5–7 mm in the atrophied posterior maxilla is present [17].

Nedir R., *et al.* 2015 concluded in his randomized controlled prospective study, there was no significant difference on short implants placed with or without grafting in atrophic sinuses for 3-year follow up [18].

Rossi F., *et al.* 2015 did a prospective cohort study on moderately rough surface (6mm) short implants, with early loading supporting single crowns, over 5-year period, and his result was 4 failed of 30 (6mm) short implants vs 1 failed of 30(10mm) regular implants [19].

Nedir R., *et al.* 2017 concluded that atrophic posterior maxillae can be predictably rehabilitated using osteotomy sinus floor elevation with a simultaneous implant placement. The new bone formed around implants after 1 year was stable after 5 years, irrespective of the presence or the absence of graft. Grafting was unnecessary to achieve an average bone augmentation of 3.8 mm, but more bone was gained with grafting [20].

Pohl V., *et al.* 2017 concluded that implants with a length of 6 mm as well as longer implants in combination with a lateral sinus lift may be considered as a treatment option provided a residual ridge height of 5-7 mm in the atrophied posterior maxilla is present [21].

### Survival of short implants

Kotsovilis., *et al.* 2009 did a systematic review and meta-analysis on the effect of implant length on the survival of rough-surface dental implants. He concluded that survival of short implants is not different from longer implants [22].

Atieh., *et al.* 2012 did a systematic literature review on survival of short dental implants of posterior partial edentulism.

- o 5 Randomized clinical studies.
- o 16 Prospective, nonrandomized, noncontrolled studies.
- o 12 Retrospective, nonrandomized studies.
- o 1 Study with both prospective and retrospective data.

Atieh concluded there is no significant difference of short versus long implants [23].

Srinivasan., *et al* 2014 did a review of the literature and meta-analysis on the survival rates of short (6 mm) micro-rough surface implants;

A total of 690 short implants 6 mm were evaluated in the reviewed studies.

The pooled early clinical success rate (CSR) calculated in this meta-analysis was 93.7%.

Overall CSR maxilla: 94.7%.

Overall CSR mandible: 98.6%.

Atieh concluded that short dental implants provide a predictable treatment option [24].

### Contributing factors affecting success of short implant

Surgical protocol

- o Undersized implant bed preparation.
- o Lateral bone condensation

Bone density seems to represent the major determinant of primary stability in maxillary sinus augmentation with simultaneous implant placement (as well as 5–6 mm short implants in the maxillary sinus floor). Preoperative bone density assessment may help to avoid stability-related complications in one-stage implant treatment of the atrophic posterior maxilla [25].

### Implant selection

Implant with geometrical designs that increased primary stability:

- o Modified shape.
- o Self-tapping threads
- o Tapered profiles.
- o Flared necks.
- o End cutting.
- o Depth threads.

Thread geometry affects the distribution of stress forces around the implant. A decreased thread pitch may positively influence implant stability. Excess helix angles in spite of a faster insertion may jeopardize the ability of implants to sustain axial load. Deeper threads seem to have an important effect on the stabilization in poorer bone quality situations. The addition of threads or micro-threads up to the crestal module of an implant might provide a potential positive contribution on bone-to-implant contact as well as on the preservation of marginal bone; nonetheless this remains to be determined [26].

### Implant surface characteristics

Rough implants offer extensive surface for osseointegration and therefore allow the clinician to consider usage of short implants [27].

Survival rate of implants with roughened surface (96.6%) is significantly higher than the survival rate of implants with machined (88%) [11].

It is apparent that rough-surfaced dental implants have significantly higher success rate compared with implants with smoother surfaces [12].

### Crown to implant ratio

Tawil, *et al.* 2006 placed 262 Branemark implants (10mm or less in length) the patients were followed 12 to 108 months and evaluate marginal bone loss.

He concluded that when the load distribution is favorable, increased crown to implant ratios are not major risk factor:

- o Reduction of the occlusal table.
- o Flattening of the cuspal inclines [28].

### Crown to implant ratio and occlusal forces

(Nedir, *et al.* 2006) 7 years study of implant to crown ratio ranged from 1.05 to 1.80, and no detrimental consequences on the final success rate were noted [29].

(Blanes, *et al.* 2007) reported the results of 10 years prospective study with 192 implants placed in the posterior region. A total of 51 implants showed a clinical crown to implant ratio equal to or greater than 2., three implants failed, giving a cumulative survival rate of 94.1% [30].

(Blanes 2009) Systematic review the current literature shows that the crown to implant ratios of implant-supported reconstructions do not influence peri-implant crestal bone loss [31].

Anitua E., *et al.* 2015 also found crown to implant ratio had not a significant influence on MBL on first year post loading [32].

### Crown to implant ratio has no influence on marginal bone loss

Systematic review on influence of crown to implant ratio on marginal bone loss 57 Articles selected. A significant negative association between the crown to implant ratio and the marginal bone loss was found (P = 0.012). However, no statistically significant difference was found [33].

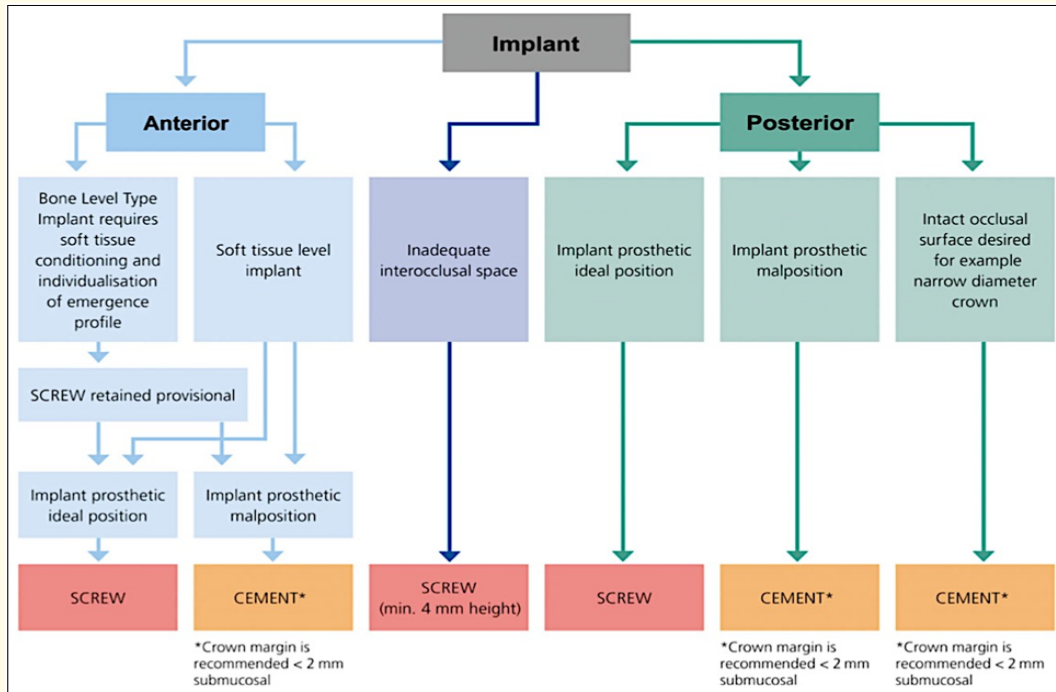
### Screw retained vs. cement retained

Screw retention may be recommended:

- o In the presence of minimal interarch space (minimum 4 mm).
- o For FDPs with a cantilever design.
- o For long-span FDPs.
- o To avoid an additional risk factor with the use of cement and a possible cement remnant.
- o In the esthetic zone, for provisionalization of implants to enable soft tissue conditioning and finalization of the emergence and mucosal profile.
- o When retrievability is desired Implants must be placed in a prosthetically ideal position with the future access hole of the planned crown below the planned incisal edge in order to facilitate screw retention [34].
- o Cement retention may be recommended:
- o For short-span prostheses with margins at or above the mucosa level.

- To compensate for improperly inclined implants
- For cases where an easier control of occlusion
- Without an access hole is desired –for example, with

narrow-diameter crowns, The cementation procedure should be carried out with great caution, with the FDP margins placed at or above the tissue level [34].



**Figure 1:** Decision tree illustrating the pathway of decisions in respect of the indication of screw vs. cementation in fixed prosthodontics supporting implants.

**Complications associated with sinus elevation**

**Complications associated with sinus elevation**

- Preoperative acute sinusitis.
- Preoperative chronic sinusitis.
- Preoperative fungal sinusitis.
- Preoperative cystic structures and mucocoeles.
- Other preoperative sinus lesions.

**Intraoperative complications**

- Hematoma during anesthesia.
- Bleeding during incision and flap reflection.
- Bleeding during osteotomy.
- Damage to adjacent dentition.
- Perforation of the sinus membrane during osteotomy.
- Perforation of the sinus membrane during elevation.
- Incomplete elevation.

- Bleeding during membrane elevation.
- Fracture of the residual alveolar ridge.
- Excessive elevation of the membrane.
- Presence of a mucus retention cyst.
- Blockage of the maxillary ostium.
- Unstable implants.

**Postoperative complications**

**Early postoperative complications**

- Postoperative pain.
- Wound dehiscence.
- Acute graft infection/sinusitis.
- Exposure of the bone graft and/or barrier membrane.
- Sinus congestion.
- Early implant migration into the sinus cavity.

Late postoperative complications

- Insufficient quality and/or quantity of healed graft.
- Implant failure in the augmented sinus.
- Chronic infection/sinusitis.
- Infection of all paranasal sinuses/intracranial cavity.
- Delayed implant migration into the sinus cavity.
- Sinus aspergillosis [35].

- Lower costs.
- Fewer complications.
- Quicker rehabilitation time.

**Discussion**

Clinical choice of the most appropriate implant therapy modality should be based on assessment of the residual alveolar bone height, width, and sinus morphology with a cone beam computed tomography (CBCT) scan, current scientific evidence, surgical skills and experience of the surgeon, and the patient’s preferences. Following a good surgical protocol and excellent oral hygiene maintenance program are fundamental elements in achieving a successful and predictable outcome.

The use of short implants allows treatment of patients who are unable to undergo complex surgical techniques for medical, anatomic or financial reasons. By reducing the need for complex surgeries short implants reduce morbidity, cost and treatment time.

The available evidence on short dental implants in early research was not significant comparing with the longer dental implants; the surface treatment is improving now than before for this reason.

Recently short implants offer a less invasive treatment alternative in resorbed ridge cases.

**Situations that limit placement of long implant**

- Height of existing available bone at maxillary sinus or mandibular canal.
- History of chronic sinusitis.
- Cystic fibrosis.
- Pathological lesions.
- Patient acceptance for adjunctive surgical procedures to place longer implant.

**Short implant as an alternative**

- Increases patient’s acceptability.
- Less surgical procedures.

Key Factors	Sinus Floor Elevation	Short Implant Placement
Medical History	Obstructed Ostium, sinusitis	
Anatomy	Septa	Residual Alveolar
Bone Quality	✓	Type 3 To 4
Bone Quantity	To Be Formed	✓
Residual B-L Width	Usually Manageable	Do We Need WP?
Simplicity	✓	✓
Mine-morbidity	✓	✓✓
C/I Ratio	✓	??
Short Term Success	✓	✓
Long Term Success	✓	??
Time and cost	✓	✓✓

**Figure 2:** Comparison between sinus floor elevation and short implant placement.

**Situations that limit placement of long implant**

In cases, where bone volume is not enough to place an implant, using a short implant may avoid complex augmentative procedures and has some advantages:

- Similar implant and reconstruction survival rate.
- Keep vital structures and vascularization.
- Maintain more bone when placing the implant.
- Less morbidity.
- Faster and cheaper.

**Bibliography**

1. Boyne PJ. “History of maxillary sinus grafting”. In: Jensen OT, ed. *The Sinus Bone Graft*. 2nd ed. Chicago, IL: Quintessence Publishing; (1999): 1-6.
2. Thoma DS., et al. “EAO Supplement Working Group 4 -EAO CC 2015 Short implants versus sinus lifting with longer implants to restore the posterior maxilla: a systematic review”. *Clinical Oral Implants Research* 26 (2015): 154-169.

3. Friberg B., et al. "Long- term follow-up of severely atrophic edentulous mandibles reconstructed with short Brånemark implants". *Clinical Implant Dentistry and Related Research* 2 (2000): 184-189.
4. Griffin TJ., et al. "The use of short, wide implants in posterior areas with reduced bone height: a retrospective investigation". *Journal of Prosthetic Dentistry* 92 (2004): 139-144.
5. Renouard F and Nisand D. "Impact of implant length and diameter on survival rates". *Clinical Oral Implants Research* 17 (2006): 35-51.
6. Goodacre CJ., et al. "Clinical complications of osseointegrated implants". *Journal of Prosthetic Dentistry* 81 (1999): 537-52.
7. Sennerby L and Meredith N. "Resonance frequency analysis: measuring implant stability and osseointegration". *Compendium* 19 (1998): 493-502.
8. Buser D., et al. "Long-term evaluation of non- submerged ITI implants. Part 1: 8-year life table analysis of a prospective multi-center study with 2359 implants". *Clinical Oral Implants Research* 8 (1997): 161-172.
9. Friberg B., et al. "MKII: the self-tapping Brånemark implant: 5-year results of a prospective 3-center study". *Clinical Oral Implants Research* 8 (1997): 279-285.
10. Rocchietta I., et al. "Clinical outcomes of vertical bone augmentation to enable dental implant placement: a systematic review". *Journal of Clinical Periodontology* 35 (2008): 203-215.
11. Chiapasco M., et al. "Bone augmentation procedures in implant dentistry". *The International Journal of Oral and Maxillofacial Implants* 24 (2009): 237-259.
12. Telleman G., et al. "A systematic review of the prognosis of short (< 10 mm) dental implants placed in the partially edentulous patient". *Journal of Clinical Periodontology* 38 (2011): 667-676.
13. Monje A., et al. "Are short dental implants (<10 mm) effective? a meta-analysis on prospective clinical trials". *Journal of Periodontology* 84 (2013): 895-904.
14. Esposito M., et al. "Three-year results from a randomised controlled trial comparing prostheses supported by 5-mm long implants or by longer implants in augmented bone in posterior atrophic edentulous jaws". *European Journal of Oral Implantology* 7 (2014): 383-395.
15. Francesco Pieri., et al. "Rehabilitation of the atrophic posterior maxilla using short implants or sinus augmentation with simultaneous standard-length implant placement: A 3-year randomized clinical trial". *Clinical Implant Dentistry and Related Research* (2012).
16. Guljé F., et al. "Implants of 6 mm vs. 11 mm lengths in the posterior maxilla and mandible: a 1-year multicenter randomized controlled trial". *Clinical Oral Implants Research* 24 (2013): 1325-1331.
17. Thoma., et al. "Randomized controlled multicentre study comparing short dental implants (6 mm) versus longer dental implants (11-15 mm) in combination with sinus floor elevation procedures. Part 1: demographics and patient-reported outcomes at 1 year of loading". *Journal of Clinical Periodontology* 42 (2015): 72-80.
18. Nedir Rabah., et al. "Short Implants Placed with or without Grafting in Atrophic Sinuses: The 3-Year Results of a Prospective Randomized Controlled Study". *Clinical Implant Dentistry and Related Research* (2015).
19. Rossi Fabio., et al. "Lang, Emanuele Ricci, Lorenzo Ferraioli, Claudio Marchetti, Daniele Botticelli. Early loading of 6-mm-short implants with a moderately rough surface supporting single crowns - a prospective 5-year cohort study". *Clinical Oral Implants Research* 26 (2014): 359-483.
20. Nedir Rabah., et al. "Short implants placed with or without grafting into atrophic sinuses: the 5-year results of a prospective randomized controlled study". *Clinical Oral Implants Research* 28 (2017): 877-886.
21. Pohl V., et al. "Short dental implants (6 mm) versus long dental implants (11-15 mm) in combination with sinus floor elevation procedures: 3-year results from a multicentre, randomized, controlled clinical trial". *Journal of Clinical Periodontology* 44 (2017): 438-445.
22. Kotsovilis S., et al. "A systematic review and meta-analysis on the effect of implant length on the survival of rough-surface dental implants". *Journal of Periodontology* 80 (2009): 1700-1718.
23. Atieh MA., et al. "Survival of short dental implants for treatment of posterior partial edentulism: a systematic review". *The International Journal of Oral and Maxillofacial Implants* 27 (2012): 1323-1331.
24. Srinivasan M., et al. "Survival rates of short (6 mm) micro-rough surface implants: a review of literature and meta-analysis". *Clinical Oral Implants Research* 25 (2014): 539-545.

25. Marquezan Mariana, *et al.* "Does bone mineral density influence the primary stability of dental implants? A systematic review". *Clinical Oral Implants Research* 25 (2014): e109-e113.
26. Abuhussein H., *et al.* "The effect of thread pattern upon implant osseointegration". *Clinical Oral Implants Research* 21 (2010): 129-136.
27. Jain Neha, *et al.* "Short Implants: New Horizon in Implant Dentistry". *JCDR - Journal of Clinical and Diagnostic Research* 10 (2016): ZE14-ZE17.
28. Tawil G., *et al.* "Influence of prosthetic parameters on the survival and complication rates of short implants". *International Journal of Oral and Maxillofacial Implants* 21 (2006): 275-282.
29. Nedir R., *et al.* "A 7-year life table analysis from a prospective study on ITI implants with special emphasis on the use of short implants. Results from a private practice". *Clinical Oral Implants Research* 15 (2006): 150-157.
30. Blanes Juan, *et al.* "A 10-year prospective study of ITI dental implants placed in the posterior region. I: Clinical and radiographic results". *Clinical Oral Implants Research* 18 (2008): 699-706.
31. Blanes RJ. "To what extent does the crown-implant ratio affect the survival and complications of implant-supported reconstructions? A systematic review". *Clinical Implant Dentistry and Related Research* 20 (2009): 67-72.
32. Anitua E., *et al.* "Retrospective study of short and extra short implants placed in posterior regions: Influence of crown to implant ratio on marginal bone loss". *Clinical Implant Dentistry and Related Research* 17 (2015): 102-110.
33. Garaicoa Pazmiño C., *et al.* "Influence of Crown to Implant Ratio Upon Marginal Bone Loss. A Systematic Review". *Journal of Periodontology* 85 (2014): 1214-1221.
34. Wittneben Julia, *et al.* "Screw retained vs. cement retained implant-supported fixed dental prosthesis". *Periodontology* 73 (2000): 141-151.
35. Louie Al-Faraje, *et al.* "Surgical complications in oral implantology Etiology, Prevention, and Management". Hanover Park, IL : Quintessence Pub., (2011).

**Volume 3 Issue 3 March 2019**

**© All rights are reserved by Hassan H Koshak.**